IX. *The Segmentation and Chondrification of the Skull of the Duck.*

By G. R. DE BEER, *M.A.*, *D.Sc.*, *Fellow of Merton College, Jenkinson Lecturer in Embryology, and Senior Demonstrator in Zoology and Comparative Anatomy in the University of Oxford; and* E. J. W. BARRINGTON, *B.A.*, *B.Sc.*, *Lecturer in Zoology, University College, Nottingham.*

(Communicated by E. S. GOODRICH, F.R.S.—Received September 27, 1933—Read January 25, 1934.)

[PLATES 46–52.]

CONTENTS.

[Published May 18, 1934.

I. INTRODUCTION.

Among the problems presented by the bird's skull and which we have attempted to solve, are the following :—

1. Why the cartilaginous plate in the orbito-temporal region (GAUPP, 1906, termed it the planum sphenolaterale) separates the first or profundus branch of the trigeminal nerve from the second or maxillary branch ; this would be the position of a processus ascendens which the bird does not possess, while a pila antotica, which is supposed to be present in the bird, should be situated in front of the profundus branch ;
2. Why the glossopharyngeal and vagus nerve-roots are separated by a cartilage which encloses the tympanic region, and what is the nature of this cartilage ;
3. How the olfactory nerve makes its way into the nasal capsule, whether it traverses a part of the orbit, and what happens to the orbital cartilage in this region ;
4. Why the internal carotid arteries pass through peculiar foramina in the cartilage on each side of the skull before penetrating into the cranial cavity through the hypophysial fenestra ;
5. How the turbinals of the nasal capsule can be compared and brought into line with those of other forms.

In addition to these problems of morphology and chondrogenesis, the marked evidence of metameric segmentation which the hinder part of the bird's skull presents, has led us to consider the whole question of the segmentation of the head in the bird. To judge from the literature, it would seem that in spite of the objections raised against them by GOODRICH (1918, 1930), current opinion has not entirely succeeded in freeing itself from the erroneous views which FÜRBRINGER (1897) put forward.

The first part of this paper, then, is devoted to a study of the segmentation of the head of the duck, and is the work of E. J. W. B. The second part is concerned with the development of the chondrocranium and the morphological problems connected with it ; for this part G. R. DE B. is responsible.

The material for these investigations consisted of duck embryos incubated expressly for this work, and either cut into serial sections, or prepared for the study of cartilage *in toto* with victoria blue by the VAN WIJHE method (1902, 1922). In addition, model reconstructions were made by the blotting-paper-wax method from serial sections of a 7-day duck embryo, and of a sparrow embryo nearing full time. Lastly, for purposes of comparison, recourse was had to the sections of embryos of other groups of vertebrates in the embryological collection of the Department of Zoology of the University of Oxford, and to the series of VAN WIJHE preparations and model reconstructions made by one of us (G. R. DE B.).

The figures illustrating the development of the skull on the plates accompanying this paper were drawn under the *camera lucida* directly from the VAN WIJHE preparations, and it is therefore hoped that they are as accurate as possible.

The work was done in the Department of Zoology and Comparative Anatomy of the Oxford University Museum, and one of the first duties of the authors is to express their appreciation of the assistance and encouragement which Professor GOODRICH has always been ready to give them. That portion of the work dealing with the segmentation of the head was completed with the aid of a research grant from the Christopher Welch Trustees, to whom grateful acknowledgment is rendered.

II. METHODS AND MATERIAL.

For serial sections, embryos were fixed in corrosive-acetic, stained in bulk in borax carmine, and counterstained on the slide with picro-indigo-carmine or by the Azan technique of HEIDENHAIN; of several methods tried, the latter gave by far the best results for skeletal structures.

Several embryos were reconstructed from sections by graphic methods. For the model reconstructions, the method first devised by the Oxford Department of Human Anatomy was used; viz., the sections were drawn under the *camera lucida* on thin paper which was then backed by blotting paper soaked in molten beeswax, so as to attain a thickness commensurate with the original thickness of the sections and the linear magnification of the microscope and *camera lucida*. The plates so obtained were then cut out by means of a sharp knife or a fretsaw, built up on one another, and fastened simply with pins. Models constructed in this manner have the great advantage over the ordinary wax-plate models that they do not melt or become deformed in hot weather, are not brittle, and are practically unbreakable.

For the making of whole preparations showing nothing but the cartilage, the victoria blue VAN WIJHE (1902, 1922) method was used.

For purposes of study, the most convenient method of mounting the VAN WIJHE preparations was found to be the construction of glass cells out of ordinary microscope slides, cut to fit the embryo closely. The sides and ends of the cells are stuck down on to a slide by means of an alcoholic solution of shellac. When this has set, the cell is filled with Canada balsam dissolved in xylol, the embryo is placed in it, and covered with a coverslip, which must allow a certain area of balsam at each end to remain uncovered for the purpose of filling up after evaporation. Preparations mounted in this manner can be studied with moderately high powers of the microscope from above, beneath, both sides, and both ends; and the use of alcoholic shellac for the construction of the cells avoids the danger of the collapse of the cell and leakage of the contained balsam. It should be added that for small embryos, no dissection is necessary, but for larger ones it is advisable to remove the skin, various muscles, and the eyes, brain and spinal cord, in order to obtain a clear and uninterrupted view of the cartilage. This is best done by means of Swiss watch-maker's forceps under the binocular microscope when the embryos are in xylol, prior to mounting.

III. TABLE OF STAGES.

The following stages were studied for the elucidation of the segmentation :—

7-somite, fig. 1.
10-somite, fig. 26, Plate 46,
14-somite, fig. 2.
18-somite, fig. 3.
23-somite, fig. 4 ; fig. 27, Plate 46.
28-somite, fig. 5.
39-somite (78 hours), fig. 6 ; fig. 28, Plate 46.
47-somite (96 hours), fig. 7.
108-hours, fig. 8.
132-hours, figs. 29, 30, Plate 46.
160-hours, fig. 9.
7-days, figs. 31, 32, Plate 46,

For the chondrogenesis of the skull the following stages were used :—

Stage 1.—132 hours, fig. 33, Plate 47.
„ 2.—138 hours, figs. 34, 35, Plate 47.
„ 3.—144 hours, figs. 36, 37, Plate 47.
„ 4.—156 hours, figs. 38, 39, Plate 47.
„ 5.—160 hours, figs, 40, 41, Plate 47.
„ 6.—7 days, fig. 11 ; figs. 42, 43, Plate 47.
„ 8.—7½ days, figs. 44, 45, Plate 48.
„ 7.—8 days, figs. 10, 12 ; figs. 46, 47, 48, Plate 48 ; figs. 71, 72, 73, 74. 75, Plate 52.
„ 9.—8½ days, figs. 50, 51, Plate 48.
„ 10.—9 days, fig. 49, Plate 48 ; figs. 52, 53, Plate 49.
„ 11.—9½ days, figs. 54, 55, Plate 49.
„ 12.—11 days, fig. 13 ; fig. 56, Plate 49.
„ 13.—14 days, fig. 14 ; figs. 57–66, Plates 50 and 51.
„ 14.—17 days, fig. 15 ; figs. 67–70, Plate 51.

IV. THE SEGMENTATION OF THE HEAD OF THE DUCK.

The position of the auditory sac in the vertebrate embryo is a convenient landmark for distinguishing the prootic segments, of which the number is usually taken to be three, from a varying number of metotic segments included between the hindmost prootic segment and the occipital arch of the skull. It must be clearly understood that the metotic series of segments and somites is directly consecutive upon the prootic series, and it is merely for the sake of convenience that the prootic and metotic regions are considered separately.

A.—*The Prootic Region.*

(i) *Descriptive.*—The development of the three prootic somites of the Selachian embryo into the extrinsic eye-muscles and the relations between these and the cranial nerves, first demonstrated by **Balfour** (1876), have been shown by subsequent workers to be true in general terms for all groups of Craniates. The development of the eye-muscles in birds has been studied by **Rex** (1897, 1901), **Edgeworth** (1907), and **Adelmann** (1922, 1926, 1927), so that the facts need only brief description, the observations now recorded being corroborative of theirs. It is, however, necessary to go into this matter here, for the main object of this particular investigation is to determine the serial number of the segment in which the occipital arch of the skull arises in the duck, and for this purpose it is essential to establish the fact that the prootic somites are true somites, corresponding serially with those in the more posterior regions, and that the prootic somites are three in number.

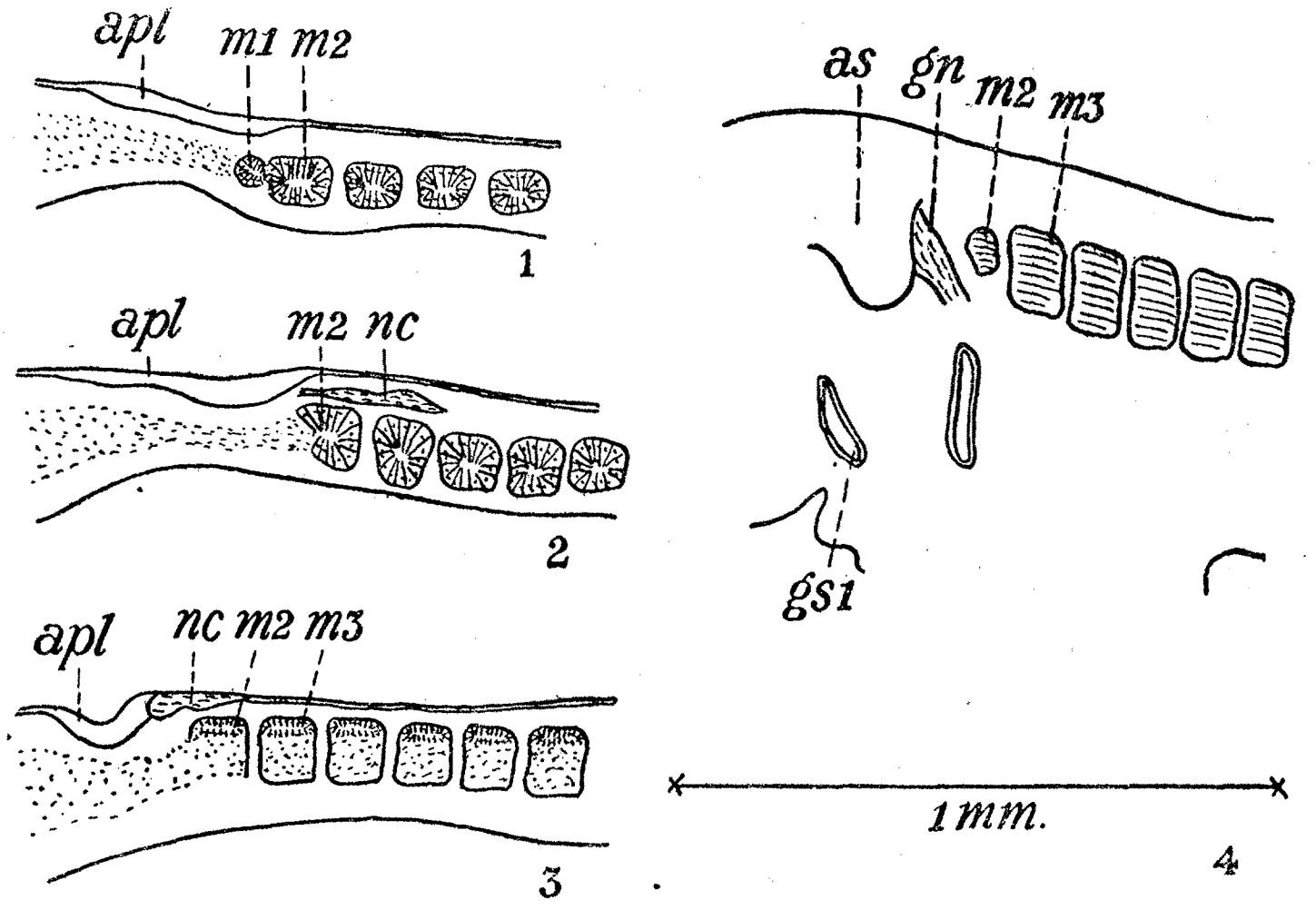

(Except where otherwise stated, all figures are of the duck.)

Fig. 1.—Reconstruction of metotic region of 7-somite stage, anterior end to the left. Fig. 2.—Reconstruction of metotic region of 14-somite stage. Fig. 3.—Reconstruction of metotic region of 18-somite stage. Fig. 4.—Reconstruction of metotic region of 23-somite stage.

From an early stage, the endoderm anterior to the notochord ("prechordal plate") is a site of mesoderm formation which results in the proliferation of the "prechordal mesoderm" (**Adelmann**) or "interepithelial cell-mass" (**Rex**), this being continuous from side to side across the middle line. The lateral regions of this mass become condensed, and, in each condensation, cavities become recognizable at about the 21-somite stage; these are the first indications of the anterior head-cavities or premandibular somites (*i.e.*, first prootic somites). They increase rapidly in size and at the 23-somite stage, there can be recognized on each side a single main cavity which passes medio-ventrally into a few much smaller cavities which are connected across the middle line by solid mesoderm, the future hollow transverse canal. By the 28-somite stage, fig. 5, a single large cavity (*hc*) is distinguishable behind the eye on each side, and a hollow transverse commissure is established. At this stage, there can be recognized an attenuated thread of cells connecting the head-cavity with the hypophysis; this never seems to display a hollow lumen, but has every appearance of representing a vestigial canal, and is to be regarded as a "proboscis-pore" (GOODRICH, 1917), homologous with the proboscis-pore of Balanoglossus and the water-pore of Echinoderm. Open "proboscis-pores," connecting the premandibular somites and hypophysis have been described in Torpedo (CHIARUGI, 1898; DOHRN, 1904; GOODRICH, 1917; DE BEER, 1926, *a*).

At the 39-somites (78-hours) stage, fig. 6, the anterior head-cavities are still larger, and the oculomotor nerves (*o.n.*) have grown down towards them; the nerve thus appears before the muscle which it ultimately innervates. The hollow transverse canal has now broken down into mesenchyme from which the acrochordal cartilage subsequently arises (JAGER, 1924).

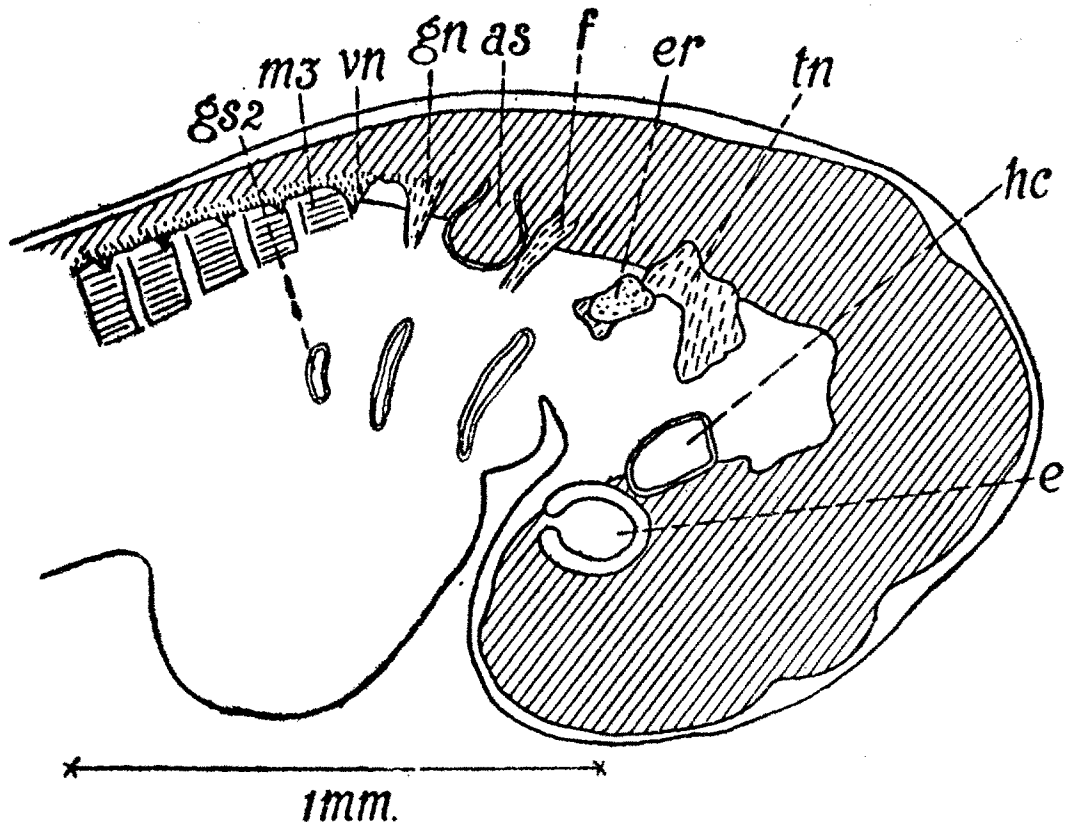

FIG. 5.—Reconstruction of head of 28-somite stage, anterior end to the right.

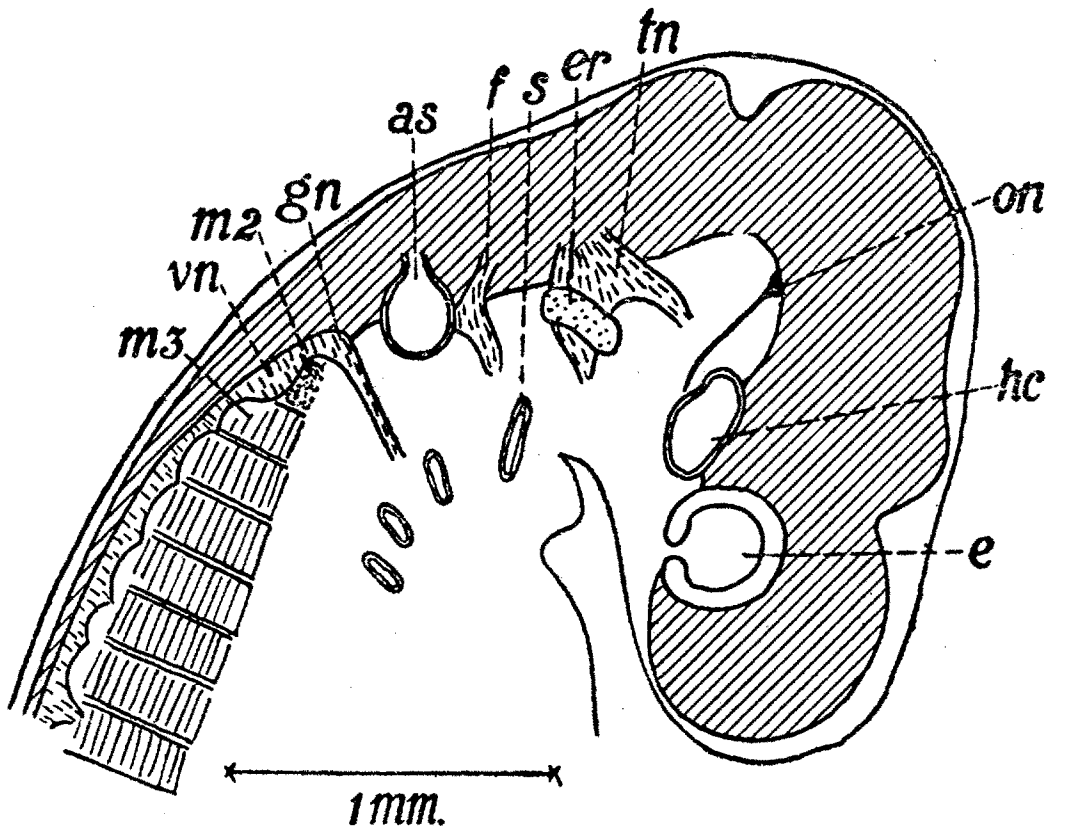

FIG. 6.—Reconstruction of head of 78-hour stage.

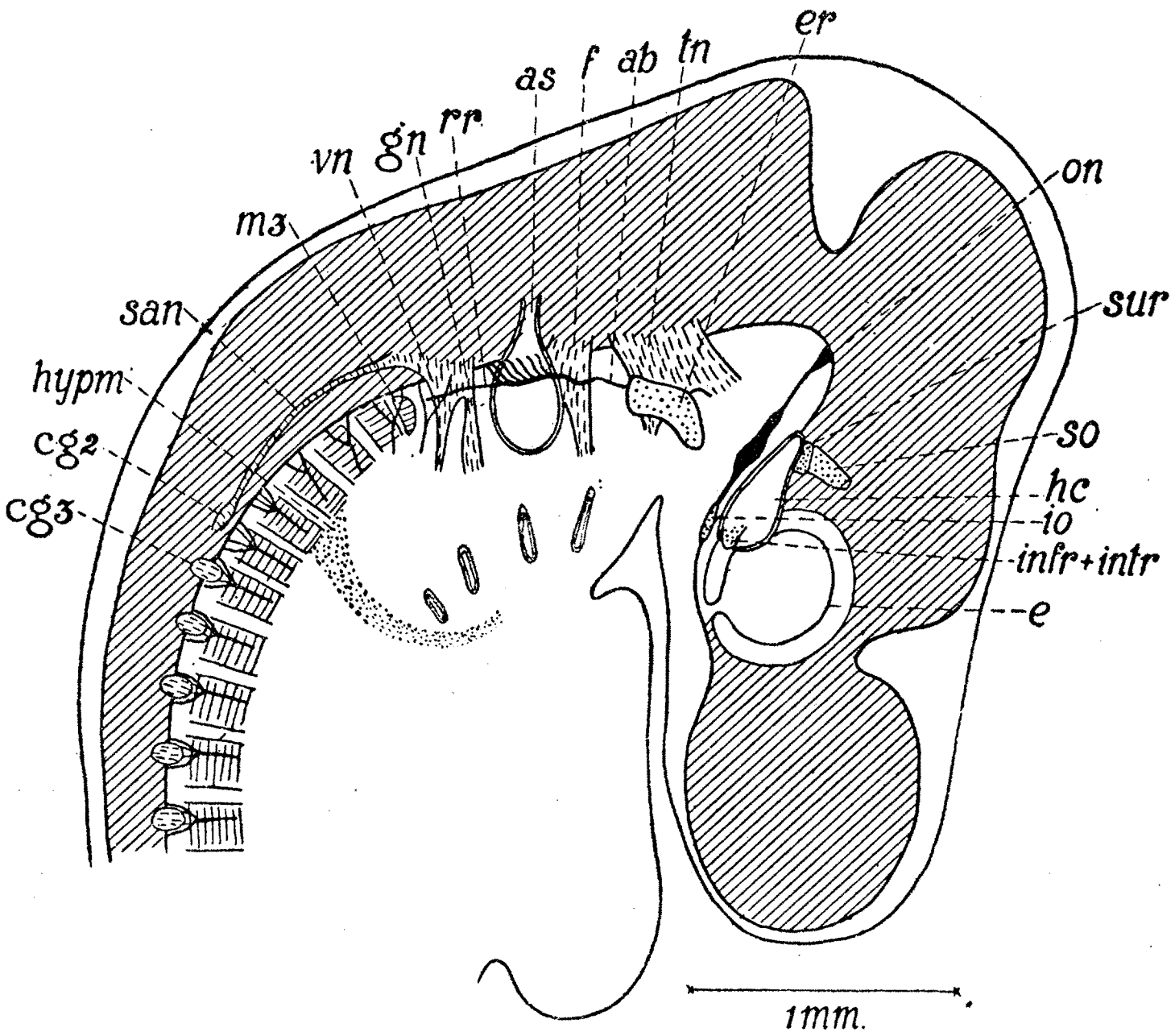

FIG. 7.—Reconstruction of head of 96-hour stage.

The rudiments of the oculomotor group of muscles appear some time before the disappearance of the head-cavities, an important point of difference between the duck and the chick. These muscles can be readily distinguished at the 47-somite (96-hours) stage, fig. 7; according to Rex they are first distinguishable at the 43-somite stage. In an embryo of 108 hours, fig. 8, the walls of the head-cavities have mostly broken down into mesenchyme, except for a small portion of the dorsal region; the oculomotor nerve can now be seen to innervate the inferior oblique rudiment (*i.o.*). At 124 hours the cavity is no longer visible; the internal rectus and inferior rectus rudiments (*intr.* and *infr.*) are becoming separate. At 160 hours all four muscles of the oculomotor group are readily identifiable, and all are innervated, fig. 9.

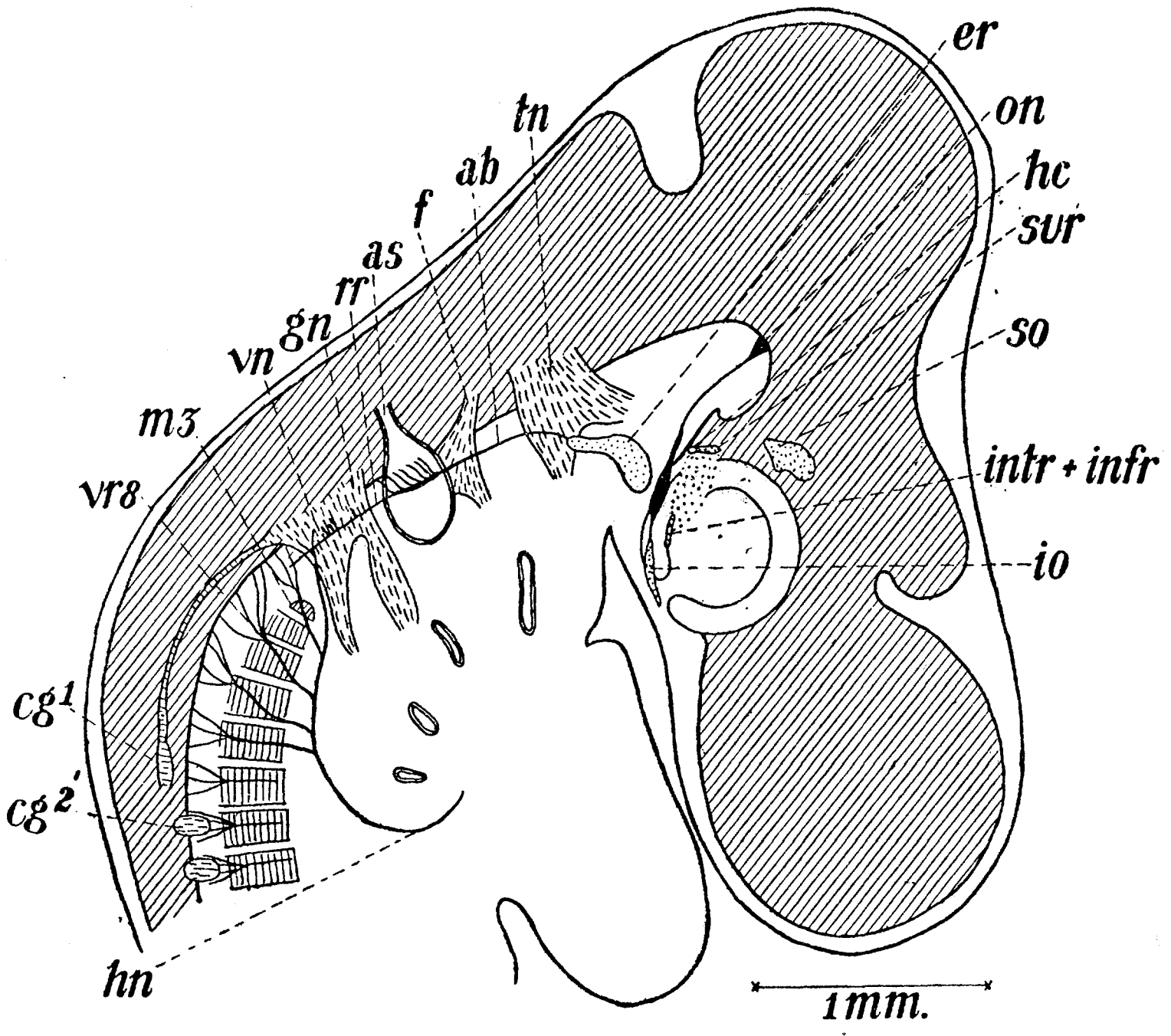

Fig. 8.—Reconstruction of head of 108-hour stage.

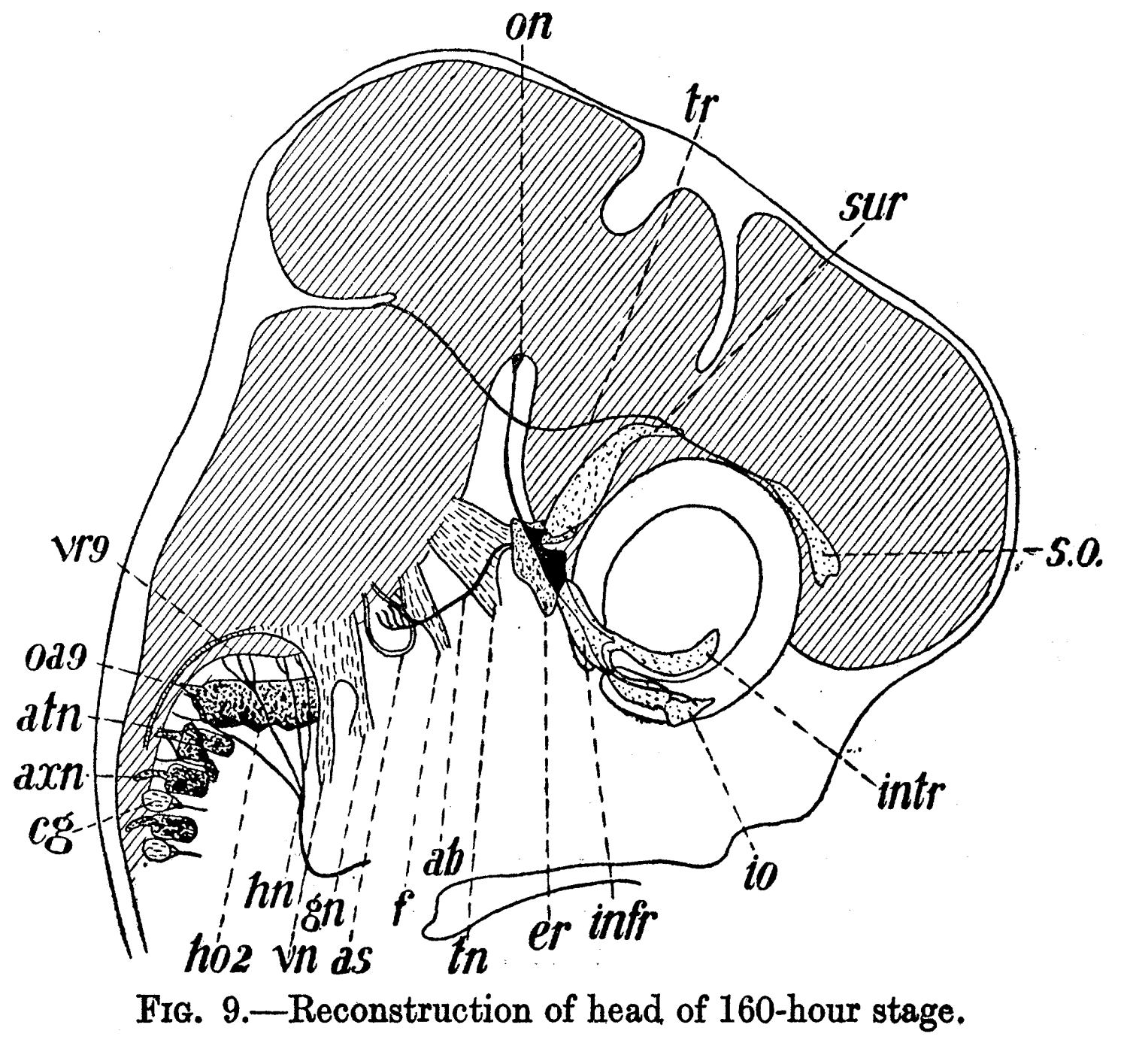

Fig. 9.—Reconstruction of head of 160-hour stage.

Although the superior oblique and external rectus muscles arise in lower vertebrates from the 2nd and 3rd prootic somites respectively, it will be convenient to treat of the latter first, since in birds it arises some considerable time before the former. The external rectus rudiment, then, arises as a condensation on the median and ventral side of the trigeminal ganglion. It is clearly defined at the 28-somite stage, fig. 5 (*er.*), and can with difficulty be traced back to the 21-somite stage, where it can be recognized by the orderly arrangement of the cells of that region, as compared with the surrounding mesenchyme. At the 28-somite and neighbouring stages it is possible in some sections to distinguish minute cavities bordered by a layer of cells showing a definite radial arrangement. It is tempting to regard these as traces of the cavity of the 3rd prootic somite, though it cannot be said to be certain.

The growth of the external rectus rudiment forwards and laterally towards its definitive position is indicated in the graphic reconstructions. At the 47-somite stage, fig. 7, the abducens nerve (*ab.*) is well developed, as is also its ramus recurrens (*r.r.*); the latter is a transient structure which runs backwards to the level of the ventral nerve-roots of the metotic segments, a number of rootlets contributing to it on its course, fig. 30, Plate 46. It probably anastomoses with the metotic roots, but owing to the slender nature of the fibres this point is difficult to determine with certainty without special neurological methods. The main centre of origin of the abducens is below the acustico-facial ganglion, where an average number of seven rootlets is to be found. At 124-hours, the ramus recurrens is no longer discernible.*

Some little time after the appearance of the external rectus rudiment, the mesenchyme of the maxillary region condenses to form a wedge-shaped mass termed the "maxillo-mandibular condensation." With this, the external rectus rudiment becomes secondarily united, forming its caudal portion, while later, the superior oblique rudiment arises as a condensation in its cranial region (ADELMANN, 1927). At 96-hours, the superior oblique (*s.o.*) is well established, dorsal to the eye, fig. 7, and gradually grows forwards and laterally, fig. 8. It may be noted in passing that various authors have compared the "intermediate mass" of this maxillo-mandibular complex with the muscle E of Miss PLATT, which it resembles in its general relations. This comparison is plausible enough, but is hardly susceptible of proof since it is impossible to detect any trace of independent muscle at this stage.

(ii) *Discussion.*—Even recently, certain authors have found difficulty in subscribing to a uniform segmental theory of the head. Noteworthy among these are REX, who in a long series of valuable studies has consistently maintained that the eye-muscle rudiments are of visceral origin, and EDGEWORTH (1907, 1928), who is not inclined to

---

* From his researches on Selachians, VAN WIJHE (1882, 1922) has been led to believe that 2 somites are related to the hyoid arch. Were this true it would necessitate the increasing by 1 of the ordinal numbers of all the metotic somites. No evidence for this could, however, be found by GOODRICH (1918) or DE BEER (1922), both working on Selachians; and since there is nothing in the duck to suggest that this is the case there, the matter may be allowed to rest.

accept the validity of VAN WIJHE'S (1882) distinction between vertebral and lateral plate mesoderm in the head. REX (1924) makes much of CORNING'S (1900) assertion that in reptiles, the superior oblique rudiment arises from the mandibular musculature, but according to JOHNSON (1913), this muscle arises in Chelydra " in the dorsal mesoderm at the side of the neural tube, just below and slightly anterior to where the trigeminal ganglion later appears." It seems probable that CORNING mistook the mandibular condensation for the superior oblique condensation. JOHNSON also describes how the cells of this condensation early " become arranged in a radial manner about a central point of lumen, and assume the form of a small somite." It is difficult to see how this can be reconciled with REX'S suggestion that the expanded multipartite cavity of later stages is related ventrally " to the dorsal arm of the tubular splanchnocoel of the mandibular arch " (1924), while the dorsal part " encloses a small portion of the terminal cavity."

A favourite suggestion of those who accept the origin of the eye-muscles from dorsal mesoderm is that they are not strictly homologous with somites, but rather represent the results of expansion in the prootic region. " Professor Kingsbury has suggested that the expansion of the mesoderm occurring coincident with the expansion of the head may conceivably take two forms—either epithelial or mesenchymal. If the expansion is epithelial in nature, head-cavities are the result." (ADELMANN, 1926.) ADELMANN'S analysis of the growth processes in the prootic region clearly shows that expansion plays a crucial part in determining the development of the eye-muscle rudiments and especially of the anterior head-cavity. It is perfectly true that the facts of eye-muscle development in birds do not immediately suggest the somitic nature of the rudiments, but it is equally true that in comparative studies the only sound method of interpretation is to proceed from the lower and simpler forms to the higher and more complex. Now, it is well known that in the lower vertebrates the eye-muscle rudiments approach much more closely to the conditions of somites; in Cyclostomes, in fact, the metotic somites form a continuous series with the three prootic somites (KOLTZOFF, 1901; and see also BRACHET, 1921, p. 362). It would therefore seem that the burden of proof must rest on those who would deny the somitic nature of the eye-muscle rudiments in the higher forms—a burden which appears never to have been adequately sustained.

The essential difference between the conditions in Selachians, for example, and birds is that development is abbreviated in the latter, the eye-muscle rudiments first arising in a form to which, in Selachians, they have to develop in each ontogeny. Thus in Scyllium the third prootic somite arises between the trigeminal and facialis ganglia (GOODRICH, 1918), whereas in the duck it arises ventrally to the trigeminal ganglion, *i.e.*, nearer to its definitive position. This phenomenon of acceleration is, of course, familiar enough in development, but it is none the less interesting to find WILLIAMS (1910) writing of the trunk somites that " the later somites do not recapitulate the development of the earlier somites; on the contrary, they merely omit the initial phases of the development of the earlier somites." Thus it is clear that the prootic somites of the bird, in failing to pass through the typical early stages of normal somites, are merely carrying to an extreme a phenomenon already manifested in the posterior trunk region.

Moreover, in addition to the facts that the extrinsic eye-muscles are striated, voluntary, and innervated by ventral nerve-roots, like the myotomes of the trunk, there are certain facts which speak directly for the somitic nature of these eye-muscle rudiments. The ramus recurrens of the abducens nerve, with its series of small roots which appear to unite the abducens and the metotic roots into a continuous series, has been described above (*cf.*, p. 418). This structure, described by Miss PLATT and others in Selachians (PLATT, 1891), and especially by BELOGOLOWY (1908) in the chick, is of the greatest importance in relating the abducens to the ventral root series and its muscle to the myotomes innervated by those ventral roots. This point has been rightly stressed by NEAL (1918), who, however, also appears to favour the view that the condition suggests the relationship of the abducens to more than one segment. Now it has been shown by COGHILL (1929) that the outgrowth of the ventral roots is conditioned by the existence of regions possessing a high rate of physiological activity at the centre of the somites, towards which the nerves grow, and it would therefore seem rather more probable that the development of the ramus recurrens is conditioned by the presence of the transient second metotic somite, and that its anterior and posterior anastomoses are a secondary result of the disappearance of that somite with the consequent absence of an end-organ to control the further outgrowth of the nerve. The first metotic somite, no doubt, disappears too early to have an effect of this nature, although JAGER (1924) believes that he has observed in a four-day chick embryo a few muscle-fibres derived from this first somite, a condition which he admits is exceptional.

The other fact which requires emphasis here is the existence (mentioned above) of a cell-strand connecting the anterior head cavity of the duck with the lateral lobes of the hypophysis (GOODRICH, 1917). There is excellent justification for regarding this connexion as a "proboscis-pore," which means that the anterior head-cavity can be traced back through the head-cavities of Amphioxus and the proboscis coelom of Balanoglossus probably to the anterior coelom of Echinoderms; the importance of this point as evidence for the somitic nature and against the "expansion" interpretation of the head-cavity is obvious.

The peculiar origin of the first pair of somites and their transverse commissure from the prechordal mesoderm in a manner differing from that of all succeeding somites has often played an important part in the criticisms of those who are unable to accept the somitic interpretation.

It must again be emphasized that all such arguments suffer from the inherent weakness of laying too much stress upon the conditions in higher forms; a reversal of this procedure, on the other hand, allowing due weight to be attached to the forms with a less modified development, leaves little doubt of the fundamental integrity of the segmental theory. As to the special peculiarities of the first prootic somite, these may receive a formal explanation from the fact of their position in front of the anterior limit of the notochord, which allows of the formation of a median commissure.

(iii) *Conclusion.*—We may therefore safely conclude that the prootic somites are true somites, and that they are three in number.

B.—*The Metotic Region.*

(i) *Descriptive.*—In the earliest stages the auditory placode provides a convenient landmark for the identification of the metotic somites; subsequently recourse can be had to the glossopharyngeal and vagus nerves which, as will be seen, preserve a constant relationship with the somites.

The first metotic somite is a reduced and transient structure, but is clearly visible between the 7-somite and 10-somite stages, appearing to attain its maximum development at about the latter stage. In a 10-somite embryo it is situated beneath the auditory placode along the lateral edge of the line of somites and has a very limited extent, the second metotic somite extending medially to it for a number of sections. The first metotic somite consists of a layer of elongated cells arranged radially round a very small central cavity; it is not completely separated either from the anterior unsegmented mesoderm or from the second metotic somite, but is quite clearly distinguishable from both. In an embryo of seven somites its relations are similar but it is somewhat less well developed, having no central cavity and extending through only two sagittal sections of 10μ, fig. 1; fig. 26, Plate 46, *m.* 1.

The transient nature of this somite is indicated by a reconstruction of a 14-somite embryo, fig. 2, which shows that at this stage it has disappeared, for the foremost visible somite is now situated immediately behind the auditory placode (*a.pl.*) and evidently corresponds to the second metotic somite (*m.* 2) of the 10-somite stage. Immediately in front of it, beneath the auditory placode, there can be distinguished in a single section a definite radial arrangement of the mesoderm, situated at the level of the lateral edge of the somites; this is probably to be interpreted as the last trace of the first metotic somite. Confirmation of this fate of the first somite is provided by evidence of a different nature, consideration of which can be more conveniently deferred until later.

The foremost metotic somite of the 18-somite stage, fig. 3, is situated a little distance behind the auditory placode instead of immediately behind it as in the preceding stages, but this need not invalidate its identification as the second metotic somite (fifth of the whole prootic-metotic series); it may be that there has been a slight relative backward migration of the somites, but it is more probable that the topographical change is due to an apparent relative movement resulting from the reduction in longitudinal extent of the auditory placode which accompanies its invagination.

The reconstructions show that this reduction between the 14-somite and 18-somite stages is a matter of some 50%. The second metotic somite, then, possesses at this stage a complete dermatome and myomere and is quite comparable with the succeeding somites; it is, however, continuous anteriorly with the so-called "unsegmented mesoderm." The neural crest (*n.c.*) is now well established behind the auditory capsule, and the glossopharyngeal nerve is represented by a condensation at the anterior end of this portion of the crest. In succeeding stages the second metotic somite undergoes involution, figs. 27, 28, Plate 46.

In a 23-somite embryo, fig. 4, the glossopharyngeal nerve (*g.n.*) is established, and this and the vagus nerve will, from now on, serve as valuable landmarks, for they will be seen to preserve constant relationships with the myotomes. The second metotic somite is situated behind the glossopharyngeal; its posterior half is well defined with muscle fibres, but comparison with the succeeding somites suggests that its anterior half is breaking down. An essentially similar condition is shown in a 24-somite embryo.

In a 27-somite embryo the second somite has almost disappeared, the posterior portion being visible in only three sections. Particularly interesting is the appearance in one section of a crescentic group of epithelial cells surrounding a small bunch of muscle fibres which fuse with the fibres of the third metotic somite. This is the only positive evidence obtained as to the direct contribution of muscle fibres to the third somite by the second. Another embryo of approximately the same age shows a well-marked mesenchymal condensation lying behind and partly below the glossopharyngeal; this represents the same somite.

At 78 hours, fig. 6, the glossopharyngeal nerve is well developed and the vagus (*v.n.*), is now beginning to grow down. Immediately behind the latter is a myomere (*m.* 3) derived from the third metotic somite, which from now on can be seen to preserve a constant relationship with the vagus, being always situated immediately behind it. In front of it is a well-defined region of somewhat more densely stained mesoderm; this condensation is the last appearance of the second metotic somite.

A reconstruction of an embryo of 96 hours, fig. 7, shows the third metotic somite (first permanent myomere) in the position already described. The third to the sixth metotic somites will eventually be incorporated in the head, as will appear below, and it is the seventh metotic somite (the tenth of the whole series) which represents the first trunk somite. The third cervical dorsal ganglion is now established (*c.g.* 3); the first and second are vestigial, but can be recognized (especially the second, *c.g.* 2) as swellings on the "accessory nerve," which is a derivative of that portion of the neural crest that remains between the vagus and the third cervical ganglion. It is to be noted that at this stage each of the four occipital myotomes (third to sixth metotic segments inclusive) has a ventral root. At 108 hours conditions are essentially similar, but at 124 hours the most anterior of the four occipital nerve-roots has vanished. At 160 hours there are only three ventral roots left, but these seem to persist for a considerable time, the three foramina associated with them being still visible in the chondrocranium of an eleven-day duck embryo. The occipital foramina appear, however, to remain for some time after the disappearance of their nerves ; thus, it is easy to recognize four foramina in whole preparations of eight- and nine-day embryos (in some, indeed, five foramina are present), although sections indicate that not more than three pairs of nerve roots can be present.

Anticipating certain results of the second part of this paper, attention must now be transferred to the skeletal elements of the occipital region. It is well known that the sclerotomes become resolved into cranial and caudal sclerotomites (PIIPER, 1928) and that in the formation of a vertebra the caudal (or hypocentral) element of a segment fuses with the cranial (or pleurocentral) element of the next posterior segment. In an embryo of 132 hours, fig. 29, Plate 46, the first two trunk sclerotomes (*c.sc.* 1, 2) can be seen lying in front of the third cervical ganglion (*c.g.* 3), but in front of them two more sclerotomes can be recognized ; these constitute the first and second occipital sclerotomes (*o.s.* 1, 2), for they eventually become incorporated in the chondrocranium, as will be shown (*see* p. 428). The cranial and caudal elements of the second occipital sclerotome can be clearly identified, as also can the hypocentrum or, *hypochordale Spange,* and the intrasclerotomal perichordal ring which arises in connexion with each sclerotome (PIIPER, 1928). The first occipital sclerotome is not so easily resolved into its constituent elements, but is none the less clearly individualized ; anterior to it extends the mesenchymatous forerunner of the parachordal. A segmental blood-vessel passes in front of the second occipital sclerotome, and in earlier stages (*e.g.*, 96 hours) a similar vessel passes in front of the first sclerotome and thus emphasizes the discrete nature of the latter.

In an embryo of 7 days, fig. 32, Plate 46, the skeletal elements are well defined in procartilage, and the parachordal is seen to extend back through the region previously occupied by the two independent sclerotomes. The sclerotomites of adjacent sclerotomes have now joined up to form vertebræ. The segmental nature of this posterior region of the skull is indicated by two transverse depressions in the ventral surface of the basal plate, which are to be regarded as marking the anterior faces of the two occipital vertebræ which have been absorbed here. That this is the correct interpretation of this region is shown by a comparison of the ventral nerve-roots with those of the preceding stage, figs. 8 and 9 ; this reveals that only two pairs of cervical ventral roots now lie in front of the first mixed nerve, the remainder, including those belonging to the two occipital sclerotomes, having become enclosed within the skull. Moreover, the hypocentrum of the second occipital vertebra (caudal sclerotomite of the second occipital sclerotome) is easily recognizable as a prominence immediately behind the second depression, fig. 32, Plate 46, *h.o.* 2, and the region between it and the posterior limit of the basis cranii represents, therefore, the body of the vertebra. The perichordal tissue has been shown to contribute pro- and opisthospondylous zones to the Avian vertebra (PIIPER, 1928), recognizable by the tangential arrangement of their cells, and it is therefore interesting to note that the hind end of the basal plate is made up of an extensive opisthospondylous zone. The hypocentrum of the first occipital vertebra is more difficult to recognize, but it can be identified by the arrangement of the nuclei.

In addition to the presence of these vertebræ, there are other indications of segmentation in the basal plate. It is characteristic of Anserine birds that the atlas rib is well developed and persists in the adult (*a.r* fig. 10). In front of it, in a duck of seven days, four pairs of condensations extend for a short distance lateral and ventral to the basal plate, the most posterior pair being associated with the hypocentrum of the second occipital vertebra. These have every appearance of being serially homologous with the cervical ribs, and they must be interpreted as vestigial cranial ribs belonging to the vertebræ which have been absorbed in this region, fig. 10 ; figs. 71–75, *c.r.* 6–9, Plate 52. A small quantity of blue-stained intercellular substance is visible in the posterior two pairs, fig. 31, Plate 46 ; the remaining ribs are much more reduced, as would be expected from the fact that their vertebræ have no longer an individual existence.

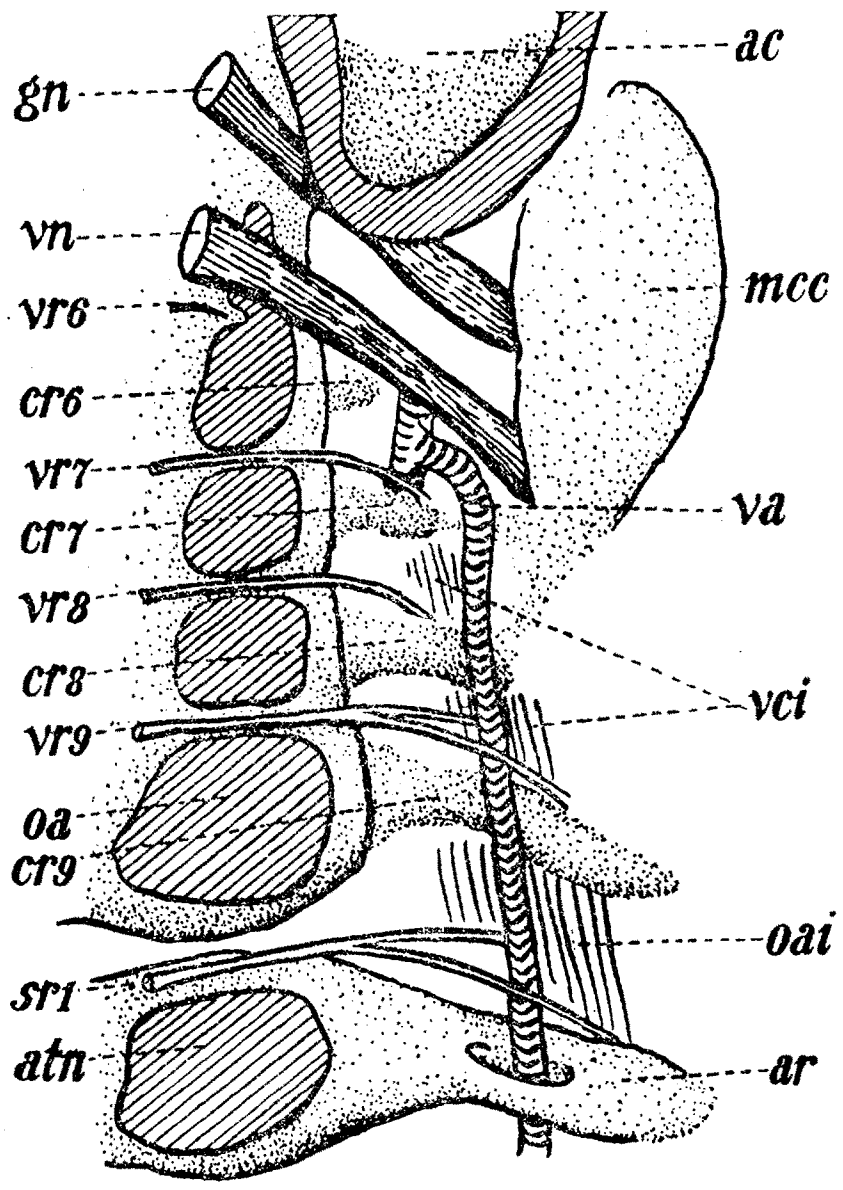

FIG. 10.—Reconstruction of right side of posterior region of the skull at 8-day stage, showing cranial ribs, seen from dorsal side.

With regard to the dorsal elements of the basal plate, a study of a whole preparation of the chondrocranium of a seven-day duck reveals four pairs of arches arising, each forming the posterior border of a future ventral nerve-root foramen. The arches soon become connected dorsally with the members of their own side, and the foramina are thus completed. The posterior arch (*o.a.* 9) continues to grow antero-dorsally, and forms the main occipital arch. The arch in front of it (*o.a.* 8) remains low, but is prominent in such sagittal sections as pass through the cervical neural arches, fig. 31, Plate 46. The remaining arches are even lower, and, in fact, lose almost all individuality; that it is justifiable to regard them as definite primary arches follows from their segmentation as revealed by the nerve-roots to which they are related.

(ii) *Discussion.*—The development and somitic constitution of the metotic region of the head of the bird has been a centre of much confusion in the literature. Certain of the earlier workers asserted that as many as three or four somites arose in front of the one earliest formed in ontogeny. This extreme view is, however, undoubtedly incorrect, and has been sufficiently criticized by PLATT (1889), whose interpretation alone need be considered here. She believed " that the first break in the mesoderm occurs anterior to the first protovertebra, and that two protovertebræ (or, more correctly, one and a half) are slowly formed anterior to the first mesodermic cleft, in the time occupied by the formation of six or seven protovertebræ posterior to that cleft.'' These two protovertebræ she called " *a* " and " *b* " respectively, the former being the more posterior.

Platt's view was contested by Patterson (1907) and Hubbard (1908), both of whom investigated the problem experimentally. The former opened eggs at a stage when only one mesodermic intersomitic cleft was present, made a mark with a needle just anterior to that cleft, and was then able to show that after further incubation to stages varying from 8 somites to 25 somites, the mark appeared in the so-called rudimentary (*i.e.*, anterior) somite. This was confirmed by Hubbard's work, which proceeded on similar lines. From these results the authors inferred that no somite, except the incomplete one, was formed anterior to the first cleft, and Patterson suggested that Platt had incorrectly interpreted certain shallow and transitory depressions in the " unsegmented mesoderm " anterior to the somites, and had been further misled by the fact that the first two or three clefts are not completed until the 6- or 7-somite stage. These conclusions have been adopted by Lillie in his well-known text-book (1908).

It has here been shown that the first metotic somite disappears early, and this implies that the " anterior " somite of Patterson must be regarded as the second metotic somite, for it was described by him up to as late a stage as 25 somites. At this stage in the duck, the first metotic somite has long since disappeared, and it seems unlikely that conditions in the chick would be so profoundly different. As a matter of fact, Jager (1924) has described in the chick a rudimentary first metotic somite resembling in its relations the corresponding somite in the duck, and there can be little doubt but that conditions in the two forms are essentially similar. It would seem that both Patterson and Miss Hubbard overlooked this first metotic somite because their methods were not calculated to detect a later-developing somite which was both rudimentary and transient. Their observations are, nevertheless, of great importance in tracing the history of the somites prior to the 7-somite stage. In these earliest stages the auditory placode is absent, and it is impossible on morphological grounds to identify with certainty any given somite, and correspondingly impossible to determine in what order these somites develop. The experimental work shows, however, that the second metotic somite develops in front of that intersomitic mesodermic cleft which appears first in time, and that the transitory first metotic somite must therefore develop later than that second somite.

It is to be noted that Rex (1905) observed this phenomenon. He distinguished a dense distal region of the " unsegmented mesoderm " (of the gull) which showed an epithelial arrangement at the 7-somite stage; subsequently dedifferentiation set in. In the course of an excellent description he writes that it is as though there was not sufficient energy present to enable the structure to complete its development. He does not, however, regard it as a true somite, and expresses the view that it owes its origin to an overflow of material from the first somite and therefore develops *pari* *passu* with the latter. He is thus able to maintain that the first metotic somite in the series is also the first to appear in time. Nevertheless, the structure described in the present work is so well defined that it seems impossible to regard it as anything but a true, although vestigial, somite, and it has already been mentioned that JAGER has come to the same conclusion. Moreover, the existence of such a somite is to be expected on morphological grounds, for it is well known that in Selachians the first metotic somite disappears early without forming any muscle-fibres, and that the first permanent myomere, lying immediately behind the vagus, arises from the third metotic somite. Thus the conditions in Selachians and birds correspond somite for somite with the expected difference that in the latter group the first metotic somite is still further reduced. The first metotic segment must therefore be the fourth of the whole series, and all the somites are accounted for.

It may be added that a study of Miss PLATT's figures shows that in her " somite *b* " she correctly identified the first metotic somite at the 7-somite stage, but was subsequently misled by a failure to envisage the possibility of its rapid disappearance. Thus the " somite *b* " in her fig. 11 is in reality " somite *a* " (*i.e.*, the second metotic somite), " somite *b* " having already disappeared.

CHIARUGI (1890), as a result of his work on the chick, not only claimed that two somites were differentiated postero-anteriorly in front of the first-developed pair, but also described rudimentary somites appearing in front of these as far as the acustico-facialis ganglion, and quickly disappearing. This is mentioned here because a somewhat similar idea has been put forward by PATTERSON in the paper discussed above. After expressing the belief that PLATT had been misled by the appearance of transitory depressions in the " unsegmented mesoderm," he goes on to suggest that these same depressions might be interpreted " as vestigial clefts separating the mesoblastic somites . . . the influence of the process which has completely obliterated or greatly modified the anterior cephalic somites, gradually becomes weaker in passing posteriorily, and finally ceases altogether." These suggestions are, of course, merely speculative. The alleged " somites " never show a definite radial condensation characteristic of true somites; their appearance is due merely to the attenuated and irregular form of the mesenchymatous tissue, and so far as they have any significance at all they are to be interpreted as an index of growth, being nothing more than regions of temporary cell-proliferation (BRACHET, 1921, p. 362). It is hardly necessary to point out that there is nothing in Cyclostomes or Selachians* corresponding to these alleged somites, for in those forms the first metotic somite, which belongs to the glossopharyngeal nerve, follows immediately upon the third prootic somite. If, then, there were such rudimentary somites in birds, it would have to be supposed that they represented somites which had moved forwards beneath

---

* The presence of a large number of metotic " somites " was at one time alleged in Torpedo, but more recent work has shown that the appearance described is due to the secondary breaking up of the three metotic somites (for references, see GOODRICH, 1918).

the auditory capsule, a conception which has owed much in the past to the speculations of FÜRBRINGER (1897). He believed that in each group of vertebrates the occipital arch occupied a fixed and definite position, and that variations in the number of occipital ventral nerve-roots were to be explained by the disappearance of protometameric segments, which had formerly existed in the auditory region. It must be emphasized that there is no evidence of phylogenetic changes of such a nature. " On the contrary there is good reason to believe that for the most part myotomes once laid down persist, and that the chief change that takes place in the course of ontogeny is the crushing of the anterior myotomes owing to the growth backwards of the auditory sac and capsule, of the vagus, and of the gill sacs " (GOODRICH, 1918). The only case so far known of a myotome laid down and subsequently disappearing is that of the transient occipital myotome which arises from the second metotic somite, as already described. With regard to its dissolution, the findings reported here agree with those of JAGER (1924), except that the process is slightly retarded in the duck. This seems to be a general characteristic of the latter as compared with the chick, and is illustrated also in the time-relations of the first metotic somite and in the fact that the anterior head cavity is still present in the duck when the eye-muscles begin to form, while it has already disappeared at the corresponding stage in the chick (ADELMANN, 1927). In the gull, the second metotic somite appears to disintegrate somewhat earlier, for even as early as the 12-somite stage, REX (1905) describes this somite as represented only by a condensation of radiating cells at its posterior border. BUTCHER (1929) notes the similarity of this to the conditions in the rat. However, it is certain that in all of these forms, the muscle-fibres of the second metotic somite have lost their individual existence by the 30-somite stage, and this accounts for the frequent assertions in the literature to the effect that only four myotomes arise in the head in birds.

CHIARUGI (1890) described the development of only three occipital ventral nerve-roots in the chick, but JAGER (1924) has described four, which agrees with the conditions in the duck reported here. A feature of some interest is the fact (reported later, p. 433) that as many as five hypoglossal foramina can be seen in the basal plate of the skull of the duck. These obviously correspond to the 2nd to 6th metotic segments, and it is interesting to find that a foramen in the cartilage may persist (in this case, that of the 2nd metotic segment) although the nerve-root which originally penetrated through it may no longer be discernible.

(iii) *Conclusion.*—We may, then, conclude by stating that the posterior limit of the skull of the duck is formed by an included vertebra, the anterior portion of which arises from the posterior sclerotomite of the 6th metotic segment, and the posterior portion of which therefore arises from the anterior sclerotomite of the 7th metotic segment. The joint between the skull and the first or atlas vertebra is intervertebral, and therefore intra-segmental, viz., in the middle of the 7th metotic segment. The skull therefore occupies $6\frac{1}{2}$ metotic segments, and since there are 3 prootic somites, and there is every reason to believe that the first metotic somite follows directly upon the 3rd prootic somite, $9\frac{1}{2}$ segments go to make up the skull of the duck.

V. The Chondrification of the Skull of the Duck.

A.—Description of Stages.

Stage 1. 132 hours; fig. 33, Plate 47.—The first element of the bird's skull to become chondrified is the acrochordal cartilage, which takes the form of a small transverse bar, at the tip of the notochord. We have succeeded in the chick in finding this cartilage at a stage (4½ days) when no other elements are chondrified, and therefore confirm Sonies' (1907) description. The same is probably true of the duck, but the earliest stages which we have studied with any cartilage at all show (5½ days) the parachordal (*p.*) in addition to the acrochordal (*a.*); the latter is, however, better developed and gives the impression of having arisen first.

As maintained by van Wijhe (1922) and Jager (1924), and confirmed by de Beer (1926 *b*, 1931, *b*), the acrochordal arises in connexion with the mesenchyme which has been formed by the breaking down of the hollow transverse commissure between the paired first prootic somites; it therefore represents the most anterior portion of the axial skeleton and of the basal plate.

The parachordal cartilage in the duck would be more appropriately termed the perichordal cartilage, for it forms a cylinder enclosing the notochord, about ½ mm. long, with its foremost point about 0·7 mm. behind the acrochordal. The parachordal, here, then, cannot be said to be a paired structure, and in this it is undoubtedly secondarily modified.

Behind the parachordal in the duck embryos at the stage described, there can be seen three separate rings of cartilage surrounding the notochord (*o.v.* 1, *o.v.* 2, *a.t.*). Comparison with later stages shows that these represent two vertebræ which will become incorporated in the skull (the 1st and 2nd occipital vertebræ) and the first vertebra of the neck, or atlas vertebra. We are thus able to confirm the important observations of Sonies (1907) and Jager (1924) in this respect.

Another pair of chondrifications which appear very early are the rudiments of the cochlear portions of the auditory capsules (*c.c.*). At this stage, they are just recognizable as faint tracts of blue-stained tissue, on each side of, but distinct from, the anterior end of the parachordal. These are the cartilages which Sonies called mesotic or basiotic. They clothe the median faces of the cochlear portions of the auditory sac, and are the first part of the auditory capsules to undergo chondrification. The fact that they are independent of the parachordal is of theoretical importance, since it further invalidates Gaupp's theory (already contradicted for the mammal by Noordenbos (1905), de Beer (1929), and de Beer and Woodger (1930)), that the cochlear portion of the auditory capsule is a modified derivative of the basal plate of the skull.

Stage 2. 138 hours; figs. 34, 35, Plate 47.—The acrochordal cartilage is slightly larger, and, at each side, it extends into a process which is the rudiment of the pila antotica (*p.a.*). At the base of each pila antotica is a notch for the abducens nerve (*n.ab.*).

Immediately behind the acrochordal, and on each side of the notochord but diverging away from it as it runs backwards, is a small bar of cartilage. This pair of cartilages will ultimately form part of the basal plate, and will enclose the basicranial fenestra between them, when they have established connexion with the parachordal and the cochlear capsules. Attention has not been drawn to them before, and it is proposed to call them the anterior parachordal cartilages (*a.p.*). It may be noted that they preserve their paired nature.

The cochlear capsules are now in cartilaginous continuity with the front of the parachordal cylinder although the distinction between them can still be made out. Posteriorly, the parachordal and the first and second occipital vertebræ have become synchondrosed, but the latter can be clearly recognized (*o.v.* 1, 2). In lateral view the hypocentra of the two occipital vertebræ project ventrally below the level of the remainder of what may now be called the basal plate. The atlas and axis vertebræ are well defined, and each has a well-marked hypocentrum, that of the atlas being the larger (*h.a*), and more or less distinct from the ring-shaped body or pleurocentrum of its vertebra, which is destined to give rise to the odontoid process. It has not been possible to observe the transient connexion, described by JAGER (1924) between the atlas hypocentrum and the posterior end of the basal plate.

Stage 3. 144 hours; figs. 36, 37, Plate 47.—The trabeculæ (*t.*) have now arisen as cartilaginous bars, paired and separate, beneath the floor of the forebrain. They are quite wide apart, as if the skull of the bird were destined to be platitrabic instead of tropitrabic. Between the trabeculæ and the acrochordal, and likewise isolated, the polar cartilages (*p.c.*) have made their appearance as spheroidal nodules, in line with the hind ends of the trabeculæ.

The pila antotica is better developed and is extending upwards and forwards; the notch is at its base for the abducens is plain. Dorsal to each polar cartilage and ventro-anterior to each pila antotica, another pair of chondrifications has appeared, known as the suprapolar cartilages (*s.t.*). They correspond to the supratrabecular bars which in the lizard (GAUPP, 1906) and in the Primates (FISCHER, 1903) connect the anterior with the posterior clinoid processes. The ophthalmic artery runs out beneath them, and their precocious appearance is probably related to the fact that the recti muscles are attached to them.

The anterior parachordals have established connexion with the parachordal and cochlear capsules, and the basal plate is now complete, enclosing a basicranial fenestra (*b.c.f.*). At the same time, the basal plate is extending to the side, by lateral growth of the originally cylindrical parachordal. The hypocentra of the two occipital vertebræ are still visible, and the atlas and axis vertebræ are as before, except that their neural arches have now arisen as separate paired struts of cartilage (*a.t.n.*, *a.x.n.*).

The first appearance of the visceral arch skeleton is found at this stage, in the form of the rudiments of the quadrate cartilages (*q.*), and of the median unpaired copula (*cop.*).

Stage 4. 156 hours; figs. 38, 39, Plate 47.—The skull at this stage is, in the main, similar to the preceding stage; the trabeculæ, polar cartilages, and suprapolar cartilages, are still separate, but in other directions some important advances have taken place. A band of procartilaginous tissue, staining faintly with victoria blue, is discernible stretching between the polar cartilage and the quadrate on each side. This cannot be anything other than the vestige of the basal articulation between the mandibular arch and the neurocranium, *i.e.*, between the basal process of the former and the basitrabecular process of the latter.

The canalicular portion of the auditory capsule has now begun to chondrify as a curved plate, quite isolated, and covering the lateral and posterior surfaces of the semicircular canals (*c.a.c.*).

Two pairs of occipital arches are now visible at the hind end of the basal plate (*o.a.* 8, 9). These obviously belong to the two absorbed occipital vertebræ, of which they represent the neural arches, and they therefore belong to the 8th and 9th segments. The hypocentrum of the 2nd (absorbed) occipital vertebra is still plainly visible (*h.o.* 2).

Stage 5. 160 hours; figs. 40, 41, Plate 47.—The chief interest of this stage lies in the fact that the trabeculæ have undergone further development. In the first place they are joined together anteriorly, forming an ethmoid plate (*e.p.*) which constitutes the anterior limit to the hypophysial fenestra (*h.fe.*). This fenestra is not yet completely enclosed, for the polar cartilages are still free from the acrochordal, but they are attached, each to the hind end of the trabecula of its own side, by procartilage.

From each trabecula, near its anterior end, there arises a process which projects laterally, and slightly forwards and upwards. This is the first appearance of the structure which SONIES (1907) regarded as the lamina orbitonasalis, but which, as we shall see, is really the anterior portion of the orbital cartilage, with its preoptic root (*o.c.a.*). This is a matter of importance, for except on this view it is impossible to understand the conditions in this region of the skull at later stages of development.

The canalicular part of the auditory capsule is faintly connected with the cochlear portion by a strand of tissue which marks the anterior limit of the fissura metotica. Laterally to the cochlear capsule, the rudiment of the columella auris (*c.a.*) can be seen as an isolated structure. This structure is, of course, the dorsal extremity of the skeleton of the hyoid arch, and these investigations afford no support whatever for SUSCHKIN'S opinion (1899) that it arises in connexion with the wall of the auditory capsule.

There is no longer any trace of the connexion between the polar cartilage and the quadrate. In the first branchial arch, the ceratobranchial element is just discernible as a procartilaginous rudiment (*c.b.*).

Stage 6. 7 days; fig. 11; figs. 42, 43, Plate 47.—The hypophysial fenestra has been completed by the fusion of the polar cartilages with the acrochordal; the fusion is, however, slender, and the position of the originally isolated polar cartilages is plainly visible. From the ventro-posterior surface of each polar cartilage, a process is directed backwards towards the under surface of the basal plate, which, however, it does not yet reach. This is the infrapolar process (*ip.p.*); it passes ventrally and medially to the internal carotid arteries which, in this region, run inwards towards the hypophysial fenestra through which they penetrate into the cranial cavity.

At the hinder end of the basal plate, four pairs of occipital arches are now present (*o.a.* 6–9), corresponding to the 6th–9th segments. This means that in addition to the two absorbed occipital vertebræ (represented now by the occipital arches of segments 8 and 9), the hinder portion of the originally continuous and unsegmented parachordal cylinder shows evidence of metameric segmentation. Between every two occipital arches on each side, a root of the hypoglossal nerve emerges.

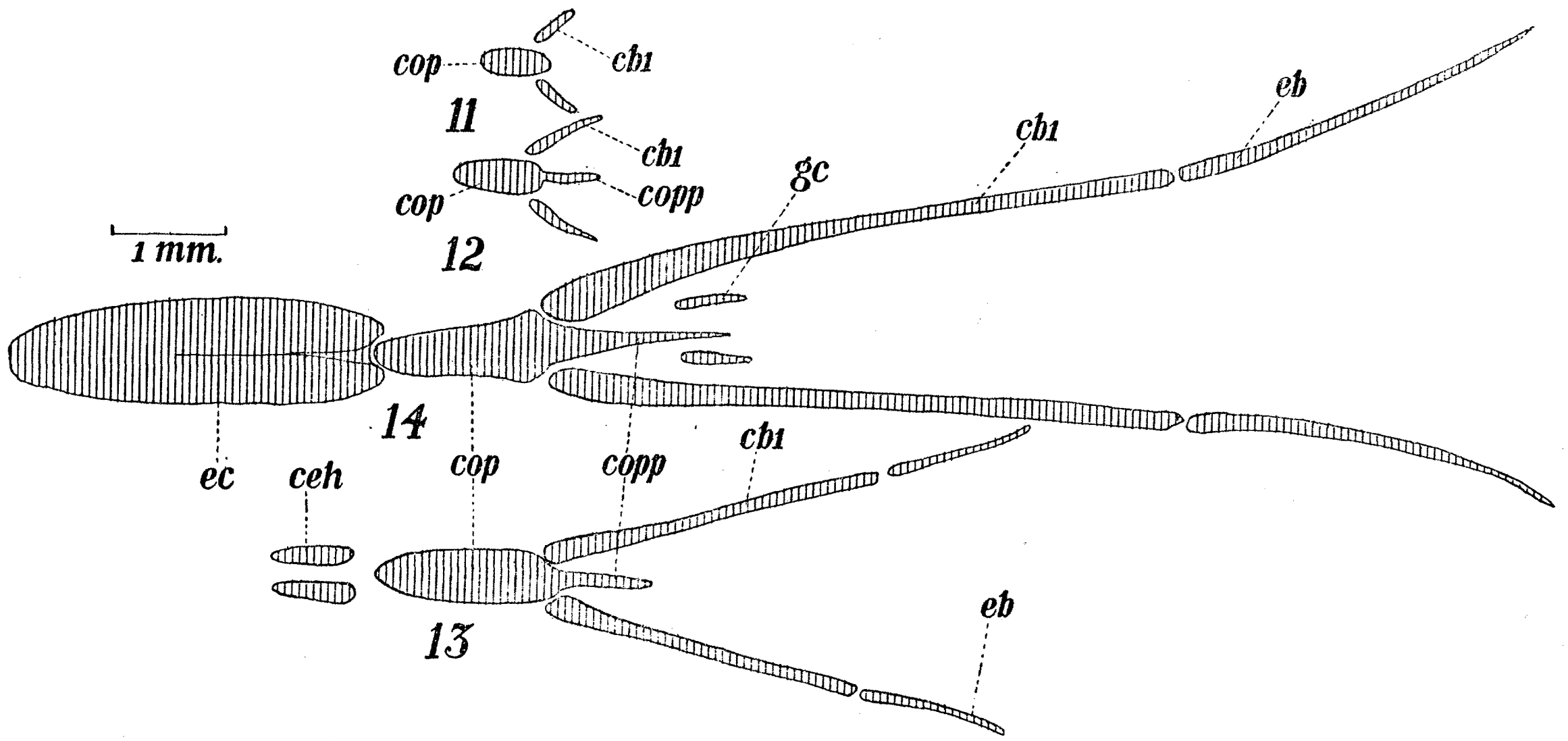

FIG. 11.—Dorsal view of hyo-branchial skeleton at 7-day stage. FIG. 12.—Ditto at 8-day stage. FIG. 13.—Ditto at 11-day stage. FIG. 14.—Ditto at 14-day stage.

As regards the visceral skeleton, MECKEL'S cartilage has now made its appearance (*M.c.*), but on each side it chondrifies from two centres.

Stage 7. 7½ days; figs. 44, 45, Plate 48.—The hypophysial fenestra has been reduced in size by the fusion of the anterior portion of the trabeculæ in the middle line to form the trabecula communis (*t.c.*). At the same time, the somewhat indistinct region of the ethmoid plate is becoming deeper in the sagittal plane, and the nasal septum (*s.n.*) is now visible. Anteriorly, the nasal septum is prolonged into the prenasal process (*pn.p.*). All these structures have chondrified in connexion with the trabeculæ, and have not arisen from independent centres.

The suprapolar cartilages have become attached to the dorsal surface of the polar cartilages of their own side, by two fusions, so as to enclose the ophthalmic artery in a foramen (*f.o.p.*). Between the posterior edge of the suprapolar cartilage and the anterior edge of the pila antotica on each side, there is a notch through which the oculomotor nerve passes (*n.o.*). The trochlear nerve has now become enclosed in a foramen (*f.t.*) in a growing plate of cartilage, the posterior portion of the orbital cartilage (*o.c.p.*) which chondrifies in connexion with the dorsal end of the pila antotica. Similarly, the abducens nerve has become enclosed in a foramen at the base of the pila antotica, but this is difficult to see in whole preparations. The canalicular capsule is now more fully developed, and the paths of the three semicircular canals can be seen by transparency. Posteriorly, the occipital arches have become joined distally so as to enclose 3 hypoglossal foramina (*h.f.*) on each side.

In the mandibular arch, MECKEL'S cartilage is now a single element on each side, while the quadrate shows both otic (*o.p.*) and pterygoid processes (*p.p.*).

Stage 8. 8 days; figs. 10, 12 and figs. 46–48, Plate 48; figs. 71-75, Plate 52.—In many ways, this stage is one of the most interesting, and deserves a full description. Beginning at the anterior end, it may be noticed that the prenasal process (*pn.p.*) is elongating, and that the dorsal edge of the nasal septum is extending on each side to form the parietotectal cartilages (*pt.c*), which will give rise to the roof and to the greater part of the side walls of the nasal capsule. Behind the nasal septum, the interorbital septum (*i.s.*) is rising up, carrying the preoptic roots of the orbital cartilage with it. Both the anterior and posterior portions of the orbital cartilages are expanding; the former (*o.c.a.*) is spreading out on each side beneath the cerebral hemispheres, while the latter (*o.c.p.*), attached by the pila antotica to the basal plate, is spreading out sideways and presents a curvature, being concave towards the now enormous eye.

The canalicular and cochlear portions of the auditory capsule are now connected by cartilage, both anteriorly and posteriorly. Between the posterior orbital cartilage, pila antotica, anterior parachordal, and auditory capsule there is now, therefore, a deep and wide notch, the incisura antotica, through which all the branches of the trigeminal nerve emerge. It is important to notice the fact that the pila antotica (*p.a.*) here possesses its typical relation, lying in front of all the trigeminal roots.

The posterior or definitive occipital arch (*o.a*) is growing upwards and forms a posterior boundary to the fissura metotica (*f.m.*), through which the glossopharyngeal, vagus, and spinal accessory nerves emerge. Opposite the centre of the fissura metotica, however, and ventral to the canalicular portion of the auditory capsule, an isolated cartilage has made its appearance; following SONIES this may be called the metotic cartilage (*mc.c.*). SONIES has no explanation to offer regarding the nature of this cartilage, but it seems to be developed in connexion with the cranial ribs, to which attention must now be turned.

At this stage of development in the duck, 4 cranial ribs can be recognized on each side (*c.r.* 6–9), corresponding to segments 6 to 9. They take the form of dense mesenchymatous tissue, which, at least in the posterior ones, shows some intercellular substance. They are seen in figs. 71 to 75, Plate 52, and a reconstruction is given in fig. 10. In addition to the evidence of metameric segmentation which these ribs show, for they alternate with the hypoglossal nerve roots (*v.r.* 6–9) in typical manner, these ribs are of interest because a mesenchymatous connexion can be made out between them and the metotic cartilage (*mc.c.*). SONIES has observed these structures, but denies their costal nature, on grounds which seem wholly insufficient. It may be mentioned that SUSCHKIN found 4 pairs of cranial ribs in Tinnunculus, that cranial ribs occur in the mammal, giving rise to the so-called paracondylar process (DE BEER and WOODGER, 1930), and that in the crocodile (SHIINO, 1914), the subcapsular process shows great similarities with the metotic cartilage and is also to be regarded as a cranial rib.

In the visceral arches, the duck at this stage shows that the otic process of the quadrate and the retro-articular process of MECKEL'S cartilage (*p.r.a.*), have developed. The copula shows a slender process directed backwards; this is really the second copula which has fused on to the hind end of the first.

Stage 9. 8½ days; figs. 50, 51, Plate 48.—The developments which characterized the previous stage have become accentuated in this; the prenasal process (*pn.p.*) is longer, the anterior (*o.c.a.*) and posterior (*o.c.p.*) portions of the orbital cartilage have expanded further, the parietotectal cartilages (*pt.c.*) of the nasal capsule have extended, and the interorbital septum (*i.s.*) is higher. A vacuity (*v.o.*) has appeared in the posterior orbital cartilage, and with the widening of the basal plate, more hypoglossal foramina (*h.f.*) have become enclosed; of these there are 5 on one side and 4 on the other. The walls of the auditory capsule are nearly complete, and reveal, on the outside, the foramen ovale (*f.o.*) into which the foot of the columella auris (*c.a.*) fits, and the foramen perilymphaticum (*f.pl.*) which faces towards the fissura metotica (*f.m.*); and, on the inside a large opening which will eventually become narrowed down to the foramina for the auditory nerve. The facial nerve is separated from the incisura antotica (*i.p.*) by the prefacial commissure, and enclosed in the facial foramen (*f.f.*).

But this stage also shows some important new developments. Two pairs of independent cartilages have appeared in the region of the nasal capsule; these are the paranasal cartilages (*pn.c.*) and the plana antorbitalia (*p.an.*). The former are curved and show a marked concavity facing outwards, which will give rise to the concha nasalis (*c.n.*). The plana antorbitalia form the posterior wall of the nasal capsule on each side, and are homologous with the laminæ orbito-nasales of other forms (Scyllium (DE BEER, 1931, *a*), Salmo (DE BEER, 1927), Lacerta (DE BEER, 1930), Lepus (DE BEER and WOODGER, 1930)), as their relations to the nasal branch of the profundus nerve show. The planum antorbitale forms the lower border of the orbitonasal fissure. This fissure is not yet completely delimited, for its lateral border will not be formed until the parietotectal cartilage becomes connected with the planum antorbitale, but its dorsal border is now present in the sphenethmoid commissure (*se.c.*), which joins the parietotectal cartilage to the anterior orbital cartilage.

Posteriorly, the metotic cartilage (*mc.c.*) has become fused with the base of the occipital arch, from which it projects forwards and outwards, beneath the auditory capsule, and presents an unmistakable resemblance to the subcapsular process of the crocodile.

In the hyoid arch, the stylohyal cartilage (*s.h.*) has appeared in procartilaginous connexion with the outer end of the columella auris, but from a separate centre of chondrification.

Stage 10. 9 days; fig. 49, Plate 48; figs. 52, 53, Plate 49.—The chief points of interest of this stage are the increase in height of the interorbital septum (*i.s.*); the development of a band of cartilage stretching back from the anterior orbital cartilage on each side towards the posterior orbital cartilage; this may be termed the supra-orbital cartilage (*t.m.*); and the expansion of the metotic cartilage (*mc.c.*). The latter is spreading forward, and at the same time its medial margin is approaching the lateral margin of the basal plate in the region between the glossopharyngeal and vagus nerves. In some embryos at this stage, cartilaginous fusion has here taken place, with the result that the fissura metotica is divided into two portions; an anterior slit (*f.g.*) through which the glossopharyngeal emerges, and a posterior slit (*f.v.*) which serves for the exit of the vagus and spinal accessory.

The whole skull is now beginning to assume the characteristic form of the bird's chondrocranium. In particular, it may be noticed how the orbital region is adapted to the enormous size of the eye, as evidenced by the height of the interorbital septum, and the concave faces which the planum antorbitale (*p.an.*) and posterior orbital cartilage (*o.c.p.*) present to it.

Stage 11. 9 days; figs. 54, 55, Plate 49.—This stage is among the most important, for the chondrocranium of the bird now exhibits its maximum resemblance to that of certain reptiles. In the first place, it is to be noted that the orbital cartilage is complete, the anterior orbital (*o.c.a.*), supra-orbital (*t.m.*), and posterior orbital cartilages (*o.c.p.*) having fused on each side, so as to form a continuous lateral wall to the cranial cavity, extending from the sphenethmoid commissure (*se.c.*) to the pila antotica (*p.a.*). A large sphenoid fontanelle is thus enclosed on each side; dorsal to the suprapolar cartilage, posterior to the interorbital septum and preoptic root of the orbital cartilage, anterior to the pila antotica, and ventral to the orbital cartilage. Through this fontanelle, the optic, oculomotor, and trochlear nerves emerge, for the latter has now been released from its foramen in the posterior orbital cartilage. In such reptiles as Lacerta, Sphenodon, and Crocodilus, the sphenoid fontanelle is subdivided by a pila metoptica, pila accessoria, and tænia medialis into three foramina, viz., opticum, epiopticum and metopticum. The duck at the stage under discussion shows a rudimentary attempt at a similar subdivision, for an isolated chondrification (*t.m.e.*) is present in the middle of each sphenoid fontanelle, and probably represents a portion of the tænia medialis.

Anteriorly, the nasal capsule is becoming more complete. It is important to notice that the lateral edge of the planum antorbitale (*p.an.*) juts out to the side beyond the side wall of the nasal capsule. Just in front of the planum antorbitale, the concha nasalis (*c.n.*) (superior or posterior turbinal of other authors) formed by the concave paranasal cartilage is plainly visible.

The olfactory nerve passes out of the cranial cavity through a foramen olfactorium evehens (*f.o.e.*), which is bordered by the front edge and preoptic root of the anterior orbital carilage (*o.c.a.*), the sphenethmoid commissure (*se.c.*), the nasal septum, and part of the hind edge of the parietotectal cartilage (*pt.c.*). The olfactory nerve then finds itself for a short distance in the orbit, which it leaves by the foramen olfactorium advehens (*f.o.a.*) for the cavity of the nasal capsule. The latter foramen is difficult to delimit, but its boundaries may be said to be constituted medially by the nasal septum; anteriorly and laterally by the hind edge of the parietotectal cartilage; and posteriorly by the dorsal edge of the planün antorbitale. The orbitonasal fissure is still more difficult to define, owing to the fact that it is so very large; its medial boundary is the interorbital septum and preoptic root of the orbital cartilage; its ventral boundary is the dorsal edge of the planum antorbitale; its dorsal boundary is the sphenethmoid commissure, while its lateral boundary is formed by part of the hind edge of the parietotectal cartilage.

Difficult as these relations are to make out, it is important to define them at this stage, for, as will be seen, at subsequent stages most of the landmarks will have either disappeared, or undergone modification and displacement. Indeed, a certain amount of displacement has already occurred; the preoptic root of the orbital cartilage has been carried up to a great height dorsally by the phenomenal development of the interorbital septum, and the parietotectal cartilage will soon begin to extend backwards, dorsally to the foramen olfactorium evehens.

Turning now to the posterior region of the skull, it may be noticed that the metotic cartilage (*mc.c.*) has become attached by its dorsal border to the side wall of the canalicular portion of the auditory capsule. The ventro-medial edge of the metotic cartilage is fused to the lateral edge of the basal plate at a point between the foramina for the glossopharyngeal (*f.g.*) and vagus nerves (*f.v.*), and, with the increasing fusion between the anterior edge of the occipital arch and the posterior surface of the canalicular portion of the auditory capsule, these two foramina are all that remains of the originally extensive fissura metotica.

By its conformation and its adhesions to neighbouring cartilages as just described, the metotic cartilage forms a covering from the side and from behind to the recessus scalæ tympani, into which the foramen perilymphaticum of the auditory capsule opens. The free edge of the metotic cartilage forms a crest which extends forwards and upwards, almost to the otic process of the quadrate.

The dorso-posterior corners of the auditory capsules are connected with one another across the middle line by a transverse bar of cartilage, forming the tectum synoticum (*t.s.*). This structure probably has a paired origin, but this was not directly observed.

The hind edge of the basal plate now, therefore, comes to form the ventral border of the foramen magnum, and, immediately on each side of the notochord, a pair of prominences have developed. These are destined to form the single median occipital condyle (*c.*); here, they are in the form of the paired elements of the pleurocentrum of the 2nd (absorbed) occipital vertebra; *i.e.*, they represent the anterior sclerotomites of the 7th metotic segment, or 10th segment of the entire series. This feature is of importance in showing the intervertebral (intrasegmental) nature of the occipito-atlantic joint in birds.

In the visceral arch skeleton, the only points worthy of notice are the great elongation of MECKEL'S cartilage, which keeps pace with that of the prenasal process, and the separation of the stylohyal cartilage from the columella auris.

Stage 12. 11 days; fig. 13; fig. 56, Plate 49.—The chief feature presented by this stage is the reduction almost to disappearance of the anterior orbital and supra-orbital cartilages. The connexion with the posterior orbital cartilage has vanished, and the sphenethmoid commissure has broken down. All that is left of the extensive anterior orbital cartilage of the previous stage is a pair of thin strips (*p.s.*) lying along the dorsal edge of the interorbital septum, and forming a structure similar to that which GAUPP (1900) in Lacerta has called the planum supraseptale. Its paired nature is still obvious, and anteriorly, it runs into the sphenethmoid process (*se.p.*), on each side, representing the posterior remnant of the sphenethmoid commissure. The anterior remnant of this commissure may now be recognized on each side as the backwardly-projecting processus tectalis (*p.t.*). The boundaries of the foramen olfactorium evehens and of the orbitonasal fissure are now, therefore, indistinct.

For the greater part of its length, the planum supraseptale (*p.s.*) is more or less horizontal, underlying the telencephalon; but its hindmost portion slants downwards and backwards. This portion is marked off from the underlying interorbital septum by extensive slit-like fissures, and gives the impression of having had a paired origin separate from that of the remainder of the planum supraseptale. It is possible that this hindmost portion (*p.s.p.*) is derived from the pair of isolated chondrifications described in stage 11 as probably representing the tænia medialis (*t.me.*) of reptiles; these cartilages would have become attached to the hindmost upper corner of the interorbital septum, immediately behind the anterior orbital cartilages, and would thus correspond to the structures which SUSCHKIN (1899) has described as "orbito-sphenoids" in Tinnunculus.

The posterior orbital cartilages show a very interesting development. As at previous stages, each is attached to the basal plate by means of a pila antotica (*p.a.*) which is situated in front of all the roots of the trigeminal nerve. But at this stage, the posterior orbital cartilages have extended sideways and backwards to a remarkable extent. This is probably associated with the large size of the eye-ball, round the hinder side of which the posterior orbital cartilage is moulded, and with the large size of the trigeminal ganglion. Be this as it may, the result is that the ventral edge of the posterior orbital cartilage approaches close to the lateral edge of the basal plate at a point situated between the exits of the profundus (*V* 1) and maxillary (*V* 2) branches of the trigeminal nerve. Here, therefore, the profundus root emerges through the extreme anterior part (*n.p.*) of the original incisura antotica (*i.p.*), which already shows signs of ultimate constriction into a separate foramen.

In the visceral arches, a new feature is the appearance of paired ceratohyal cartilages (*ce.h.*), in front of the copula. Behind the ceratobranchials, epibranchial cartilages (*eb.*) have appeared in the first branchial arch.

Stage 13. 14 days; fig. 14; figs. 57–66, Plates 50, 51. The chondrocranium has now practically reached its maximum state of general development, although, as has already been seen, some structures such as the complete orbital cartilage have undergone regression.

The most striking feature is the great elongation of the prenasal process (*pn.p.*), parallel with that of Meckel's cartilages (*M.c.*). The anterior part of the nasal capsule is still very incompletely chondrified, but the posterior part is now well formed. On each side, the concha nasalis (*c.n.*) forms a deep inpushing, opening outwards, and situated immediately in front of the planum antorbitale (*p.an.*). The wall of the concha passes anteriorly into the parietotectal cartilages (*pt.c.*), which forms the roof and side walls of the greater part of the capsule. Close to its ventral edge, each side wall gives off an elongated scroll-like structure, curved in such a way as to form a half-cylinder, the concavity facing sideways and downwards. This is the maxillo-turbinal (*m.t.*). Posteriorly, the maxillo-turbinal extends beneath the concha nasalis forming a floor to the hindmost region of the capsule. Dorsal to this floor, and ventral to the aperture of the concha and to the latero-ventral edge of the planum antorbitale, is the aperture through which the nasal sac communicates with the orbital sinus (*a.s.or.*). The anterior cupula, fenestra narina, and atrio-turbinal are not yet chondrified. Two fenestræ are to be seen in the nasal septum, and in one place beneath its ventral edge are to be seen the nodules of secondary cartilage representing the prevomer bones (*pv.c.*).

On the dorsal side of the nasal capsule, the roof (*b.r.*) has grown still further back and become fused with the interorbital septum; two vacuities in the roof are left, in this process. The olfactory nerve runs forwards beneath this backgrowing roof and thus traverses a portion of the orbit on its way to the foramen olfactorium advehens (*f.o.a.*). Thus the gap between the backgrowing roof and the interorbital septum seen in side view in fig. 57, Plate 50, is not to be mistaken for the gap between the interorbital septum and the sphenethmoid commissure—really the foramen olfactorium evehens—through which the olfactory nerve passes, seen in fig. 54, Plate 49, and previous stages.

The planum supraseptale (*p.s.*) is still further reduced, and it is the disappearance of this, the anterior orbital cartilage which normally separates the olfactory nerve from the orbit, which is responsible for the passage of this nerve through the orbit in the duck. The posterior portion of the planum supraseptale (*p.s.p.*) has now assumed a vertical position, and lies just above the exits of the optic nerves. Two fenestræ have been formed in the interorbital septum (*v.s.*).

The posterior orbital cartilage on each side has established a secondary connexion with the lateral edge of the basal plate, between the profundus and maxillary branches of the trigeminal nerve. This connexion, which it is proposed to call the pila antotica spuria (*p.a.s.*), thus encloses the profundus nerve in a foramen of its own (*f.p.r.*), of which the true pila antotica (*p.a.*) forms the slender median and dorsal margin. The maxillary and mandibular branches of the trigeminal nerve emerge behind the pila antotica spuria, through what may be called the incisura antotica spuria (*f.p.s.*) which is almost converted into a foramen by the approximation of the orbitocapsular process (*o.c.p.r.*) of the posterior orbital cartilage to the prootic process (*p.r.o.*) of the auditory capsule. A postorbital process (*p.o.p.*) projects forwards from the extreme lateral edge of each posterior orbital cartilage. These cartilages also show a fenestra (*v.o.*) or vacuity as a result of absorption.

The infrapolar processes (*ip.p.*) have established contact with the ventral surface of the basal plate, with the result that each of the internal carotid arteries on its way to the hypophysial fenestra has to pass through a foramen—the lateral carotid foramen (*l.c.f.*).

As regards the hinder region of the skull, the number of hypoglossal foramina (*h.f.*) is undergoing reduction, the occipital condyle (*c.*) is increasing in size, and the tectum synoticum has become interrupted so that instead of the continuous bar of cartilage which at previous stages stretched from one auditory capsule to the other, there are now two processes projecting dorsally side by side : the supra-occipital processes (*s.o.p.*). The occipital arches (*o.a.*) end dorsally as blunt points medially to the base of the supra-occipital processes

The metotic cartilage (*mc.c.*) is now an integral part of the chondrocranium, and sends forwards a subcapsular process (*sc.p.*). The foramina for the glossopharyngeal (*f.g.*) and vagus (*f.v.*) nerves serve to indicate the position of the original fissura metotica, and of the line of fusion between the metotic cartilage and the lateral edge of the basal plate. Dorso-anteriorly, the metotic cartilage gives rise to a crest which runs along the outer side of the canalicular part of the capsule, and against which the otic process (*o.p.*) of the quadrate abuts.

In the visceral arches, the chief difference is the great elongation of the ceratobranchial and epibranchial cartilages of the first branchial arch, and the fusion of the ceratohyal cartilages to form the median unpaired entoglossal cartilage (*e.c.*), which has also greatly increased in length. (The entoglossal cartilage is the structure which KALLIUS (1905) regards as a paraglossal cartilage, the entoglossal according to him being represented by the anterior part of the copula.)

On each side of the posterior process of the copula and near its hind end there are now to be seen a pair of cartilages (*g.c.*) which embrace the aperture of the glottis.

They lie at a more dorsal level than the copula and appear to be the rudiments of the cricoid cartilages; possibly they represent the cartilaginous elements of the 2nd branchial arch, hitherto not found in birds.

Stage 14. 17 days; fig. 15; and figs. 67-70, Plate 51.—It is not proposed to give a complete account of the chondrocranium at this stage, for it shows no important differences as compared with the last, except that the nasal capsule is now completely chondrified.

The backgrowing roof (*b.r.*) formed by the parietotectal cartilages (*pt.c.*), the plana antorbitalia (*p.an.*), the conchæ nasales (*c.n.*), and the maxillo-turbinals (*m.t.*) are as in the previous stage, except that the maxillo-turbinal scrolls are still further wound, and now present a complete turn and a half. The chief advance is in the chondrification of the anterior region of the capsule, involving the formation of a cupula anterior (*cu.*) on each side, bounding the fenestra narina from in front, and of the atrio-turbinals (*at.t.*). The latter are plates of cartilage descending from the roof of the capsule and forming longitudinal curtains; their hinder extremity overlaps and is lateral to the anterior extremity of the maxillo-turbinals. It is noticeable that the floor of the capsule is practically absent. On a level with the hind end of the atrio-turbinals, a small pair of processes (*s.a.*) are to be seen jutting out to each side

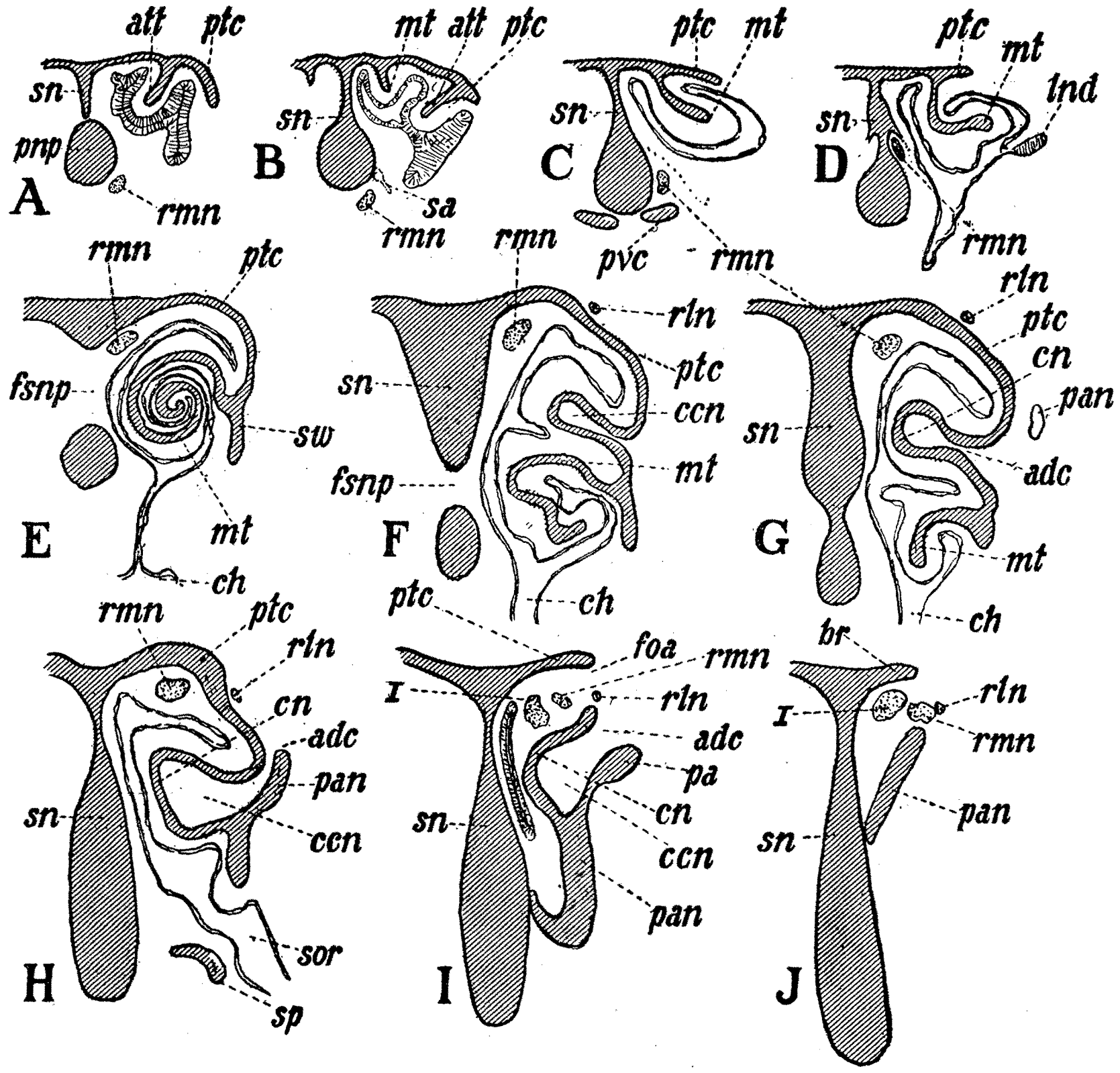

FIG. 15.—Series of transverse sections through the nasal capsule at successive posterior levels, at 17-day stage.

from the nasal septum near its ventral edge. These processes curve forwards and are joined by a strand of dense mesenchymatous tissue with the lowermost and hindmost point of the cupula anterior of their own side, thus forming a very rudimentary floor to this region of the capsule.

The side wall of the capsule is also very incomplete in the anterior and middle regions ; but in the hinder region, the free ventral edge of the side wall (parietotectal cartilage) now extends down laterally to, and further ventrally than, the maxillo-turbinals.

In order to assist in comprehending the somewhat complicated relations of the nasal capsule, and to serve as material for comparison with other forms, a set of selected transverse sections is appended, fig. 15, taken through progressively posterior levels of the capsule, and arranged in order. One of the most striking objects seen in any such section in the duck is the relatively enormous size of the ramus medialis nasi (*r.m.n.*), which is of course related to the development of the large flat bill with its extensive sensory surface. This nerve passes backwards beneath the rudimentary processes representing the floor, and then, as it reaches more dorsal levels at the side of the nasal septum, it is covered over by a ridge of cartilage (*r.*). This ridge, the development of which is much accentuated at successive stages, must be regarded as forming part of the morphological floor of the capsule, and is, indeed, connected with the cartilaginous process mentioned above by means of dense mesenchyme. It seems that the relations of the various structures in this region have been distorted by the outgrowth of the prenasal process (*pn.p.*). This process arises, not from the anterior end of the nasal capsule, but from its ventral surface, some little distance behind its anterior end. Strictly speaking, the structure which forms the ventral border to the foramina in the nasal septum (*f.s.n.a.*, *f.s.n.p.*) and which is regarded as the ventral part of the nasal septum itself, should be regarded as the base of the prenasal process. Consequently, as it extends forwards, this basal portion of the prenasal process is morphologically ventral to the floor of the anterior part of the nasal capsule, represented by the ridge above-mentioned, and the small cartilaginous processes.

The atrio-turbinals and maxillo-turbinals are clothed with folds of epithelium of the nasal sac, as is the inner surface of the concha nasalis. The aperture of the lachrymo-nasal duct (*l.n.d.*) and the choana (*ch.*) are situated ventrally to the maxillo-turbinal, and between the posterior extension of the latter (which forms the posterior floor) and the concha nasalis, an interruption (*a.s.o.r.*) in the side wall serves for the egress of the orbital sinus from the main cavity of the nasal sac. The concha nasalis is occupied only by mesenchyme.

Owing to the breaking down of the sphenethmoid commissure, the orbitonasal fissure is only virtual at this stage, and the ramus lateralis nasi (*r.l.n.*) does not enter the cavity of the nasal capsule, but, immediately after parting company with the ramus medialis nasi which enters the foramen olfactorium advehens (*f.o.a.*), the ramus lateralis nasi runs forward by the side of the parietotectal cartilage, immediately above the mouth or aditus of the concha nasalis (*a.d.c.*).

Altogether, the nasal capsule in the duck shows signs of reduction as compared with that of reptiles, and, in particular, it presents the appearance of having been squashed from behind, as if the planum antorbitale, itself displaced forwards by the huge eye, had therefore ceased to form the dome-shaped cupula posterior which is characteristic of the hinder region of the nasal capsule in reptiles and in mammals. Further consideration of this and related matters is reserved for the discussion.

B.—Discussion and Morphological Considerations.

1. *The present position with regard to the Segmental Theory of the Head.*—We may now attempt to correlate the conditions in birds with those in other forms, as regards the segmentation of the head and the position of the occipital arch.

We are not here concerned with the fate of, or the problems connected with, the prootic somites; suffice it to say that in no form yet investigated has any evidence been put forward to show that their number is other than 3. It is among the metotic somites included in the region of the head that variation is found. As might be expected, the least modified conditions are to be found in the Cyclostomes (KOLTZOFF, 1901) where the series of prootic and metotic somites are uninterrupted and complete, where no somites disappear, and where the total number of segments included in the head is 4.

In the remaining vertebrates, one or two, but never more, of the metotic somites disappear. In Selachians, the results of several workers (BALFOUR, 1876, VAN WIJHE, 1882, GOODRICH, 1918, DE BEER, 1922) have established that at a given moment the series of prootic and metotic somites is uninterrupted and complete, as in Cyclostomes, but that two somites, the 4th and 5th of the whole series, disappear. The total number of segments included in the head varies from 7 or 8 in Scyllium (GOODRICH, 1918), to 9 in Squalus (DE BEER, 1922), or 10 in Spinax (BRAUS, 1899).

Among vertebrates above Selachians, the problem is rendered more difficult by the fact that the series of prootic and metotic somites are interrupted, more or less. Nevertheless, it would seem that the total number of segments included in the head in Amia and Lepidosteus is 10 (SCHREINER, 1902), in Salmo 6 (HARRISON, 1895), while the results concerning Dipnoi are too conflicting to enable definite conclusions to be drawn.

In Amphibia, the Urodeles, represented by the axolotl, have been subjected to detailed study by GOODRICH (1911) who finds the total number of segments included in the skull to be 6. In Anura (represented by Alytes), the number is 5 (VAN SETERS, 1922).

Turning now to Amniota the constitution of the metotic region of the mammalian head has recently been studied by BUTCHER (1929), who describes three occipital myomeres, and states that the works of CHIARUGI (1890) on the rabbit, FRORIEP (1886) on the cow, and MALL (1897) on man, confirm this assertion. According to this view, there are four occipital somites of which the first disappears. But the results of other recent workers suggest, however, that these observations are incomplete. Thus, MUGGIA (1931) describes a human embryo of 5 mm. *c.r.* length with four occipital myomeres, each of which possesses a ventral root, while DAWES (1930) describes in the mouse five rudimentary occipital somites, of which the most posterior one is almost typically developed, the remainder each having a very small dermatomyotome and a very loosely arranged sclerotome. The latter results are curious because it seems to be the rule judging by all other forms above the Cyclostomes, that the first metotic somite never gives rise to a myomere. It is possible, however, that the earliest stage studied by DAWES may not have revealed the transitory first metotic somite described by BUTCHER ; if this is so, then the mammal could be regarded as resembling the bird in possessing 6 metotic somites. But a consideration of the occipito-atlantic joint in the different amniotes (see next sections) will show that there is no justification for the assumption of any detailed resemblance between birds and mammals in this region ; and in particular, since the joint appears to be intrasegmental in birds while it is intersegmental in mammals, the total number of segments included in the head of the latter would be 9, as against $9\frac{1}{2}$ in birds.

2. *The Segmentation of the Basis Cranii.*—The indications of segmentation in the skeletal elements of the basis cranii have been touched upon by various authors. FRORIEP (1886) described in the chick two occipital vertebræ which later became assimilated in the skull, but, as SONIES (1907) points out, he only described these in the form of sclerotomes, and did not further distinguish them in subsequent stages of chondrification. As we have seen in an earlier part of this paper, there is good evidence for the existence of true occipital vertebræ, as distinct from sclerotomes, in the posterior region of the bird's skull.

FRORIEP (1886) and SUSCHKIN (1899) refer to the existence of vestigial ribs in the occipital region of the skull of the bird. SUSCHKIN describes them as being of the same character as the anterior cervical ribs, although less dense. SONIES (1907), on the other hand, denies that these are ribs, pointing out that they do not chondrify. It is difficult to see how this objection could destroy the morphological validity of the comparison, and, moreover, it is certain that in the duck the two posterior pairs of ribs, at least, develop intercellular substance, as we have shown, fig. 10. It may therefore be concluded that the bird's skull possesses 4 pairs of ribs, and it is probable that they bear some relation to the metotic cartilage. These ribs being formed in connexion with the hypocentral elements, it follows that they correspond to the posterior sclerotomites of segments 6, 7, 8, and 9 of the entire series.

Evidence of segmentation may also be obtained from the foramina for the hypoglossal nerve-roots, of which, as we have seen, the skull of the duck has, at one time, five pairs. The cartilages separating the foramina of one side have the morphological value of occipital arches, of which there are therefore also five (the anterior border of the foremost foramen is presumably not an arch, but merely the cartilage of the basal plate), corresponding to segments 5 to 9 of the whole series, the last or 9th being the definitive occipital arch.

It is interesting to note, not only that the skull of the bird presents evidence of metameric segmentation in the basal region of its skull from the 5th segment to the 9th segment, but also that there is no evidence of segmentation anterior to the 5th segment. This falls curiously well into line with the evidence derived from other investigations. In Scyllium, for instance, there are on each side three occipital arches, of which the foremost corresponds to the 5th segment (GOODRICH, 1918; DE BEER, 1931, *a*). Similarly, the preoccipital arch of Urodeles (GOODRICH, 1911) and the (single) occipital arch of Anura (VAN SETERS, 1922) is situated in segment 5.

The relations of the occipital arches, their alternation with nerve-roots, and the presence of ribs in some forms, suggests the possibility that occipital arches were originally the neural arches of separate vertebræ now assimilated in the basal plate of the skull, as is known to occur with regard to the two hindmost pairs of occipital arches in birds. If this were so, then it follows that the vertebrate body originally possessed vertebræ from segment 5 backwards, but no vertebræ anterior to segment 5. In this connexion, attention may be called to three points, all of which provide evidence for the view that segment 5 represents a transitional region between an anterior non-vertebral part and a posterior vertebral part of the skull.

First, there is the well-known fact that in Cyclostomes, the skull occupies 4 segments only, and the vertebræ are only incipient. Were they to condrify as proper vertebræ, the foremost one would be in segment 5. Next, there is the fact that in the development of the skull in Selachians, the notochordal sheath is invaded by the cartilage cells of the parachordal from its hinder edge to a point opposite the middle of the auditory capsules (VAN WIJHE, 1922; DE BEER, 1931, *a*). Invasion of the sheath of the notochord is a typical vertebral phenomenon, and that it should not occur in the anterior region of the basal plate is evidence of the non-vertebral nature of this region. Lastly, there is the fact that in almost all vertebrates (Anura and Dipnoi are the only exceptions) a basicranial fenestra is present, *i.e.*, the anterior portions of the parachordals are entirely free from the notochord, and separated from it by a more or less wide space, which again is totally different from the conditions of formation of vertebral centra. It is difficult to estimate the extent of the region occupied by the basicranial fenestra, or in which in Selachians the notochordal sheath is not invaded, but it would not be extravagant to assume that it corresponds to the first 4 segments.

The conclusion which we have reached is of interest from the historical as well as from the theoretical point of view. When HUXLEY (1858) annihilated GOETHE's and OKEN's vertebral theory of the skull, he demonstrated the futility of attempting to interpret the bony skull in terms of modified vertebræ, and the vertebral theory was replaced by the segmental theory. But since it is clear that true vertebræ can and do become incorporated in the hinder part of the skull, the minor question arises as to how much of the hinder region of the skull represents originally separate vertebræ.

This question was raised by GEGENBAUR (1872), who thought he could distinguish a vertebral region behind from a prevertebral region in front. It would seem from the present state of knowledge that the extent of the prevertebral region may be put down as 4 segments, while that of the vertebral region varies from 0 (Cyclostomes) to 1 (Anura), 2 (Urodeles), 3 or 4 (Scyllium), 5 (Squalus, probably mammals), $5\frac{1}{2}$(birds), or 6 (Spinax).

Before concluding this section of the discussion, attention may be drawn to the opinion recently expressed by DAWES (1930) and MACBRIDE (1932) to the effect that it is the number of vertebræ included in the skull that forms the great difference between Amphibia and Amniota, and that it is the cranial flexure of the embryo in the latter which is responsible for the incorporation in their skull of a larger number of vertebræ. Whether this be so or not, it must be remembered that a cranial flexure also occurs in non-Amniote animals such as Selachians, and that in several fish (Spinax, Acipenser, Amia), the number of segments in the skull may equal or even exceed that characteristic of Amniotes.

3. *The Occipito-Atlantic Joint in Amniotes.*—In the birds, the hind end of the basis cranii is formed from two fused vertebræ, and the joint between the basis cranii and the vertebral column is therefore intervertebral. It is important to realize that the hypocentrum of the 2nd occipital vertebra (which, as we shall see, is also called the proatlas vertebra) is situated some distance in front of the hindmost edge of the basis cranii, and that the (definitive) occipital arch arises in a corresponding position. This indicates that the hindmost portion of the basis cranii represents the pleurocentrum of the 2nd occipital or proatlas vertebra, which is derived, at least in part (PIIPER, 1928), from the anterior sclerotomite of the segment which gives the first trunk myomere—the 7th metotic or 10th segment of the whole series. The occipital condyle arises from the posterior edge of the basis cranii in this region.

Since the ring of the atlas vertebra (neural arches and hypocentral element, or hypochordale Spange) is derived from the posterior sclerotomite of the segment which contributes the first trunk myomere, and the anterior sclerotomite of which, as just seen, furnishes the hindmost part of the basis cranii together with the occipital condyle, it is clear that all the skeletal elements of this region are accounted for, with the exception of the interdorsal element of the 10th segment, which does not here appear to contribute to the occipital arch. The occipito-atlantic joint in birds is thus to be regarded as intervertebral and therefore intrasegmental.

A similar interpretation was arrived at by HAYEK (1923), who, as a result of a study of this particular problem throughout the Amniotes, was able to present an interesting comparison of the conditions obtaining in the different groups, and, to show that the mammalian joint differs fundamentally from that of birds. We have examined our material, in the form of VAN WIJHE preparations of the skull in the rabbit, the duck, and the lizard, together with serial sections of these forms and of the crocodile, and are in a position to confirm HAYEK's conclusions.

In the occipital region of the sheep (Froriep, 1883), four "vertebral equivalents" have been described, of which only the hindmost one develops as an independent vertebra ("occipital vertebra") which soon becomes fused with the more anterior apparently unsegmented portion. In the mouse (Dawes, 1930), the fusion of the parachordal part of the whole occipital region takes place before chondrification, so that the "occipital vertebra" seems to lose its distinctness earlier than in the sheep. An occipital vertebra which subsequently becomes fused with the parachordal has been found in man and Bos (Muggia, 1931).

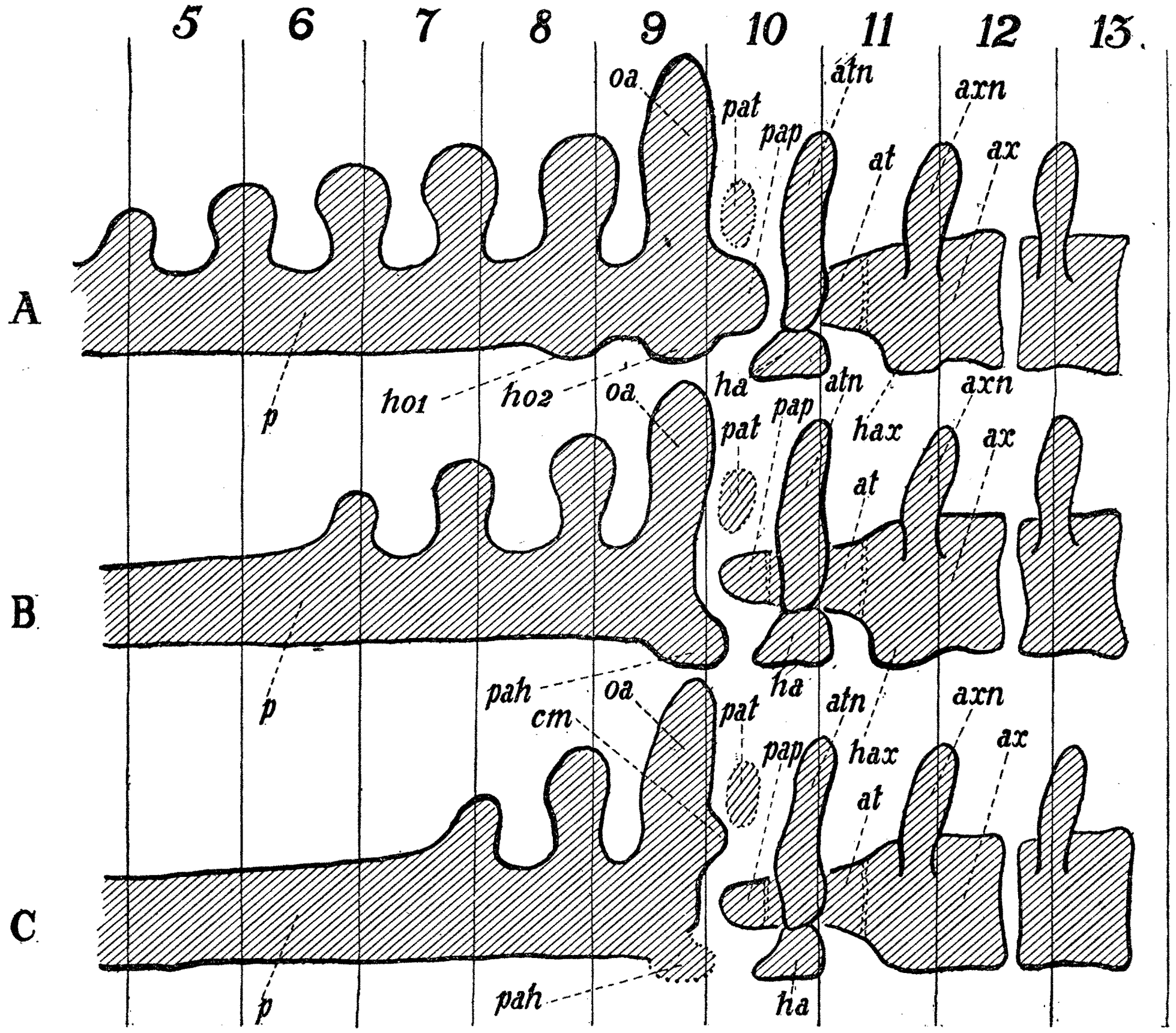

Fig. 16.—Diagrammatic reconstructions, seen from the left side, of the posterior region of the skull, occipito-atlantic joint, and anterior cervical vertebræ, of A. Chelonia, Crocodilia, and Aves. B. Sphenodon and Squamata. C. Mammalia.

It seems, however, that the hindmost portion of the basis cranii in mammals is formed from the posterior sclerotomite of the 6th metotic segment and that the anterior sclerotomite of the 7th segment (the pleurocentral element of the proatlas vertebra) does not become attached to the basis cranii in front of it (as in birds) but to the tip of the odontoid peg behind it. This has been observed in the rat (Weiss, 1901), in Echidna (Gaupp, 1908, *a*, *b*), and in Bradypus (de Burlet, 1913). In other words, in the mammals, the odontoid peg consists of the bodies or pleurocentral elements of both atlas and proatlas vertebræ, and the occipito-atlantic joint is intravertebral, and therefore intersegmental. As for the hypocentral element of the proatlas vertebra, it seems to disappear in all mammals except Echidna (GAUPP, *loc. cit.*), and this is of the greatest interest, for the skull of Echidna is really monocondylar, and resembles that of Squamata in this respect.

An examination of VAN WIJHE preparations brings out clearly the essential differences between the two fundamentally different types of joint as found in mammals and birds, in particular as regards the fates of the hypocentral and pleurocentral elements of the proatlas vertebra. The paired occipital condyles of the mammal arise from the base of the occipital arches, and at the place where in the bird the single condyle is developed, there is in the mammal a deep notch (the incisura intercondyloidea of some authors).

Turning now to the condition of the occipito-atlantic joint in reptiles, one of the most interesting facts elucidated by HAYEK (1924) is that the crocodiles and Chelonians resemble the birds in including the hypocentral and pleurocentral elements of the proatlas vertebra in the basal plate, having an odontoid peg consisting of the pleurocentrum of the atlas vertebra only, and having an intervertebral intrasegmental joint; while Sphenodon (SCHAUINSLAND, 1900) and Squamata (HAYEK, 1924) resemble mammals in including the pleurocentral element of the proatlas vertebra in the odontoid peg, and having an intravertebral intersegmental joint. The hypocentral element of the proatlas vertebra in Sphenodon and Squamata becomes attached to the hind part of the basis cranii, and contributes to the formation of the single median occipital condyle (as presumably in Echidna).

It follows, therefore, that the condyle in Sphenodon and Squamata is different from the similarly named structure in crocodiles, Chelonia, and birds.

An attempt to depict these rather complicated relations in simple diagrammatic form has been made in fig. 16. For the Squamata type it has been assumed that the number of segments included in the head is the same as in mammals, viz., 9. It will also be clear from the diagram why the number of segments in the skull of the birds is reckoned as $9\frac{1}{2}$.

The problem of the occipito-atlantic joint is confused by the presence in some forms of a so-called " proatlas arch " (ALBRECHT, 1880). Such an arch is present in all three of the groups of animals discussed; in the crocodile, in Sphenodon, and in Erinaceus. The most plausible interpretation of this structure is that of BARGE (1917), according to whom it represents an arch-like chondrification arising in the anterior sclerotomite of the segment, of which the posterior sclerotomite gives rise to the neural arch and ring (hypocentrum) of the atlas vertebra. The " proatlas arch " therefore seems to be an isolated interdorsal arch, formed from the same sclerotomite as the pleurocentrum of the proatlas vertebra, and which has failed to become attached to the posterior surface of the occipital arch. Now, an interdorsal element appears to contribute to the posterior part and postzygapophyses of the neural arches of the vertebræ in many Tetrapods (FORTMAN, 1918; PIIPER, 1928; GOODRICH, 1930, p. 61). The "proatlas arch" must not therefore be confused with the entire neural arch of the proatlas vertebra; the latter (see HAYEK, 1923) is simply the vertebra next immediately in front of the atlas vertebra, consisting of hypocentral, pleurocentral, and neural arch elements, including the interdorsal or "proatlas arch." The elements of the proatlas vertebra, as we have seen, however, do not always become joined up in the manner of a typical vertebra; they do in crocodiles, Chelonia, and birds, thus giving rise to the 2nd occipital vertebra found in birds; but they remain separated in Sphenodon, Squamata, and mammals. As an additional variation, then, we may occasionally find the separate chondrification of the posterior (interdorsal) part of the neural arch of the proatlas vertebra (occipital arch) to give the "proatlas arch." Since the term proatlas vertebra is very useful to denote those elements in front of the atlas, but which are not always included in the occipital region of the skull, its retention is desirable and confusion would be avoided if the "proatlas arch" were referred to more specifically as the proatlas interdorsal arch.*

4. *The Nasal Capsule.*—W. K. PARKER (1866, 1869, 1876) recognized three turbinals in the nasal capsule of birds which he named "naso-turbinal," "inferior turbinal," and "upper turbinal" ("Bagged condition of the aliethmoidal wall"). But he also observed a small "middle turbinal" on the inner side of the root of the inferior turbinal in ostriches.

GEGENBAUR (1873) also distinguished three turbinals, which he called "anterior turbinal" or "inferior turbinal," "middle turbinal," and "posterior turbinal" or "superior turbinal" (also called "Riechhügel"). It is already clear that the expressions "middle turbinal" and "inferior turbinal" are being used in different senses by PARKER and GEGENBAUR.

BORN (1879) recognized a "primary turbinal" (middle turbinal), a "secondary turbinal" (upper turbinal), and a "vestibular turbinal" (nasoturbinal of PARKER, anterior turbinal of GEGENBAUR). T. J. PARKER (1892) working on Apteryx described an "anterior turbinal," an "anterior accessory turbinal," a "ventral accessory turbinal," a "middle turbinal," and a "posterior turbinal." SUSCHKIN (1899) speaks, in Tinnunculus, of a "vestibular turbinal," and a "middle turbinal," of which the "upper turbinal" is a part. SONIES (1907) did not follow the development long enough to see the chondrification of the anterior region of the nasal capsule, and speaks only of a "concha superior" and a "concha inferior."

---

* Reference may be made to a recent brief communication by MOOKERJEE (1931, *b*) in which the author puts forward an entirely novel interpretation of the occipito-atlantic joint, according to which the atlas ring is completed ventrally, not by the hypocentrum of the atlas, but by the posterior part of an "intercalated arch," the hypocentrum of the atlas (in reptiles and birds) fusing with the odontoid peg. While it is necessary to await the detailed publication of these results before their significance can be appraised, it may be said that the present work offers no justification for the view that the ventral element of the atlas ring is anything other than the hypocentrum of that vertebra, developed from the posterior sclerotomite of the first trunk segment; nor does such a suggestion seem to have been entertained by any other investigator.

The first point which emerges from this rapid survey of previous work is the inadvisability of using comparative topographical terms, such as "upper," "middle," "anterior," to denote structures which in different forms may have topographically different positions while retaining their essential morphological relations. For this reason we have preferred to speak of an atrio-turbinal, a maxillo-turbinal, and a concha nasalis. Our first task is, therefore, to equate them with the terminology of previous authors, and, by means of comparisons with reptiles and mammals, to attempt to defend their selection.

W. K. PARKER.	GEGENBAUR.	BORN.	T. J. PARKER.	SUSCHKIN.	This paper.
Naso-turbinal	Anterior turbinal	Vestibular turbinal	Anterior, anterior accessory, and ventral accessory turbinal	Vestibular turbinal	Atrio-turbinal.
Inferior turbinal	Middle turbinal	Primary turbinal	Middle turbinal	Middle turbinal	Maxillo-turbinal.
Superior turbinal	Posterior turbinal	Secondary turbinal	Posterior turbinal	(Upper turbinal)	Concha nasalis.

Previous workers who have considered the problem of the homology of the turbinals in birds and other amniotes (GEGENBAUR, BORN) have regarded the middle turbinal of GEGENBAUR (our maxillo-turbinal) as homologous with the concha nasalis which is found in lizards, snakes, tortoises, and crocodiles. The crocodile, however, possesses more than one turbinal. W. K. PARKER (1883) speaks of an upper turbinal and a lower turbinal, while MEEK (1911) in his careful and accurate study distinguishes three: an anterior turbinal which he thinks is the mammalian maxillo-turbinal; a middle turbinal (the concha nasalis) which he thinks is the mammalian naso-turbinal; and a posterior turbinal (the pseudo-concha of GEGENBAUR), which he regards as the mammalian ethmo-turbinal. SHIINO (1914) prefers to regard MEEK'S anterior turbinal as the atrio-turbinal of mammals and the vestibular turbinal of birds.

It seems to us, however, that the nasal capsule of the bird is to be interpreted on the view that the inwardly directed bulge, here called concha nasalis and arising from the paranasal cartilage, is the representative of the concha nasalis of reptiles, and in support of this opinion we advance morphological as well as embryological evidence. It will be convenient to begin with the latter, fig. 17.

Recent investigations into the development of the nasal capsule of the lizard (DE BEER, 1930); the duck (SONIES, 1907, and this paper); and the rabbit (DE BEER and WOODGER, 1930), have shown that the parietotectal cartilage (*p.t.c.*), which forms the roof and side wall, the paranasal cartilage (*pn.c.*), and the planum antorbitale (*p.an.*)

take part in its formation. In lizard and rabbit, the planum antorbitale forms the cupula posterior of the capsule and is continuous with or overlapped by the hinder edge of the paranasal cartilage. In the duck, on the other hand, the planum antorbitale extends sideways beyond the hinder edge of the paranasal cartilage, and there is no cupula posterior. The point of junction between the paranasal cartilage and the parietotectal cartilage is marked in lizard and rabbit by the epiphanial foramen (*f.e.*), which is situated immediately above the aditus conchæ. In the duck there is no epiphanial foramen since the ramus lateralis nasi (*r.l.n.*) does not enter the nasal capsule; but an epiphanial foramen is present in the sparrow, and is situated immediately above the opening of the concha nasalis.

The concha nasalis (*c.n.*) of the lizard is formed at the place where the parietotectal and paranasal cartilages join, and this is the same in the duck, but here the whole paranasal cartilage appears to contribute to the formation of the concha, as if the wall in this region were crumpled by pressure from behind. Actually, there is reason to believe that such pressure, or rather competition for space, exists, and is due to the large size of the eye, which forces the planum antorbitale forward.

The embryological evidence is thus favourable to our view that the structure which we have called the concha nasalis in birds is the representative of the similarly named structure in reptiles. We may now turn to the morphological evidence, as revealed by a consideration of the fully developed chondrocrania of the lizard (Gaupp, 1900; de Beer, 1930), the crocodile (Meek, 1911; Shiino, 1914; and original investigations), the sparrow (original investigations), and the rabbit (Voit, 1909; de Beer and Woodger, 1930). Figs. 18 and 19 represent dorsal and left side views of the nasal capsule in these forms.

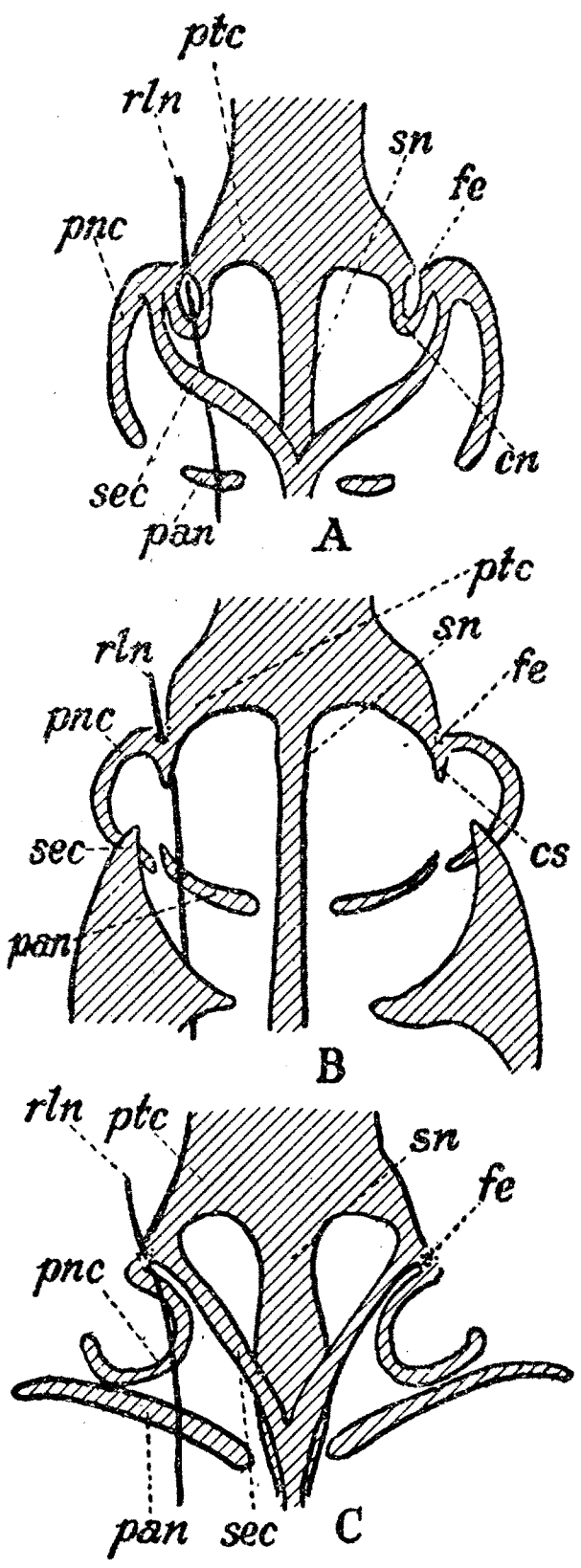

Fig. 17.—Dorsal views of early stages of development of the nasal capsule in A, Lizard; B, Rabbit; C, Duck.

The chief point emerging from such a comparison is the difference already alluded to in the part played by the planum antorbitale in the bird and in the other forms. It may also be noticed that in the crocodile, the ramus lateralis nasi does not pass through an epiphanial foramen, but that it would do so if the fusion between the parietotectal and paranasal cartilages were slightly more extensive. The relations of the nerve in the crocodile are really the same as in the lizard or the rabbit, and therefore the fact that there is no epiphanial foramen in the duck is no evidence against the view which we are here putting forward.

The lachrymo-nasal duct (*l.n.d.*) is seen to be of little value for purposes of comparison, for whereas its junction with the nasal sac takes place behind the zona annularis in the lizard, the crocodile and the duck, it takes place in front of the zona annularis in the rabbit. There is, here, therefore, a discrepancy which does not amount to much, and which places the mammal on a footing different from the others. But within the latter, the relations of the lachrymo-nasal duct to the concha nasalis present no obstacle to our view, and, indeed, for what it is worth, give support to it.

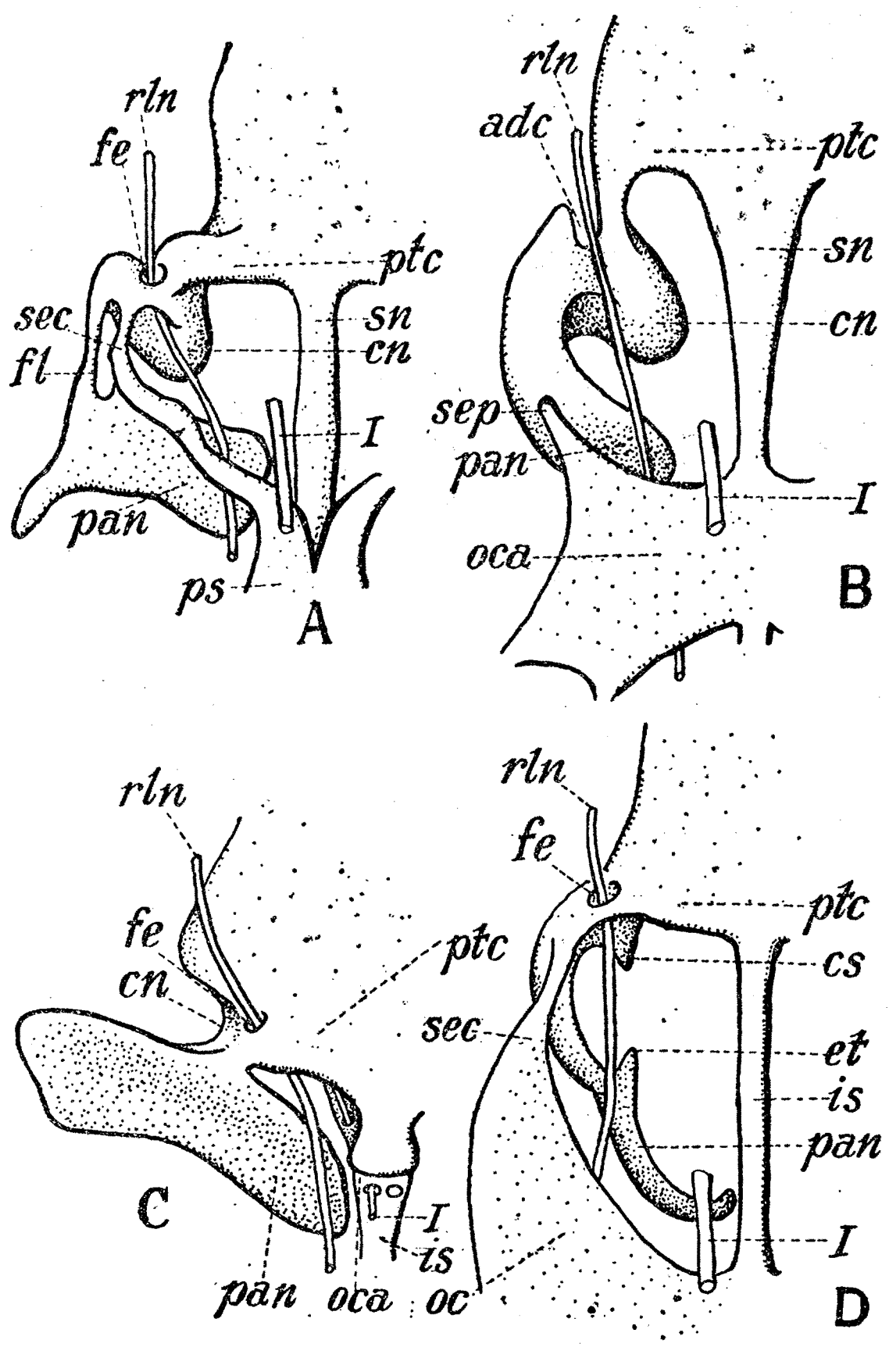

FIG. 18.—Dorsal views of left side of nasal capsule in A, Lizard; B, Crocodile; C, Sparrow; D, Rabbit. (A, partly after GAUPP; B, partly after SHIINO; C, original; D, after DE BEER and WOODGER.)

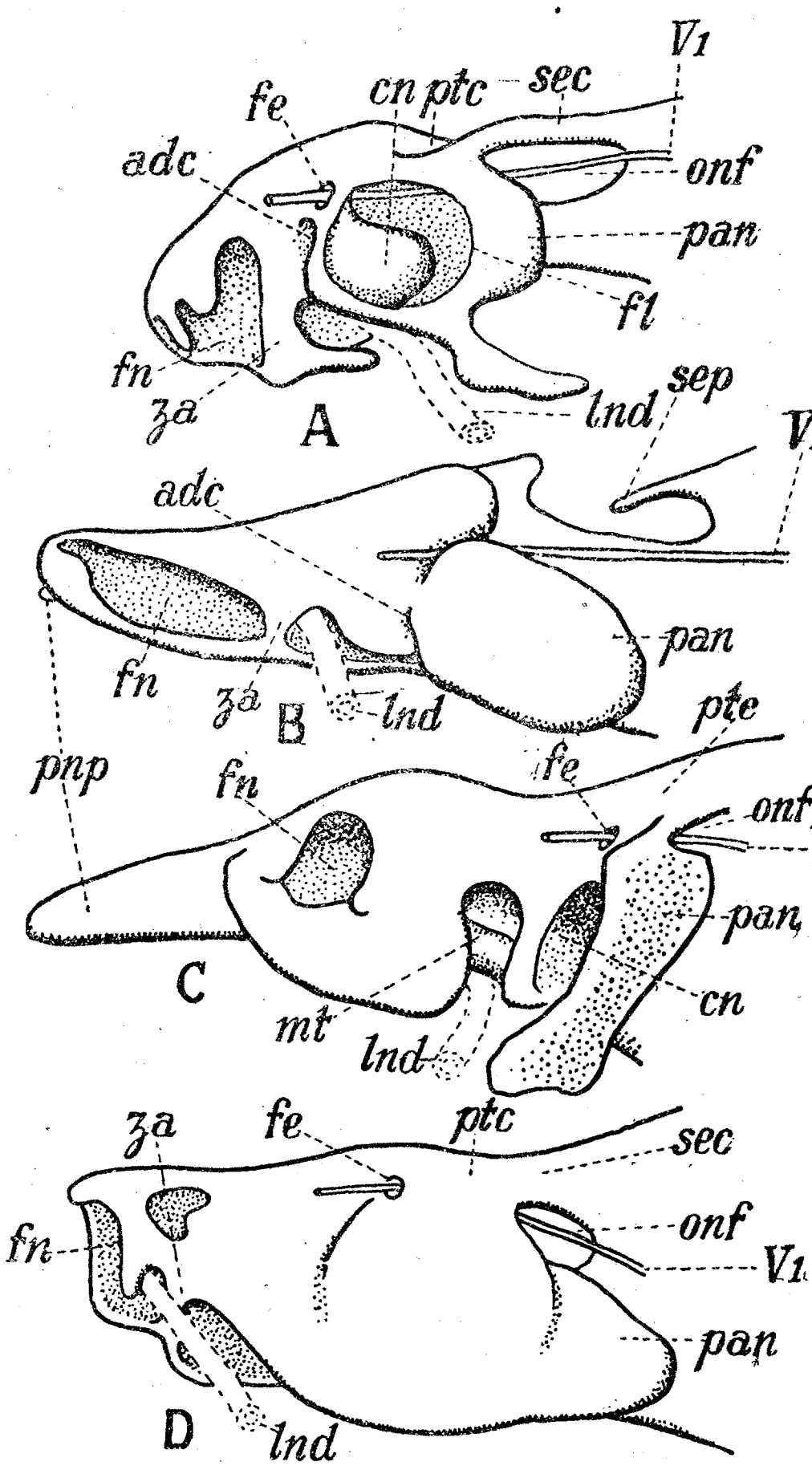

FIG. 19.—Left side views of nasal capsule in A, Lizard; B, Crocodile; C, Sparrow; D, Rabbit. (A, after GAUPP and DE BEER; B, partly after SHIINO; C, original; D, after VOIT, and DE BEER and WOODGER.)

(The peculiar course taken by the olfactory nerve in the sparrow will be the subject of comment in the next section.)

In order to make a complete comparison between the nasal capsules of the different forms, it is necessary to have recourse to transverse sections, of which a selected set is given in fig. 20, for comparison with fig. 15.

In the first place, it will be advantageous to consider the view held by GEGENBAUR and BORN that their middle turbinal of birds (our maxillo-turbinal) is the concha nasalis of the reptile. It is quite true that a section through the capsule of the lizard, such as that given in fig. 20, B 3, shows the wall of the concha nasalis (*c.n.*) curved in such a way as to resemble the maxillo-turbinal of the bird (*cf.* fig. 15, E, *m.t.*). But the concha nasalis of the reptile shows considerable variability, and the conditions in the Lacertilian Calotes, fig. 20, A 2, or in the crocodile, fig. 20, C 2 and 3, would not prompt the suggestion that it is homologous with the maxillo-turbinal of birds.

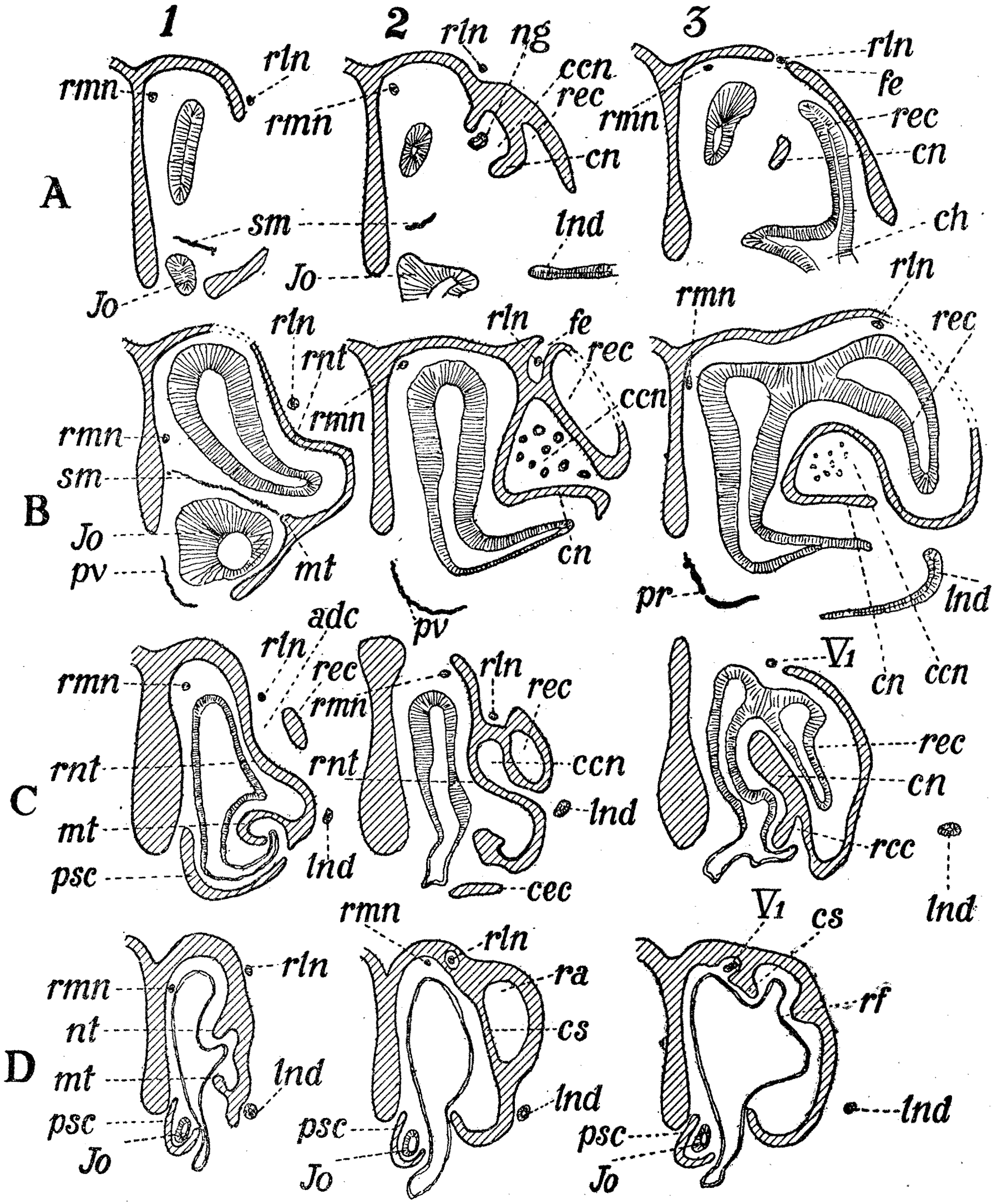

FIG. 20.—Transverse sections through selected successively posterior levels, 1, 2, 3, of nasal capsule in A, Calotes ; B, Lacerta ; C, Crocodilus ; D, Mus.

On the other hand, the crocodile shows, just anterior to its concha nasalis, a curved projection pointing inwards from the side wall, fig. 20, C 1, and which we have labelled maxillo-turbinal (*m.t.*). It is shown in GEGENBAUR's (1871) Plate I, fig. 6, labelled "*e.*" In the lizard, fig. 20, B 1, this structure appears to be related to the outer edge of the septomaxillary bone (*s.m.*), which is absent from the crocodile. In the mammal —mouse, fig. 20, D 1—the maxillo-turbinal is shown for comparison.

We may therefore conclude that the maxillo-turbinal of the bird is an extreme development by way of scroll-like rolling, of the structure present in the crocodile and which is also represented in the lizard and in the mammal.

Sectional views of the concha nasalis (*c.n.*) are also instructive, for a comparison between the structure to which we have given this name in the duck, fig. 15, F, G, H, I, and the concha in the lizard, fig. 20, B 2, 3, and in the crocodile, fig. 20, C 2, 3, shows that their relations are similar. We may also note with regard to the epiphanial foramen (*f.e.*) that Calotes presents a condition intermediate between that of the lizard and that of the crocodile or duck, for in Calotes the foramen is relatively far back; in fact, it is only just separated off from the foramen olfactorium advehens, and the ramus lateralis nasi (*r.l.n.*) makes its way forwards over the aditus conchæ (*a.d.c.*), already external to the wall of the capsule. The cavity of the concha nasalis (*cavum conchæ*) in the crocodile contains a diverticulum of the olfactory sac, but this fact is no objection to the homology of the crocodile's concha nasalis with that of the duck which contains no such diverticulum, for the concha of the lizard and of Calotes resembles that of the duck in this respect. Instead, the concha in the latter two forms contains the acini of the lateral nasal gland, and it is interesting to note that acini are found near the opening of the concha nasalis in the sparrow.

In the mammal, the concha nasalis appears to be represented by a solid structure, the crista semicircularis (*c.s.*), behind which the cavity of the nasal capsule extends sideways and forwards to form the recessus anterior (*r.a.*), which ends blindly in front, and thus corresponds to the recessus extraconchalis (*r.e.c.*) of the lizard and crocodile. In the bird, if our comparisons are just, there should be no recessus extraconchalis, for the planum antorbitale presses close up against the hind surface of the concha nasalis, and there is no room; this, in fact, appears to be so.

Turning now to the structure which we have termed atrio-turbinal in the bird, it is at any rate clear that it cannot represent the naso-turbinal of the mammal, for the latter is dorsal and morphologically median to the maxillo-turbinal, whereas the atrio-turbinal of the bird is lateral to the maxillo-turbinal, fig. 15, B. By exclusion, therefore, the structure which we have called atrio-turbinal in the bird would seem to correspond in position to the atrio-turbinal in the mammal, of which rudiments may perhaps be recognized in the bulges formed by the inner wall of the cavum conchæ nasalis. We have no desire, however, to imply a strict and formal homology between these structures in the bird and mammal, and we have chosen these terms because of the necessity for avoiding such relative terms as "anterior," or "middle," and because the structures denominated by them seem to represent corresponding elements of the nasal capsule.

Applying these terms to the crocodile, we would therefore agree with SHIINO (1914) in regarding MEEK'S anterior turbinal as the atrio-turbinal; his middle turbinal as the concha nasalis; while his posterior turbinal may correspond to the mammalian ethmo-turbinal as MEEK (1911) suggests. Alternately, the posterior turbinal may be a structure peculiar to crocodiles and absent in birds owing to the crushing of the posterior region of the nasal capsule in these animals by the planum antorbitale.

5. *The Orbital Cartilage.*—The recognition of the existence in the bird of a preoptic root of the orbital cartilage, as described in this paper (SUSCHKIN'S root of the supraorbital plate; SONIES' lamina orbitonasalis), and the discovery of a stage at which the orbital cartilage is continuous from the sphenethmoid commissure to the pila antotica, puts the bird's chondrocranium completely into line with those of other vertebrates. SONIES was misled by the remarkable similarity between the skulls of birds and of dogfish (*cf.* fig. 42, Plate 47, of this paper with fig. 12, Plate 33, of DE BEER'S (1931, *a*) paper on the dogfish), for in both, a process projects sideways and upwards from the trabecula. In the dogfish, this is the lamina orbitonasalis, which lies laterally to the ramus lateralis nasi; the preoptic root of the orbital cartilage arises later (DE BEER, *loc. cit.*, fig. 14, Plate 34), and between it and the lamina orbitonasalis is the orbitonasal fissure through which the ramus lateralis nasi passes. In the bird, the order of appearance of these cartilages is exactly reversed; the preoptic root of the orbital cartilage appears first, and subsequently the planum antorbitale makes its appearance. The planum antorbitale is to be regarded as a lamina orbitonasalis that has chondrified separately from the trabecula. The preoptic root of the orbital cartilage, as part of the true cranial wall, is median to the ramus lateralis nasi, and this nerve is therefore the key to the distinction between the two structures.

In some vertebrates, the orbital cartilage has a separate and independent chondrification, and while this does not occur in the duck, it does in the gull, fig. 21, *o.c.* The great reduction to which the orbital cartilage is subjected in the bird is doubtless connected with the upgrowth of the interorbital septum and the size and space required for the eye-balls. The first effect of this is seen in the discontinuity between the anterior part of the orbital cartilage which remains attached to the interorbital septum and the posterior part which is continuous with the pila antotica, and its further effect is the reduction of the anterior orbital cartilage into the planum supraseptale. As a result of this reduction, the olfactory nerve ceases to have any cartilage between it and the orbit, through which it then runs. It is interesting to compare this state of affairs with that which prevails in certain fish such as Salmo. There (DE BEER, 1927), the olfactory nerve finds itself in the orbit, not as a result of any reduction in the orbital cartilage, but as a consequence of a relative forward displacement of the lamina orbitonasalis.

With regard to the reduction of the anterior orbital cartilage in the duck, our results are in complete agreement with those of SONIES (1907) as to fact; it is only with his interpretation of these results and with his application of the term lamina orbitonasalis to the preoptic root of the orbital cartilage that we are unable to agree. A somewhat similar reduction in the orbital cartilage, though rather difficult to follow, occurs according to SUSCHKIN'S (1899) descriptions in Tinnunculus. It is, however, by no means universal in birds, for the sparrow presents a very different state of affairs.

A search for the olfactory nerve in series of transverse sections of the sparrow revealed the extraordinary fact that the orbital cartilage (*o.c.*) in this region is not absorbed and lost, but is plastered against the interorbital septum (*i.s.*), and encloses the olfactory nerve (*I.*) in a small long canal. The olfactory nerve, here, then, does not traverse the orbit at all, but appears at first sight to run down through the thickness of the septum, and it is only careful observation which shows that the "septum" is really a composite structure in this region, formed by the true interorbital septum to which on each side the orbital cartilage is attached as a thin plate (see figs. 18 C and and 23, and fig. 76, Plate 52).

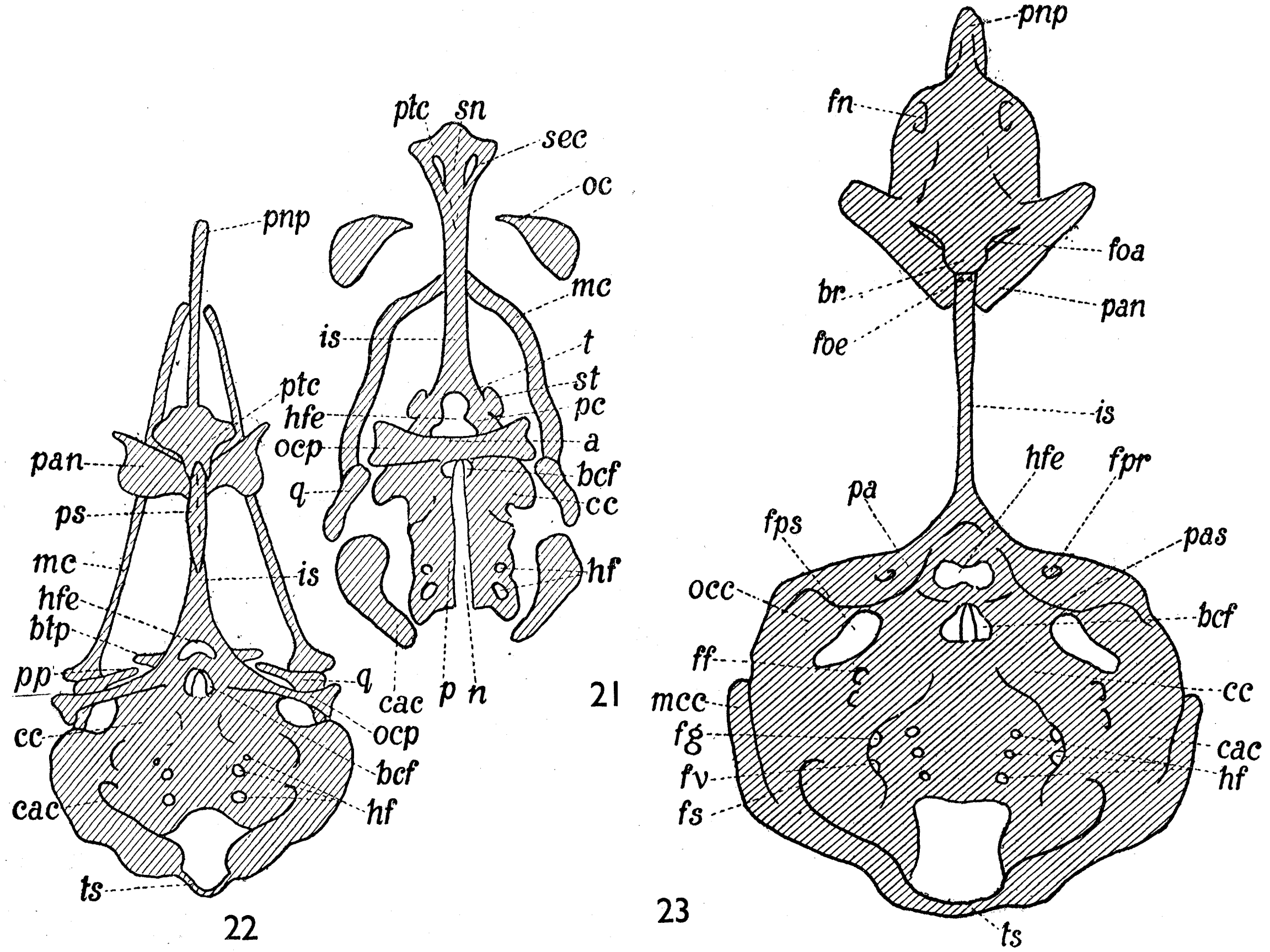

FIG. 21.—Dorsal view of the skull of an embryo of Larus sp., showing the separate origin of the orbital cartilage. FIG. 22.—Dorsal view of the skull of an embryo of Hirundo sp., showing the well-developed basitrabecular process. FIG. 23.—Dorsal view of a blotting-paper-wax model reconstruction of the skull of an embryo of Passer domesticus near full time.

6. *The Basitrabecular Process.*—The basitrabecular process, one of the most constant and widespread structures throughout the vertebrates, is a laterally-directed process of the polar cartilage which meets, fuses with, or is articulated with, the basal process of the pterygoquadrate. We have shown, figs. 38, 39, Plate 47, that at a certain early

stage in the duck, the polar cartilage and the pterygoid process of the quadrate are interconnected by a strand of dense tissue, with intercellular substance staining with victoria blue. This cannot represent anything other than a vestige of the original basal connexion. A connexion almost certainly similar was described by FILATOFF (1906) in the pigeon, but was held by him, on grounds which we believe to be untenable, to represent the ascending process.

The interest of this connexion between the polar cartilage and the pterygoquadrate lies in the fact that it enables us to identify the basitrabecular process, and to see that the infrapolar process is not simply a basitrabecular process directed backwards. The basitrabecular process as such is not further developed in the cartilaginous skull in the duck ; it is, however, very obvious in the swallow, fig. 22 (*b.t.p.*), and has been described by W. K. PARKER (1876), T. J. PARKER (1892), and SUSCHKIN (1899) in the forms studied by them.

The recognition of the fact that the infrapolar process is a different structure from the basitrabecular process solves a problem raised by a comparison between the crocodile and the bird (DE BEER, 1926, *b*). Infrapolar processes are also present in the crocodile, and the palatine nerves run on their median side, whereas they run on the lateral side of the infrapolar processes in birds. Since the infrapolar processes are free downgrowths from the polar cartilage, there is no reason why they should not grow inside the palatine nerves in one case and outside them in another. Further, it is to be noticed that in the crocodile the infrapolar processes do not fuse with the basal plate, but end freely, and it would therefore be possible for the palatine nerves to slip over their free ends and so assume a median position. The palatine nerves always run ventrally to the basitrabecular process.

7. *The Pila Antotica.*—In the fully-formed chondrocranium of the bird, *e.g.*, in the fowl (TONKOFF, 1900), the posterior orbital cartilage is attached to the basal plate by a cartilaginous pillar which passes between the profundus and the maxillary branches of the trigeminal nerve. This condition is explained by the fact that an additional support, the pila antotica spuria, is developed in this position. A complete series can thus be made out, fig. 24, from such a form as the crocodile, which possesses a pila antotica (*p.a.*), and no pila antotica spuria (*p.a.s.*) ; here, as always, all the branches of the trigeminal nerve pass out behind the pila antotica, fig. 24, A. At young stages, fig. 24, B, the duck is precisely similar to the crocodile, and the pila antotica is typical. Later, however, the pila antotica spuria is developed, fig. 24, C, and the profundus branch (*V* 1) now emerges through a separate foramen. The sparrow is in this condition, fig. 23. The next stage is represented by the fowl, fig. 24, D, where the pila antotica spuria alone remains, the pila antotica disappearing, with the result that the posterior orbital cartilage appears to be connected with the basal plate by a pila which is in the wrong position for a pila antotica.

This case is a good example of the value of morphological criteria. At first sight the condition in the fowl appears to be contrary to normal as regards the relations of the pila antotica. But by following the development of this region in the duck, it is seen that all the morphological relations between the various structures are scrupulously respected, and the conditions in the fowl are nothing but the result of the development of a new structure and the reduction of an old one.

It is interesting to compare the conditions of the orbito-temporal region of the chondrocranium in birds and in mammals. In both the large size of the brain and trigeminal ganglion necessitate the provision of more room in the cranial cavity than is present in lower forms such as the crocodile or lizard. But the way in which this has been achieved is totally different in the two groups. In mammals, as is well known, a primitively extracranial space, the cavum epiptericum, becomes incorporated within the cranial cavity by the disappearance in this region of the cartilaginous true side wall of the skull (the pila antotica or tænia clino-orbitalis) and the development of a structure belonging to the visceral skeleton, the ala temporalis, as part of the side wall of the definitive skull. In the bird, no extracranial space is incorporated, but the existing intracranial space is enlarged by extension to the side of the posterior orbital cartilage: it is this extension which for mechanical reasons requires the formation of the pila antotica spuria. Even then there is a gap in the chondrocranium between the lateral edge of the posterior orbital cartilage and the auditory capsule, and this is filled up in the bony skull by the squamosal.

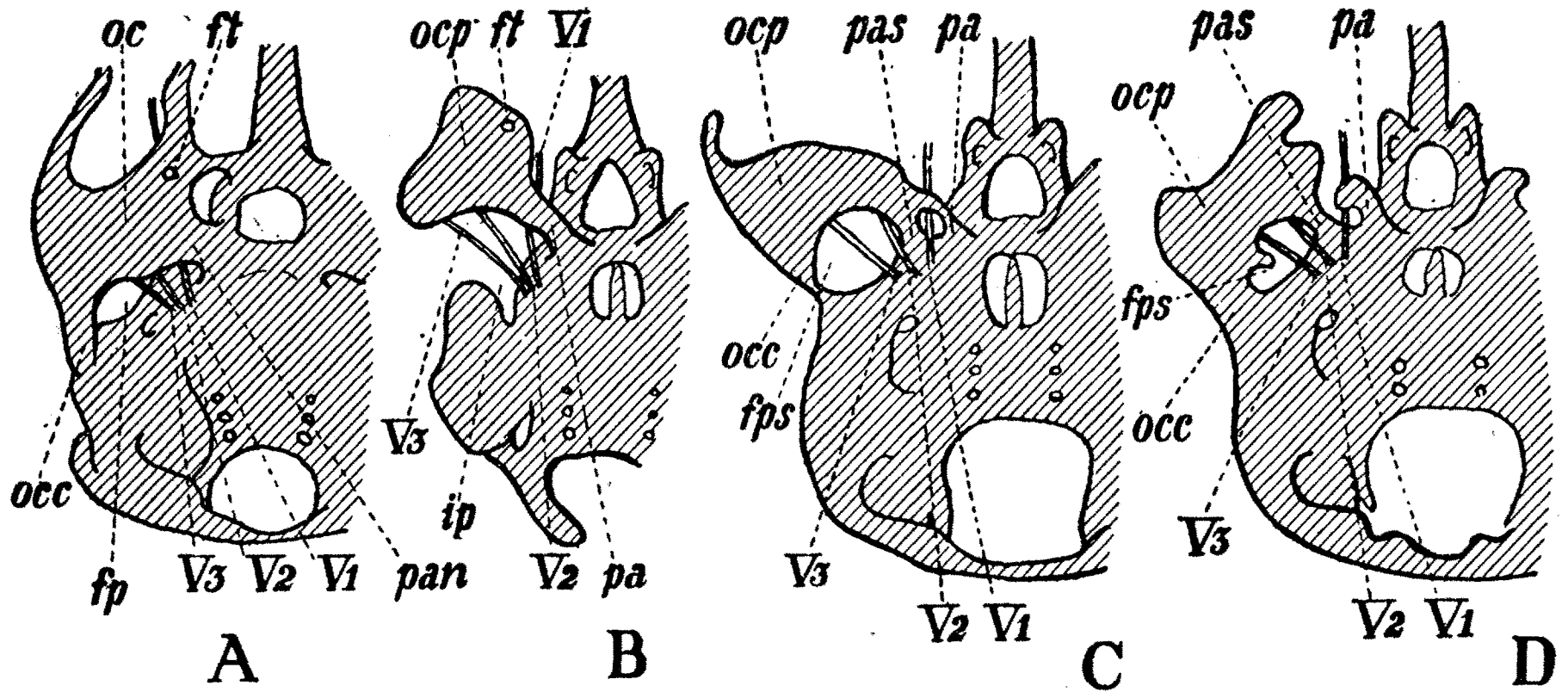

Fig. 24.—Dorsal views, showing the relations of the pila antotica, pila antotica spuria, and the various branches of the trigeminal nerve, in A, Crocodile; B, Duck, early stage; C, Duck, later stage; D, Fowl. (A, after Shiino; D, after Tonkoff.)

8. *The Metotic Cartilage.*—The skull of the bird is characterized by the development of a cartilage which becomes attached to the occipital arch, the side of the auditory capsule, and the lateral edge of the basal plate, in such a manner as to separate the glossopharyngeal and vagus nerves in two foramina (formed out of the originally extensive fissura metotica) and to provide a skeletal floor for the recessus scalæ tympani.

So far as the embryological evidence goes, the metotic cartilage appears to chondrify in relation to the cranial ribs, and is in all probability to be regarded as a modification of a number of cranial ribs. This conclusion is borne out by the morphological evidence, provided by a comparison between the chondrocrania of the crocodile and the bird The crocodile possesses a subcapsular process (Shiino, 1914) which extends forwards from the occipital arch beneath the auditory capsule, with which, however, it does not fuse, fig. 25 (*s.c.p.*). Were it to do so, the conditions in the bird would be automatically realized. There can therefore be no doubt that the metotic cartilage (*mc.c.*) is homologous with the subcapsular process, and the latter, in the crocodile, has all the appearances of being a cranial rib, attached to the occipital arch, just as in the rabbit the paracondylar process is so attached.

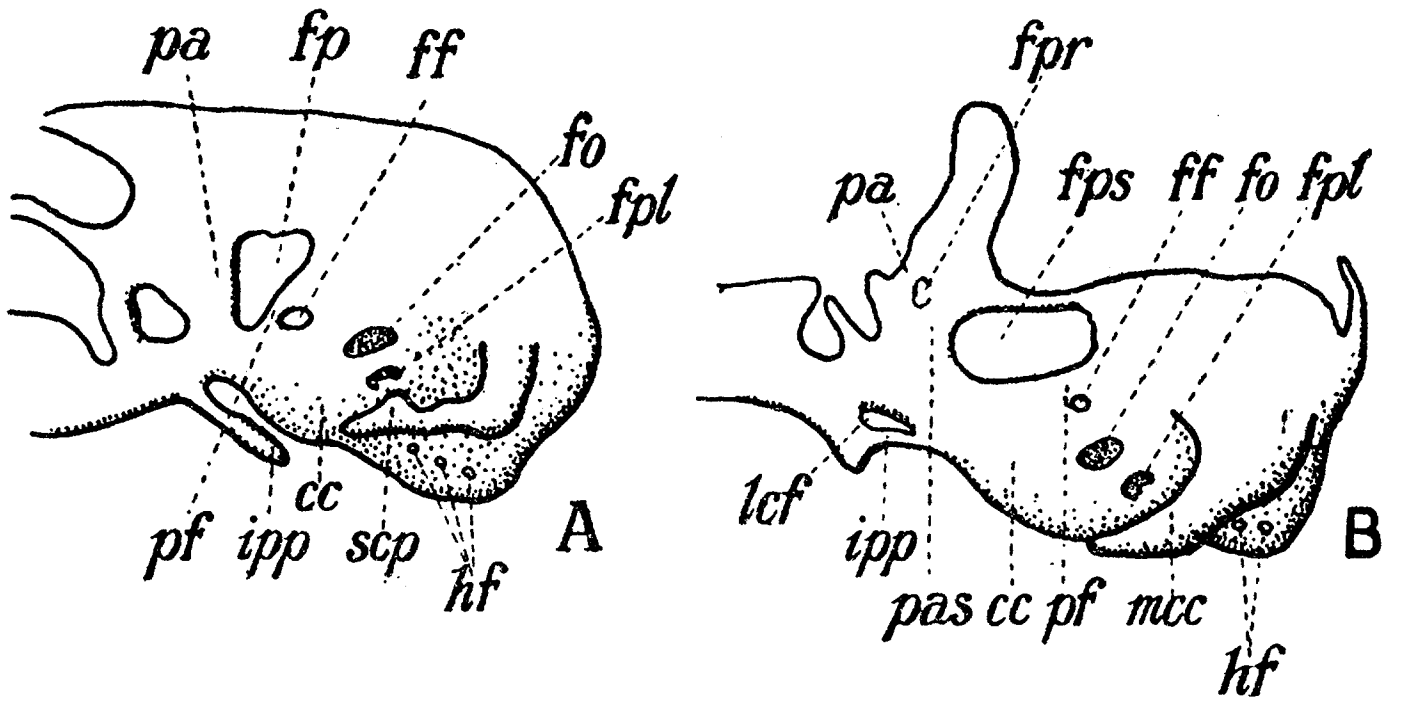

Fig. 25.—Left side views, showing the relations of the subcapsular process and metotic cartilage in, A, Crocodile ; and, B, Sparrow. (A, partly after Shiino.)

The metotic cartilage was first recognized as such by Sonies (1907), but there is no doubt that it is the same structure as that which T. J. Parker (1892) called the paroccipital process, and Suschkin (1899) the occipital wing.

With regard to the recessus scalæ tympani, it may be observed that here again the bird's skull presents a condition analogous to that of the mammal, obtained by other means. In the mammal (de Beer, 1929) the recessus becomes covered over by a backgrowth of the cartilage forming the floor of the cochlear part of the capsule; in the bird, a new element altogether, the metotic cartilage fulfils this function.

9. *The Parachordal and the Auditory Capsule.*—Gaupp (1906) was of the opinion that the cochlear part of the auditory capsule was formed from cartilage which originally belonged to the basal plate or parachordal, which had become modified and adapted to its new function. For the mammal (Noordenbos, 1905 ; de Beer, 1929), this view has been shown to be untenable, since a close study of the development in those forms shows that the cochlear capsule and the parachordal are independent from the start, and usually remain separated by a basicochlear fissure. Since a cochlear capsule is also present in the skull of the bird, it becomes of interest to examine it from this point of view.

In birds there is no basicochlear fissure, and from an early stage the cochlear capsule and the parachordal are in contact. But reference to the earliest stages, figs. 33, 34, Plate 47, shows that these elements are really independent, and that there is here, as in the mammal, no support for the view that the cochlear capsule is formed from parachordal (*i.e.*, axial) cartilage.

10. *The Visceral Arch Skeleton.*—The mandibular arch calls for no especial mention, except to repeat that at a certain stage the pterygoid process of the quadrate is connected to the polar cartilage by a strand of tissue, and that MECKEL's cartilage has two centres of chondrification (as in Squalus, VAN WIJHE, 1922). The hyoid arch is remarkable for its poor chondrification. Dorsally, the columella auris chondrifies quite independently of the auditory capsule (*contra* SUSCHKIN), and in procartilaginous connexion with the stylohyal cartilage. Subsequently, the stylohyal becomes connected with the columella auris by cartilage, and, later again, it becomes separated from it. The remainder of the skeleton of the hyoid arch is represented only by the pair of cartilages which arise fairly late, in front of the copula, and which are here (after SONIES) called the ceratohyals. They subsequently fuse to form the median entoglossal cartilage. KALLIUS (1905), however, as a result of his careful investigations into the development of the tongue, denies that these elements are the ceratohyals, for he finds in a procartilaginous condition in the duck another pair of processes, posterior to our ceratohyals, given off from the copula. He regards these latter processes as representing the ceratohyals, and considers the structures here called ceratohyals and entoglossal cartilage as a new formation, peculiar to birds, and which he styles the paraglossal cartilage. The term entoglossum is by him retained for the anterior part of the copula.

However, nothing of this is to be seen in the cartilaginous state, for KALLIUS' processes do not chondrify, and the copula presents the appearance of a simple median cigar-shaped nodule of cartilage. On the other hand, if the copula is to be regarded as representing an originally separate pair of basihyal elements, the procartilaginous processes described by KALLIUS might be taken as evidence of their former paired origin, which would leave no objection to the identification of the pair of chondrifications which appear just in front of it as ceratohyals. The matter is hardly susceptible of proof from a study of the birds alone, since the intermediate portion of the skeleton of the hyoid arch has been lost and it is not even possible to trace mesenchymal connexions between the stylohyal cartilages and the reputed ceratohyals. An investigation of the crocodile with this point in mind might be fruitful.

The first branchial arch is the only one which develops its cartilaginous skeleton in birds, with the possible exception of the glottal cartilages, which may represent the second. The first branchial arch possesses ceratobranchials and epibranchials.

Behind the copula, and on each side of its posterior process, there is to be seen at late stages in the duck a pair of cartilages, which lie on each side of the glottis and entrance to the larynx. As seen in dorsal view, fig. 14, this pair of cartilages (*g.c.*) suggests that they are serially homologous with the ceratobranchials of the first branchial arch. Further, it may be seen from KALLIUS' (1905) study that in this region at a very early stage there is dense mesenchymatous tissue, continuous with the posterior end of the rudiment of the copula, and this tissue persists as a ligament in later stages connecting the copula with the glottal or laryngeal cartilages. These cartilages are presumably to be regarded as the rudiments of the cricoid cartilages, and the question therefore arises as to whether they are derived from the visceral arch skeleton or not.

The question is complicated by the fact that in the mammal, the cricoid cartilages, if they represent visceral arches at all, must correspond to the fourth branchial arch; in the bird, coming immediately after the first branchial arch, they would correspond to the second. Here, again, a detailed study of the crocodile seems the most likely method of settling the matter, and all that can safely be concluded from the present state of knowledge is the possibility that the second branchial arch of the bird is represented in the glottal cartilages.

The birds are the vertebrates in which the visceral arch skeleton is the least well developed, and this may be associated with the fact that the syrinx has superseded the larynx in importance.

VI. THE PHYLOGENY OF THE AMNIOTA IN THE LIGHT OF THE CHONDROCRANIUM.

All detailed comparative studies of homologous structures in a group as compact as the vertebrates should provide evidence which can be used for the construction of a phylogeny, and the chondrocranium is no exception to this principle.

In the first place, it is important to realize how closely the birds resemble the crocodiles in respect of the chondrocranium. The most characteristic feature of the bird's skull is the possession of a median unpaired prenasal process, a paired metotic cartilage or subcapsular process, and paired infrapolar processes. These structures are also found in the chondrocranium of the crocodile, and in no other form so far investigated. So peculiar and characteristic are these structures that they may safely be regarded as additional evidence of the close affinity between birds and crocodiles. (N.B.—The structure named " prænasal process " in the chondrocranium of Sphenodon by HOWES and SWINNERTON (1901) is a paired element, corresponding to what we have called the cupula anterior of the nasal capsule. Similarly, the cartilago prænasalis which BÄCKSTRÖM has described in the grass-snake (1931) is paired.)

Turning now to the general form of the chondrocranium of the bird, as exemplified by the duck, figs. 54, 55, Plate 49, at the stage when there is the greatest development of the orbital cartilage, it is clear that it bears strong resemblances to the crocodile, and, in a general way, to the other living reptiles. But here it is necessary to take into consideration the evidence presented by the occipito-atlantic joint. In this the birds, as might be expected, resemble the Crocodilia and the Chelonia. This latter fact may perhaps be regarded as a support for the view that the Chelonia are derived from a Diapsid stock, common to them and Crocodilia, and not separately from an Anapsid stock. Sphenodon and the Squamata, on the other hand, show a different type of joint. This latter type is adopted by the mammals, with the modification entailed by the development of the paired condyles from the bases of the occipital arch. That this type, in its main lines, is found in mammals and in Sphenodon and Squamata, can hardly be taken to mean that there is any particularly close affinity between them, since all the other evidence points to Sphenodon and Squamata being more closely related to birds, crocodiles, and Chelonians than to mammals. At the same time it is difficult to imagine that the intersegmental type of joint can have been evolved independently in Sphenodon and Squamata and in mammals.

It must therefore be concluded that there was in the Amphibia a stock in which the occipito-atlantic joint was intersegmental, *i.e.*, the hindmost part of the skull was formed by the posterior sclerotomite of a segment. Subsequently, this stock diverged into its Sauropsidan and Theropsidan branches. In the latter, this type of joint persisted, the single hypocentral condyle becoming gradually replaced by paired condyles formed from the bases of the occipital arches. In the Sauropsida the intersegmental type persisted in Sphenodon and Squamata, which retain the single hypocentral condyle. But in the Chelonia, Crocodilia, and birds the joint became intrasegmental by the addition to the skull of the anterior sclerotomite of the first trunk segment and the formation of a pleurocentral condyle. On this view, therefore, the intrasegmental type of joint is, within the Amniotes secondary, while the intersegmental type is primitive. The evidence from Amphibia, so far as it goes, in the living specialized forms (FORTMANN, 1918; MOOKERJEE, 1930, 1931, *a*) does not contradict this view, for in these animals the hindmost part of the basis cranii is formed from the posterior sclerotomite of a segment. It should perhaps be stressed that it is the cartilaginous condyles of the chondrocranium that are here under discussion, regardless of the bones (basi- or exoccipitals) which may form the condyles in the bony skull. It is to be hoped that fossils will throw further light on this problem.

VII. *Summary.*

1. The segmentation of the head of the duck has been investigated, and the skull has been found to occupy $9\frac{1}{2}$ segments.
2. The chondrification of the skull of the duck has been followed through 14 stages.
3. A procartilaginous connexion has been observed between the polar cartilages and the quadrates, representing the original basal connexion.
4. The orbital cartilage is typically formed, but soon undergoes reduction.
5. The homologies of the regions of the nasal capsule are discussed.
6. The basitrabecular process in birds is a different structure from the infrapolar process.
7. The parachordal does not contribute to the formation of the cochlear capsule.
8. The parachordal shows evidence of segmentation in that:—
   (i) two vertebræ are absorbed into its hinder region;
   (ii) four pairs of cranial ribs are present;
   (iii) five pairs of hypoglossal formaina, and five pairs of occipital arches are present.

9. It is probable that the prevertebral region of the skull occupies four segments, and that a variable number of segments contribute to the formation of a vertebral region out of previously separate vertebræ.

10. The columella auris chondrifies separately from the auditory capsule.

11. The pila antotica is typically developed, but a pila antotica spuria is also formed; in some forms the latter persists, while the former disappears, thus leaving a cartilage which separates *V* 1 from *V* 2.

12. The recessus scalæ tympani becomes covered by the metotic cartilage, probably derived from cranial ribs, and homologous with the subcapsular process of crocodiles.

13. The occipito-atlantic joint in birds is intrasegmental and intervertebral.

14. HAYEK'S conclusions with regard to the nature of the occipito-atlantic joint in mammals and Squamata is supported and confirmed.

15. The glottal cartilages are possibly derived from the visceral arch skeleton.

16. The olfactory nerve traverses the orbit in the duck, but not in the sparrow, where the orbital cartilages form a tunnel for it, between themselves and the inter-orbital septum on to which they are plastered.

17. The closeness of the affinity between birds and crocodiles is emphasized as a result of the study of the chondrocranium.

VIII. REFERENCES.

ADELMANN, H. B. (1922). 'Amer. J. Anat.,' vol. **31**, p. 55.

—— (1926). 'J. Morph.,' vol. **42**, p. 371.

—— (1927). 'J. Morph.,' vol. **44**, p. 29.

ALBRECHT, P. (1880). 'Zool. Anz.,' vol. **3**, pp. 450, 472.

BÄCKSTRÖM, K. (1931). 'Acta Zool.,' vol. **12**, p. 83.

BALFOUR, F. M. (1876). "Monograph on the Development of Elasmobranch Fishes." London.

BARGE, J. A. J. (1917). 'Anat. Hefte,' vol. **55**, p. 415.

DE BEER, G. R. (1922). 'Quart. J. Micr. Sci.,' vol. **66**, p. 457.

—— (1926, *a*). "The Comparative Anatomy, Histology, and Development of the Pituitary Body." Edinburgh.

—— (1926, *b*). 'Quart. J. Micr. Sci.,' vol. **70**, p. 263.

—— (1927). *Ibid.*, vol. **71**, p. 259.

—— (1929). 'Phil. Trans.,' B, vol. **217**, p. 411.

—— (1930). 'Quart. J. Micr. Sci.,' vol. **73**, p. 707.

—— (1931, *a*). *Ibid.*, vol. **74**, p. 591.

—— (1931, *b*). *Ibid.*, vol. **74**, p. 701.

—— and WOODGER, J. H. (1930). 'Phil. Trans.,' B, vol. **218**, p. 373.

Belogolowy, J. (1908). ‘ Bull. Soc. Imp. Nat. Moscou,’ vol. **22**, p. 177.

Born, G. (1879). ‘ Morph. Jahrb.,’ vol. **5**, pp. 62, 401.

Brachet, A. (1921). ‘ Traité d’embryologie des vertébrés.’ Paris.

Braus, H. (1899). ‘ Morph. Jahrb.,’ vol. **27**, p. 415.

de Burlet, H. (1913). ‘ Morph. Jahrb.,’ vol. **45**, p. 393.

Butcher, E. O. (1929). ‘ Amer. J. Anat.,’ vol. **44**, p. 381.

Chiarugi, G. (1890). ‘ Arch. Ital. Biol.,’ vol. **13**, pp. 309, 423.

—— (1898). ‘ Mon. Zool. Ital.,’ vol. **9**, p. 37.

Coghill, C. G. (1929). “ Anatomy and the Problem of Behaviour.” Cambridge.

Corning, H. K. (1900). ‘ Morph. Jahrb.,’ vol. **28**, p. 28.

Dawes, R. (1930). ‘ Phil. Trans.,’ B, vol. **218**, p. 115.

Dohrn, A. (1904). ‘ Mitt. Zool. Stat. Neapel.,’ vol. **17**, p. 1.

Edgeworth, F. H. (1907). ‘ Quart. J. Micr. Sci.,’ vol. **51**, p. 511.

—— (1928). ‘ Phil. Trans.,’ B, vol. **217**, p. 39.

Filatoff, D. (1906). ‘ Anat. Anz.,’ vol. **29**, p. 623.

Fischer, E. (1903). ‘ Z. Morph. Anthrop.,’ vol. **5**, p. 383.

Fortmann, J. P. de G. (1918). ‘ Tidschr. ned. dierk. Ver.’ (2), vol. **16**, p. 121.

Froriep, A. (1883). ‘ Arch. Anat. and Physiol. Anatom Abt.,’ p. 177.

—— (1886). *Ibid.*, p. 69.

Fürbringer, M. (1897). “ Ueber die spino-occipitalen Nerven,” ‘ Festsch. f. Gegenbaur,’ p. 349.

Gaupp, E. (1900). ‘ Anat. Hefte,’ vol. **49**, p. 433.

—— (1906). Hertwig’s ‘ Handbuch,’ vol. **3**, II, Jena, p. 573.

—— (1908, *a*). ‘ Verh. anat. Ges. Jena,’ vol. **22**, p. 181.

—— (1908, *b*). ‘ Denkschr. med-naturw. Ges. Jena,’ vol. **6**, II, p. 539.

Gegenbaur, K. (1872). “ Untersuchungen zur vergleichenden Anatomie der Wirbelthiere. III. Das Kopfskelet der Selachier.” Leipzig.

—— (1873). ‘ Jena Z. Naturwiss.,’ vol. **7**, p. 1.

Goodrich, E. S. (1911). ‘ Proc. Zool. Soc.,’ p. 101.

—— (1917). ‘ Quart. J. Micr. Sci.,’ vol. **62**, p. 539.

—— (1918). *Ibid.*, vol. **63**, p. 1.

—— (1930). “ Studies on the Structure and Development of Vertebrates.” London.

Harrison, R. G. (1895). ‘ Arch. mikr. Anat.,’ vol. **46**, p. 500.

Hayek, H. (1923). ‘ SitzBer. Akad. Wiss. Wien.,’ Jahrg, 1921/2, vol. **130**, p. 25.

—— (1924). ‘ Morph. Jahrb.,’ vol. **53**, p. 137.

Howes, G. B., and Swinnerton, H. H. (1901). ‘ Trans. Zool. Soc.,’ vol. **16**, p. 1.

Hubbard, M. E. (1908). ‘ Amer. Nat.,’ vol. **42**, p. 466.

Huxley, T. H. (1858). ‘ Proc. Roy. Soc.,’ vol. **9**, p. 381.

Jager, J. (1924). “ Über die Segmentierung der Hinterhauptregion, und die Beziehung der Cartilago acrochordalis zur Mesodermcommissur.” Groningen. (Also ‘ Morph. Jahrb.,’ vol. **56**, 1926, p. 1.)

JOHNSON, C. E. (1913). ‘ Amer. J. Anat.,’ vol. **14**, p. 119.

KALLIUS, E. (1905). ‘ Anat. Hefte,’ vol. **28**, p. 305.

KOLTZOFF, N. K. (1901). ‘ Bull. Soc. Imp. Nat. Moscou,’ vol. **15**, p. 259.

LILLIE, T. F. (1908). “ The Development of the Chick.” New York.

MACBRIDE, E. W. (1932). ‘ Biol. Rev.,’ vol. **7**, p. 108.

MALL, F. P. (1897). ‘ J. Morph.,’ vol. **12**, p. 395.

MEEK, A. (1911). ‘ J. Anat.,’ vol. **45**, p. 357.

MOOKERJEE, H. K. (1930). ‘ Phil. Trans.,’ B, vol. **218**, p. 415.

—— (1931, *a*). *Ibid.*, vol. **219**, p. 165.

—— (1931, *b*). ‘ Nature,’ vol. **127**, p. 705.

MUGGIA, G. (1931). ‘ Monit. zool. Ital.,’ vol. **42**, p. 275.

NEAL, H. V. (1918). ‘ J. Morph.,’ vol. **30**, p. 433.

NOORDENBOS, W. (1905). ‘ Petrus Camper,’ vol. **3**, p. 367.

PARKER, T. J. (1892). ‘ Phil. Trans.,’ B, vol. **182**, p. 25.

—— (1893). *Ibid.*, vol. **183**, p. 73.

PARKER, W. K. (1866). ‘ Phil. Trans.,’ vol. **156**, p. 113.

—— (1869). ‘ Phil. Trans.,’ vol. **159**, p. 755.

—— (1876). ‘ Trans. Linn. Soc. London,’ Zool., vol. **1**, p. 99.

—— (1883). ‘ Trans. Zool. Soc.,’ vol. **11**, p. 263.

PATTERSON, T. J. (1907). ‘ Biol. Bull.,’ vol. **13**, p. 121.

PIIPER, J. (1928). ‘ Phil. Trans.,’ B, vol. **210**, p. 285.

PLATT, J. B. (1889). “ Bull. Mus. Comp. Zool. Harvard,’ vol. **17**, p. 171.

—— (1891). ‘ J. Morph.,’ vol. **5**, p. 79.

REX, H. (1897). ‘ Arch. mikr. Anat.,’ vol. **50**, p. 71.

—— (1901). *Ibid.*, vol. **57**, p. 229.

—— (1905). ‘ Morph. Jahrb.,’ vol. **33**, p. 107.

—— (1924). ‘ Z. ges. Anat.’ ‘ Z. Anat. EntwGesch,’ vol. **70**, p. 512.

SCHAUINSLAND, H. (1900). ‘ Arch. mikr. Anat.,’ vol. **56**, p. 747.

SCHREINER, K. E. (1902). ‘ Z. wiss. Zool.,’ vol. **72**, p. 467.

VAN SETERS, W. H. (1922). ‘ Arch. Biol.,’ vol. **32**, p. 373.

SHIINO, K. (1914). ‘ Anat. Hefte,’ vol. **50**, p. 253.

SONIES, F. (1907). ‘ Petrus Camper,’ vol. **4**, p. 395.

SUSCHKIN, P. P. (1899). ‘ Nouv. Mém. Soc. Imp. Nat. Moscou,’ vol. **16**, p. 1.

TONKOFF, W. (1900). ‘ Anat. Anz.,’ vol. **18**, p. 296.

VOIT, M. (1909). ‘ Anat. Hefte,’ vol. **38**, p. 425.

WEISS, A. (1901). ‘ Z. wiss. Zool.,’ vol. **69**, p. 492.

VAN WIJHE, J. W. (1882). “ Ueber die Mesodermsegmente und die Entwicklung der Nerven des Selachierkoptes.” Amsterdam.

—— (1902). ‘ Proc. K. Akad. Wetensch.,’ Amst., vol. **5**, p. 47.

—— (1922). ‘ Bijdr. Dierk.,’ vol. **22**, p. 271.

WILLIAMS, L. W. (1910). ‘ Amer. J. Anat.,’ vol. **11**, p. 55.

IX. Explanation of Lettering.

a., acrochordal cartilage.
a.b., abducens nerve.
a.c., auditory capsule.
a.d.c., aditus conchæ.
a.p., anterior parachordal cartilage.
a.p.l., auditory placode.
a.r., rib of atlas vertebra.
a.s., auditory sac.
a.s.or., aperture in nasal capsule communicating with orbital sinus.
a.t., pleurocentrum (body) of atlas vertebra; odontoid process.
a.t.n., neural arch of atlas vertebra.
at.t., atrio-turbinal.
a.x., pleurocentrum of axis vertebra.
a.x.n., neural arch of axis vertebra.
a.x.r., rib of axis vertebra.
b.c.f., basicranial fenestra.
b.r., backgrowing roof of nasal capsule.
b.t.p., basitrabecular process.
c., occipital condyle.
c.a., columella auris.
c.a.c., canalicular portion of auditory capsule.
c.b., ceratobranchial of 1st branchial arch.
c.c., cochlear portion of auditory capsule.
c.c.n., cavum conchale.
c.e.c., ectochoanal cartilage.
ce.h., ceratohyal cartilage.
c.g. 1, 2, dorsal-root ganglion of cervical nerve of 1st, 2nd, trunk segment.
ch., choana.
c.m., paired occipital condyle of mammals.
c.n., concha nasalis.
cop., copula.
cop.p., posterior process of copula.
c.r. 6–9, cranial ribs of 6th to 9th segments.
c.s., crista semicircularis.
c.s.c. 1, 2, 1st, 2nd, cervical sclerotome.
cu., cupola anterior of nasal capsule.
e., eye.
e.b., epibranchial cartilage.
e.c., entoglossal cartilage (ceratohyals fused).
e.p., ethmoid plate.
e.r., external rectus muscle.
e.t., ethmoturbinal.
f., facial nerve.
f.a., foramen for abducens nerve.
f.a.c., foramen for auditory nerve.
f.d., fenestra dorsalis of nasal capsule.
f.e., foramen epiphaniale.
f.f., foramen for facial nerve.
f.g., foramen for glossopharyngeal nerve.
f.l., fenestra lateralis of nasal capsule.
f.m., fissura metotica.
f.n., fenestra narina.
f.o., foramen ovale of auditory capsule.
f.o.a., foramen olfactorium advehens.
f.o.e., foramen olfactorium evehens.
f.o.p., foramen for ophthalmic artery.
f.p., foramen prooticum (for complete trigeminal nerve).
f.pl., foramen perilymphaticum of auditory capsule.
f.p.r., foramen for profundus branch of trigeminal nerve.
f.p.s., foramen prooticum spurium (for maxillary and mandibular branches of trigeminal nerve).
f.s., fossa subarcuata.
f.s.n.a., fenestra septi nasalis anterior.
f.s.n.p., fenestra septi nasalis posterior.
f.t., foramen for trochlear nerve.
f.v., foramen for vagus nerve.
g.c., glottal cartilage.
g.n., glossopharyngeal nerve.
g.s., 1, 2, gill-slit 1, 2.
h.a., hypocentrum of atlas vertebra.
h.a.x., hypocentrum of axis vertebra.
h.c., head cavity (of first or premandibular somite).
h.f., foramina for hypoglossal nerve-roots.
h.fe., hypophysial fenestra.
h.n., hypoglossal nerve.
h.o. 1, hypocentrum of 1st occipital vertebra.
h.o. 2, hypocentrum of 2nd occipital vertebra (proatlas vertebra).
h.y.p.m., hypoglossal muscles.
I., olfactory nerve.
i.c., internal carotid artery.
i.n.f.r., inferior rectus muscle.

i.n.t.r., internal rectus muscle.
i.o., inferior oblique muscle.
i.p., incisura antotica.
ip.p., infrapolar process.
i.s., interorbital septum.
J.o., Jacobson's organ.
l.c.f., lateral carotid foramen.
l.j., line of junction between parietotectal and paranasal cartilages.
l.n.d., lachrymo-nasal duct.
m. 1, 2, 3, 1st, 2nd, 3rd, metotic somite.
M.c., Meckel's cartilage.
mc.c., metotic cartilage.
m.m.t., inner margin of maxillo-turbinal (seen by transparency).
m.t., maxillo-turbinal.
n., notochord.
n.a.b., notch for abducens nerve.
n.c., neural crest.
n.g., nasal gland.
n.o., notch for oculomotor nerve.
n.o.p., notch for optic nerve.
n.p., notch for profundus branch of trigeminal nerve.
n.t., naso-turbinal.
n.t.r., notch for trochlear nerve.
o.a., definitive occipital arch.
o.a. 6–9, occipital arch of the 6th–9th segment.
o.a.i., occipito-atlantic intercostal muscle.
o.c., orbital cartilage.
o.c.a., anterior portion of orbital cartilage.
o.c.c., orbitocapsular commissure.
o.c.p., posterior portion of orbital cartilage.
o.c.p.r., orbitocapsular process.
o.n., oculomotor nerve.
o.n.f., orbitonasal fissure.
o.p., otic process of quadrate.
o.s. 1, 2, 1st, 2nd, occipital sclerotome.
o.v. 1, first occipital vertebra.
o.v. 2, second occipital vertebra (proatlas vertebra).
p., parachordal cartilage.
p.a., pila antotica.
p.a.h., hypocentrum of proatlas vertebra.
p.an., planum antorbitale.
p.a.p., pleurocentrum of proatlas vertebra.
p.a.s., pila antotica spuria.
p.a.t., proatlas interdorsal arch.
p.c., polar cartilage.
p.f., prefacial commissure.
pn.c., paranasal cartilage.
pn.p., prenasal process.
p.o.p., postorbital process.
p.p., pterygoid process of quadrate.
p.r.a., processus retro-articularis of Meckel's cartilage.
p.r.o., prootic process.
p.s., planum supraseptale.
p.s.c., paraseptal cartilage.
p.s.p., posterior portion of planum supraseptale.
p.t., processus tectalis.
pt.c., parietotectal cartilage of nasal capsule.
p.v., prevomer bone.
pv.c., prevomer cartilage.
q., quadrate.
r., ridge overlying ramus medialis nasi.
r.a., recessus anterior of nasal capsule.
r.e.c., recessus extraconchalis of nasal capsule.
r.f., recessus frontalis of nasal capsule.
r.l.n., ramus lateralis nasi.
r.m.n., ramus medialis nasi.
r.n.t., rudimentary naso-turbinal.
r.r., ramus recurrens of abducens nerve.
s., spiracle.
s.a., anterior portion of floor of nasal capsule.
s.a.n., spinal accessory nerve.
sc.p., subcapsular process.
se.c., sphenethmoid commissure.
se.p., sphenethmoid process.
s.h., stylohyal cartilage.
s.m., septomaxillary bone.
s.n., nasal septum.
s.o., superior oblique muscle.
s.o.p., supra-occipital process.
s.o.r., orbital sinus.
s.p., posterior portion of floor of nasal capsule.
s.r. 1, 2, 1st, 2nd, spinal nerve-root.
s.t., suprapolar cartilage.
s.u.r., superior rectus muscle.
s.w., side wall of nasal capsule.
t., trabecula cranii.
t.c., trabecula communis.
t.m., supra-orbital cartilage.
t.m.e., rudiment of tænia medialis.

t.n., trigeminal nerve
t.r., trochlear nerve.
t.s., tectum synoticum.
V 1, 1st or profundus root of trigeminal nerve.
V 2, 2nd or maxillary branch of trigeminal nerve.
V 3, 3rd or mandibular branch of trigeminal nerve.
v.a., vertebral artery.
v.c.i., vestigial cranial intercostal muscles.
v.n., vagus nerve.
v.o., vacuity in orbital cartilage.
v.r. 6–9, ventral nerve-roots of the 6th–9th segment.
v.s., vacuities in interorbital septum.
v.t., vacuity in backgrowing roof of nasal capsule.
z.a., zona annularis of nasal capsule.

X. Explanation of Plates.

(Except where otherwise stated, all figures are of the duck.)

Plate 46.

Fig. 26.—Parasagittal section through an embryo of the duck at the 10-somite stage. Anterior end to right.
Fig. 27.—Ditto, at the 23-somite stage.
Fig. 28.—Ditto, at the 78-hour stage.
Fig. 29.—Ditto, at the 132-hour stage.
Fig. 30.—Ditto, at the 132-hour stage (anterior to 29).
Fig. 31.—Ditto, at the 7-day stage. Anterior end to left.
Fig. 32.—Ditto, at the 7-day stage. Median to 31.

Plate 47.

Fig. 33.—Dorsal view of skull at 132-hour stage.
Fig. 34.—Left side view of skull at 138-hour stage.
Fig. 35.—Dorsal view of ditto.
Fig. 36.—Left side view of skull at 144-hour stage.
Fig. 37.—Dorsal view of ditto.
Fig. 38.—Left side view of skull at 156-hour stage.
Fig. 39.—Dorsal view of ditto.
Fig. 40.—Left side view of skull at 160-hour stage.
Fig. 41.—Dorsal view of ditto.
Fig. 42.—Left side view of skull at 7-day stage.
Fig. 43.—Dorsal view of ditto.

Plate 48.

Fig. 44.—Left side view of 7½-day stage.
Fig. 45.—Dorsal view of ditto.
Fig. 46.—Left side view of skull at 8-day stage.
Fig. 47.—Dorsal view of ditto.
Fig. 48.—Left side view of posterior region of skull at 8-day stage.
Fig. 49.—Median view of left half of posterior region of skull at 9-day stage.
Fig. 50.—Left side view of skull at 8½-day stage.
Fig. 51.—Dorsal view of ditto.

PLATE 49.

FIG. 52.—Left side view of skull at 9-day stage.
FIG. 53.—Dorsal view of ditto (lower jaw omitted).
FIG. 54.—Left side view of skull at 9½-day stage.
FIG. 55.—Dorsal view of ditto (visceral arches omitted).
FIG. 56.—Dorsal view of skull at 11-day stage (visceral arches omitted).

PLATE 50.

FIG. 57.—Left side view of skull at 14-day stage.
FIG. 58.—Dorsal view of ditto (visceral arches omitted).
FIG. 59.—Posterior view of ditto.
FIG. 60.—Anterior view of orbito-temporal region of ditto.

PLATE 51.

FIG. 61.—Ventral view of right half of nasal capsule of ditto.
FIG. 62.—Dorsal view of right half of nasal capsule of ditto.
FIG. 63.—Ventral view of left half of posterior region of ditto.
FIG. 64.—Anterior view of thick transverse section through anterior region of nasal capsule of ditto.
FIG. 65.—Anterior view of thick transverse section through middle region of nasal capsule of ditto.
FIG. 66.—Anterior view of thick transverse section through posterior region of nasal capsule of ditto.
FIG. 67.—Left side view of nasal capsule at 17-day stage.
FIG. 68.—Dorsal view of ditto.
FIG. 69.—Ventral view of ditto.
FIG. 70.—Transverse section through ditto, at level A—A.

PLATE 52.

FIG. 71.—Transverse section through duck embryo at 8-day stage, showing cranial rib of 6th segment.
FIG. 72.—Ditto, showing cranial rib of 7th segment.
FIG. 73.—Ditto, showing cranial rib of 7th and 8th segments.
FIG. 74.—Ditto, showing cranial ribs of 8th and 9th segments.
FIG. 75.—Horizontal section through duck embryo at 8-day stage, showing cranial ribs.
FIG. 76.—Horizontal section through sparrow embryo near full time, showing interorbital septum with orbital cartilages plastered on to it on each side, and enclosing olfactory nerves in tunnels.

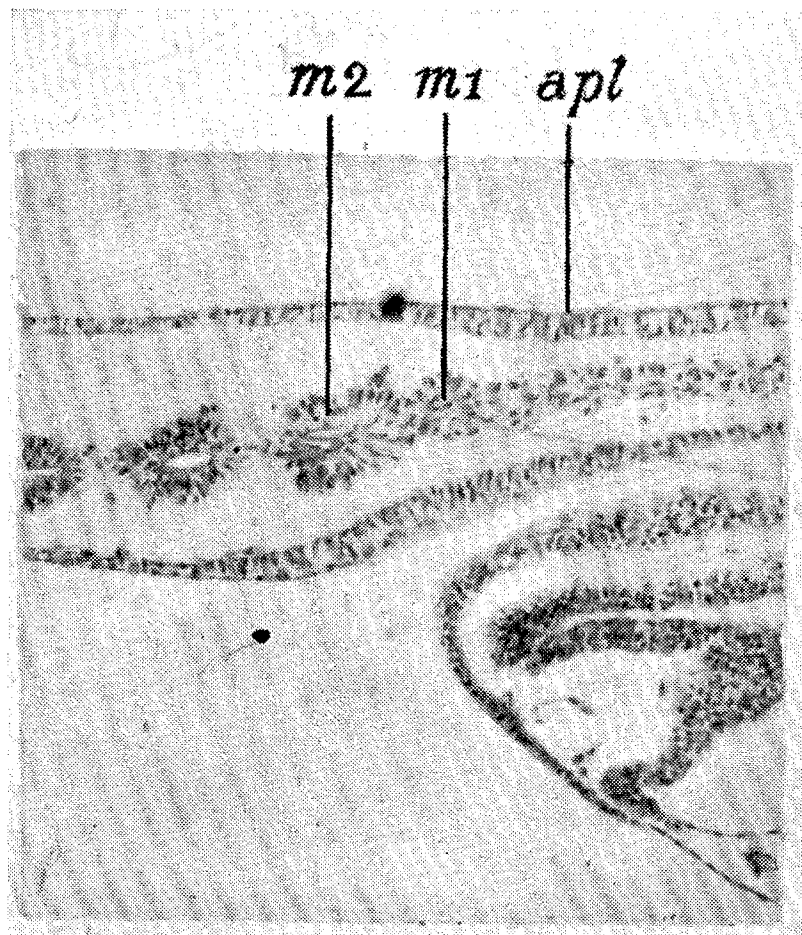

26

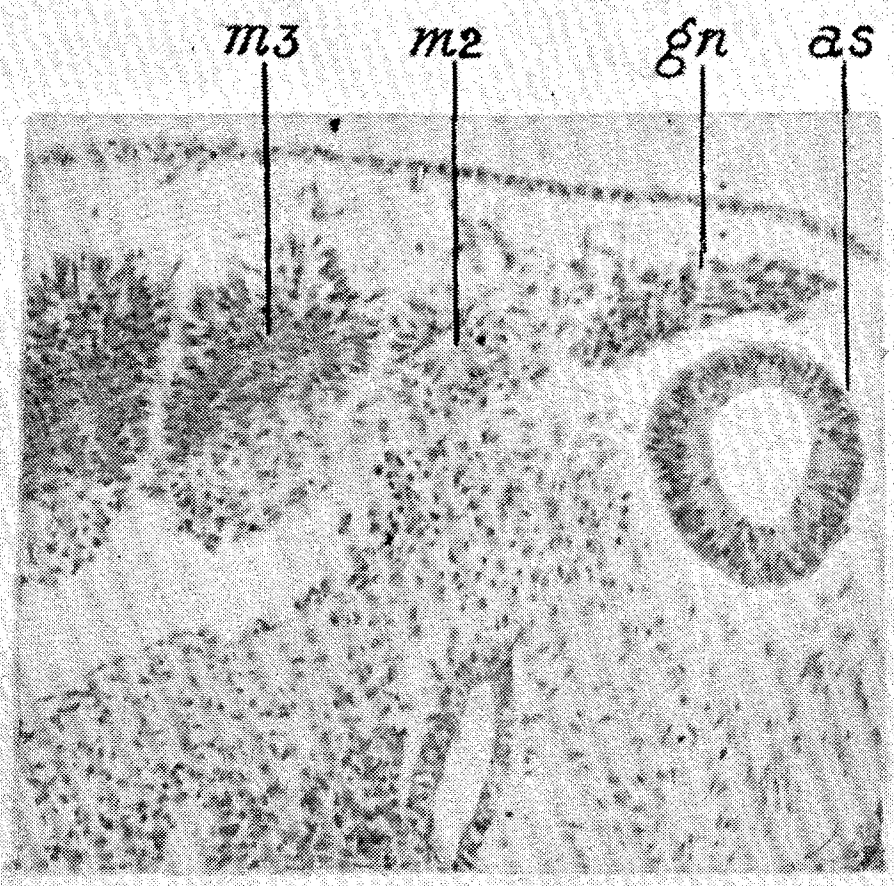

27

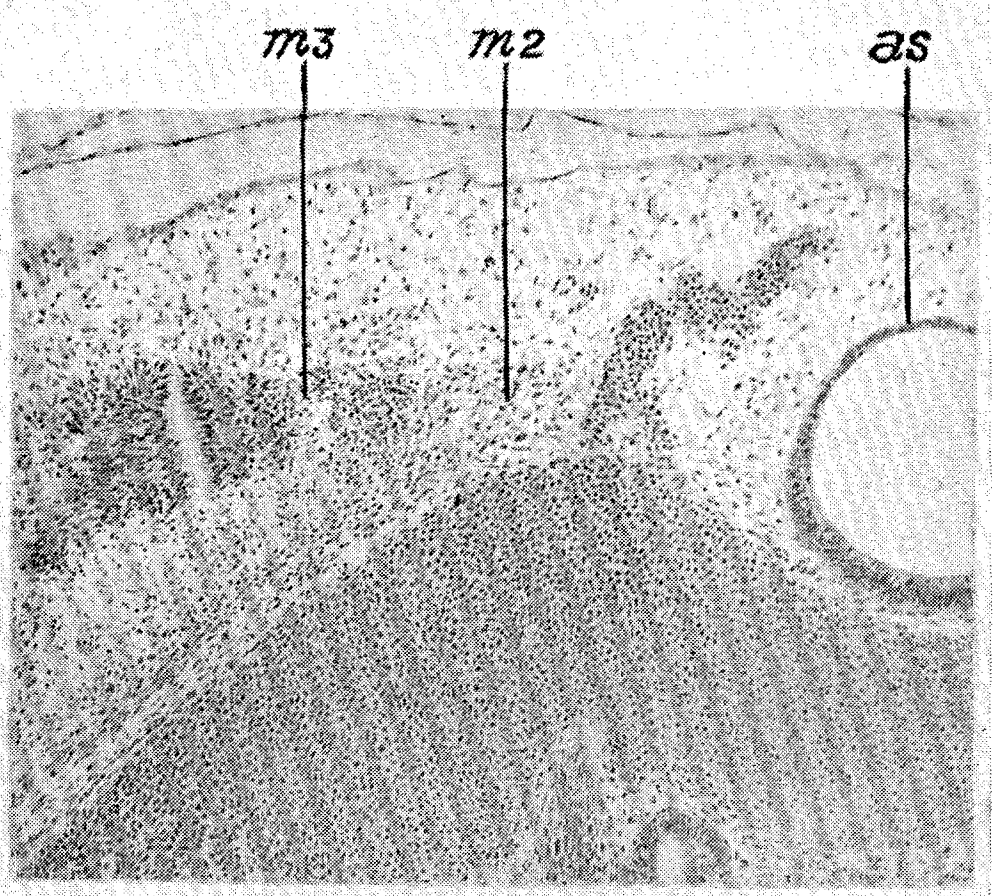

28

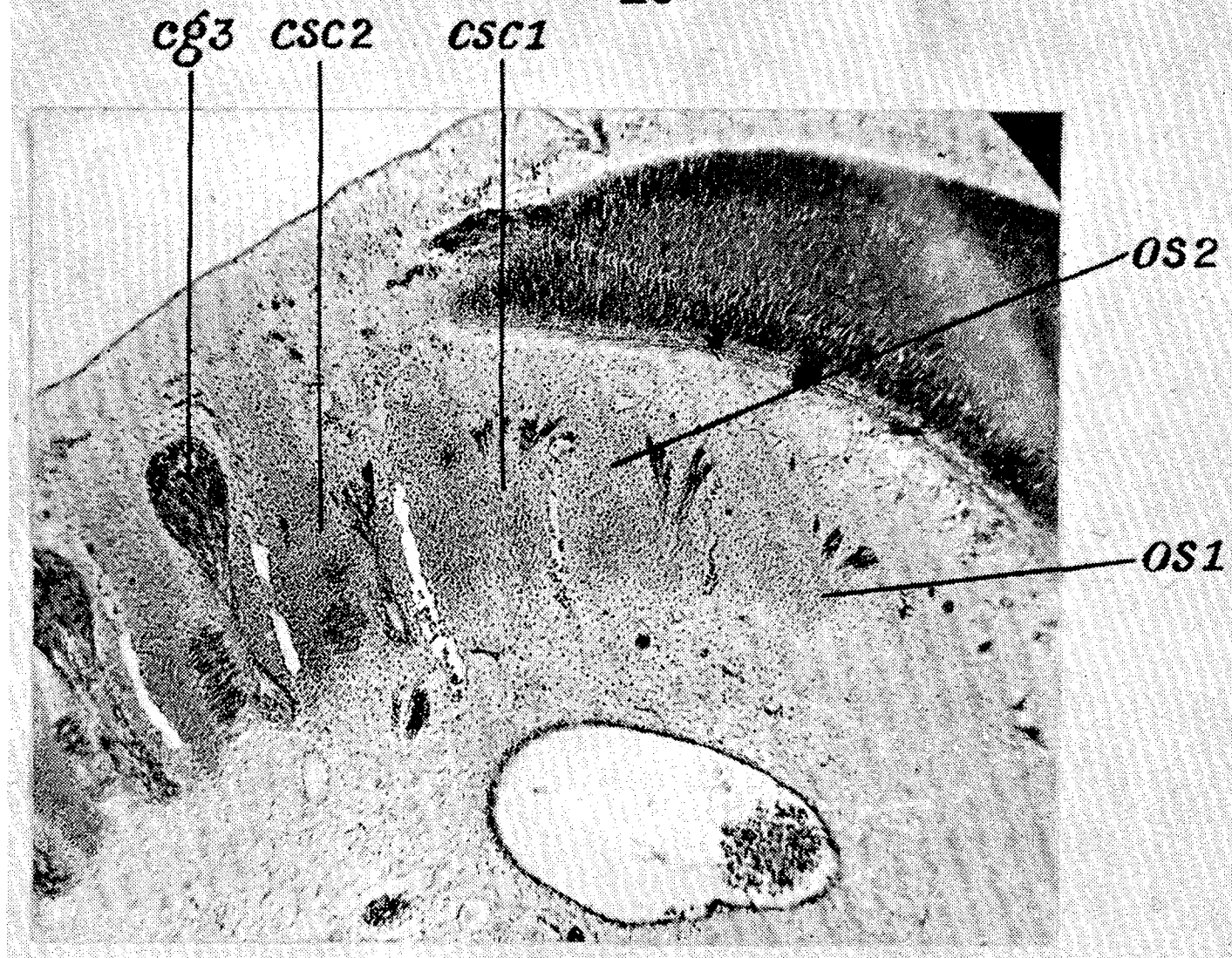

29

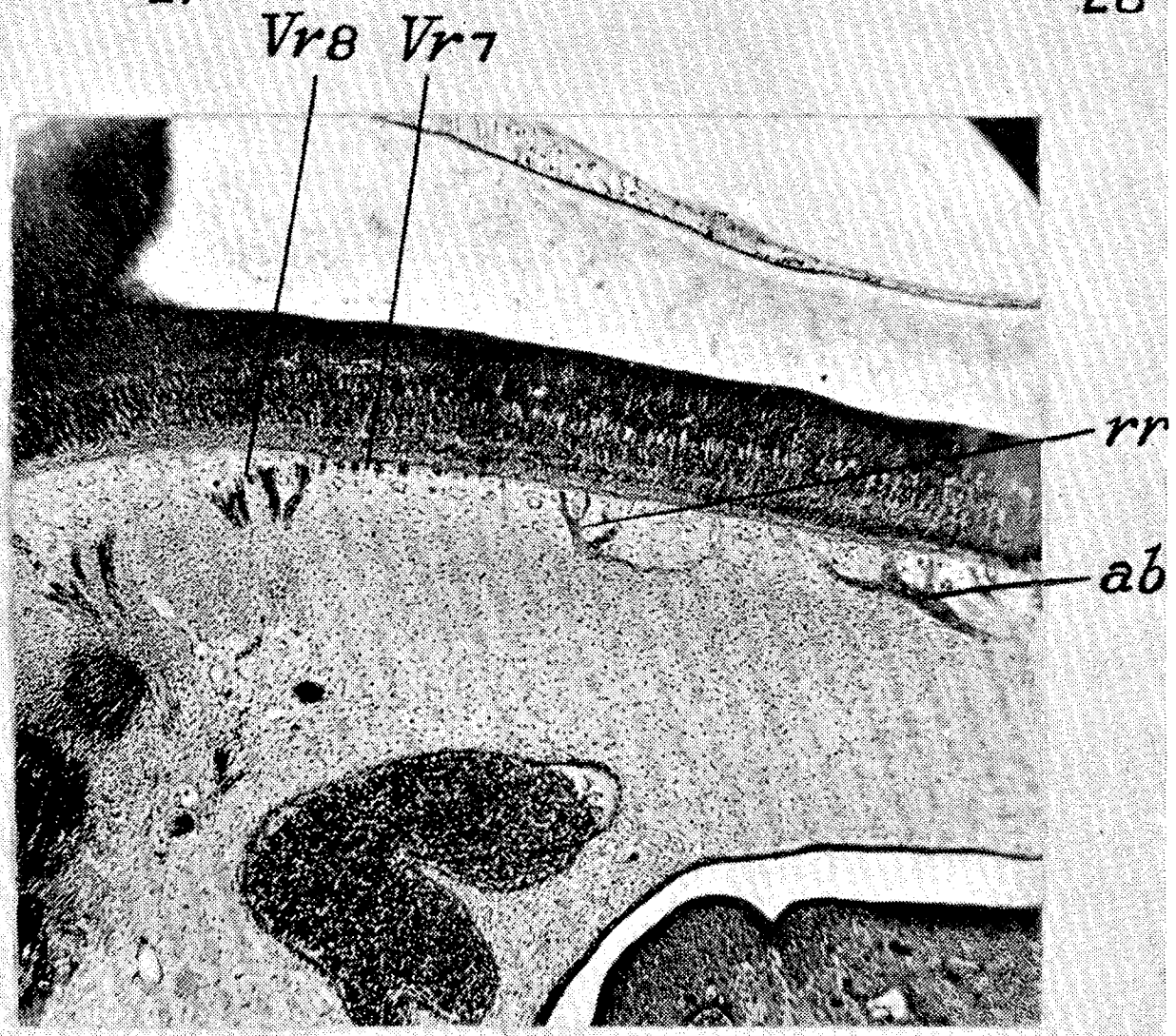

30

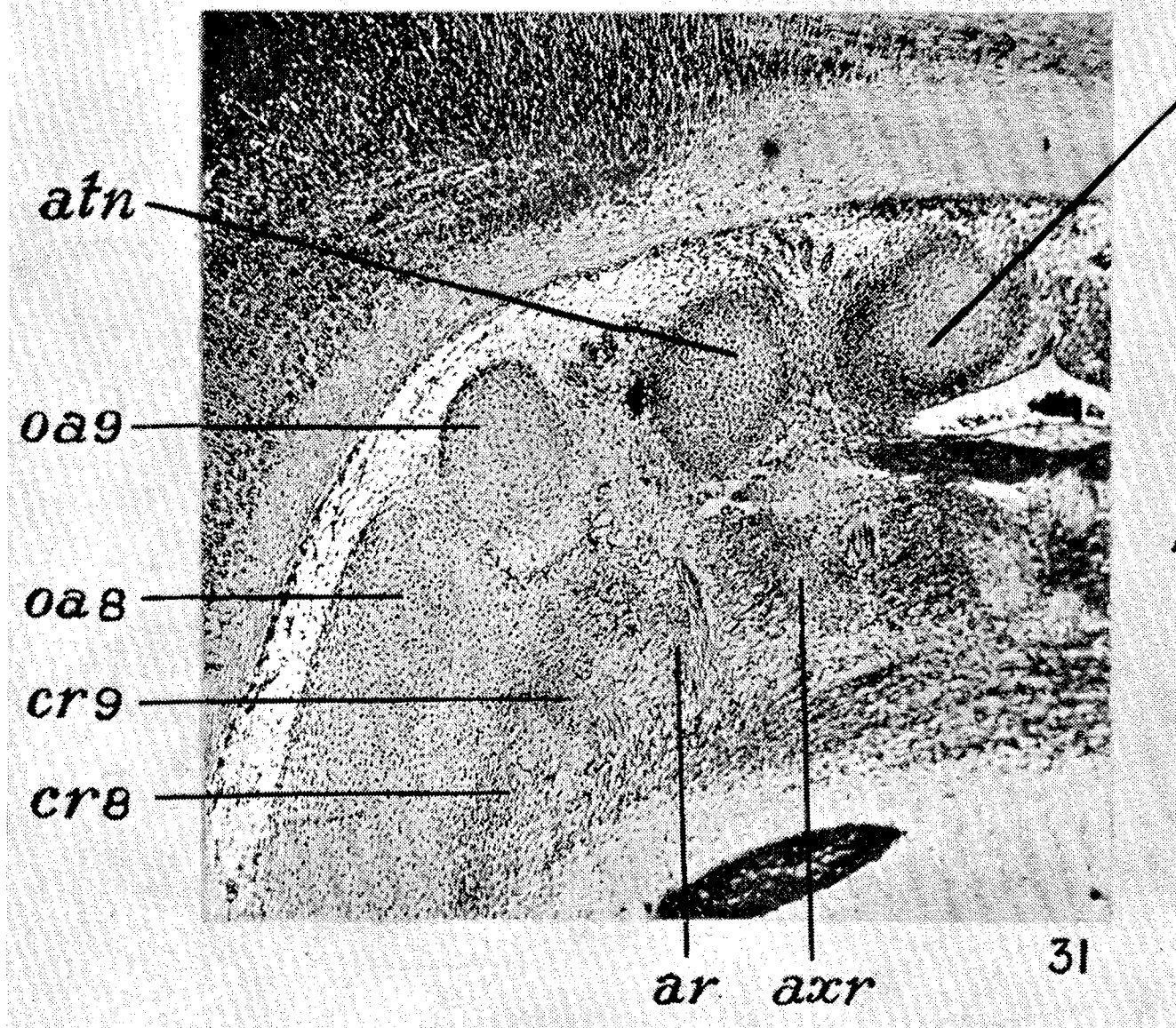

31

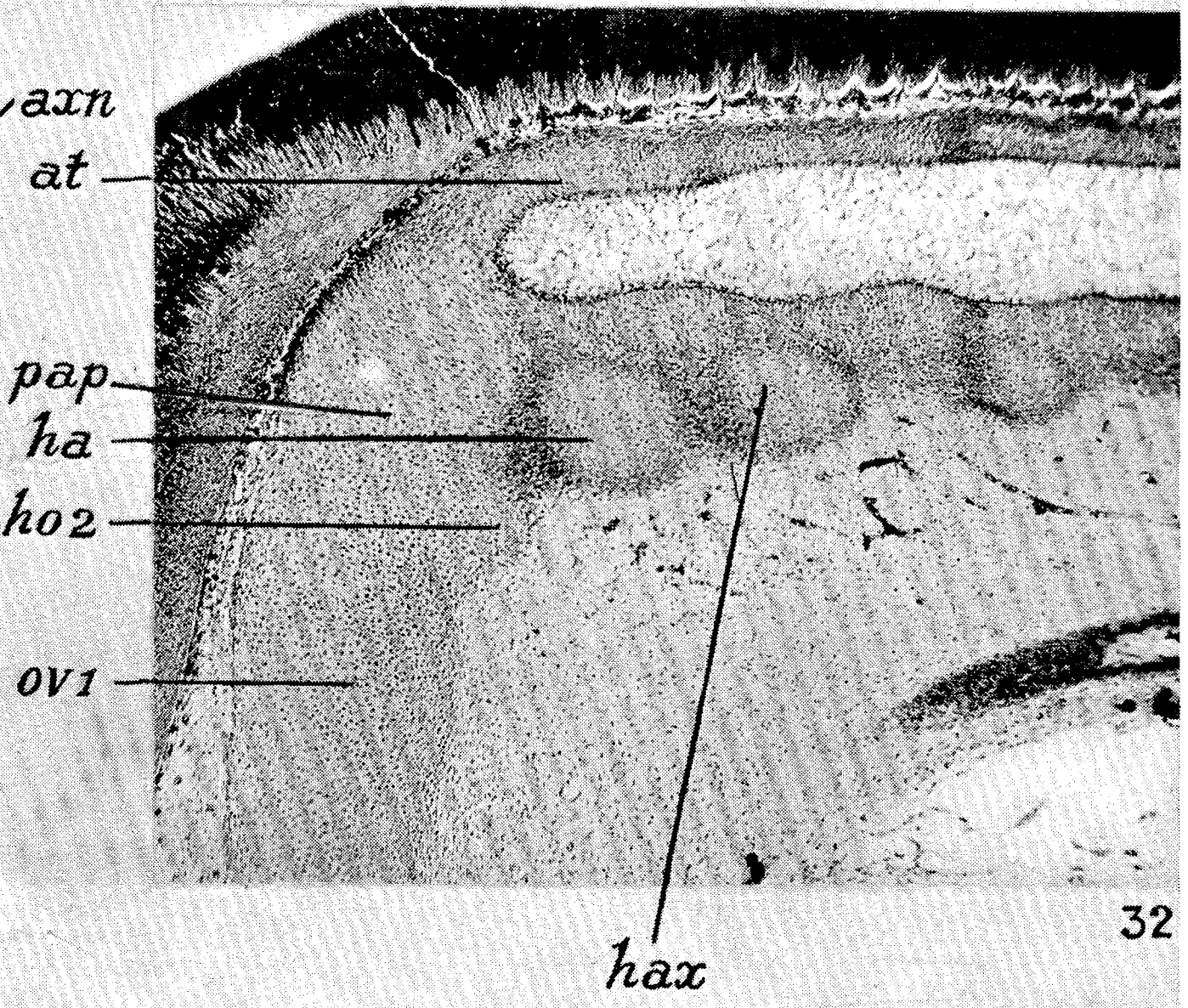

32

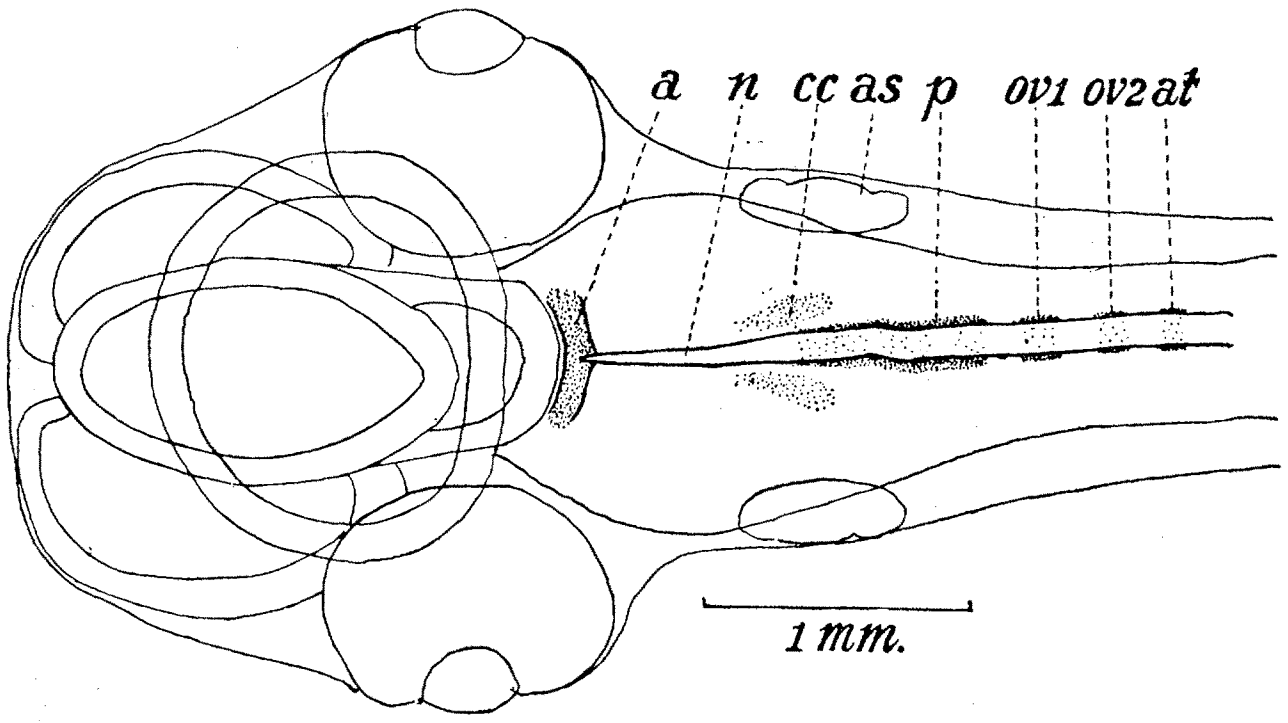

Fig. 33.

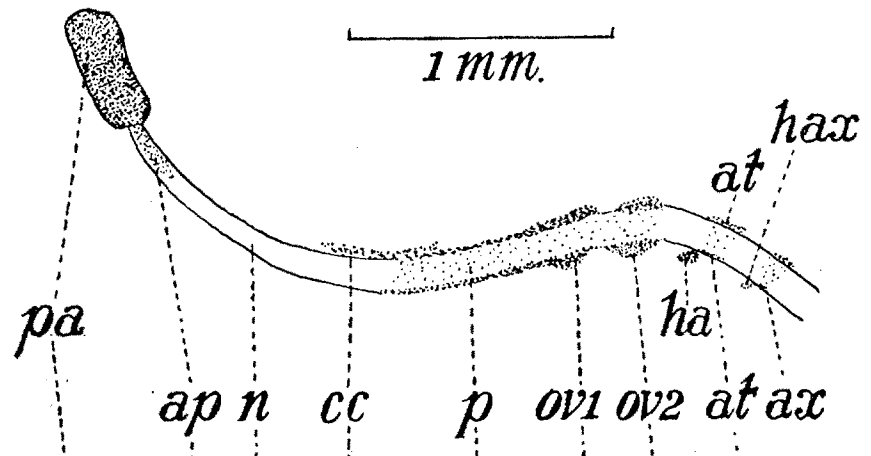

Fig. 34.

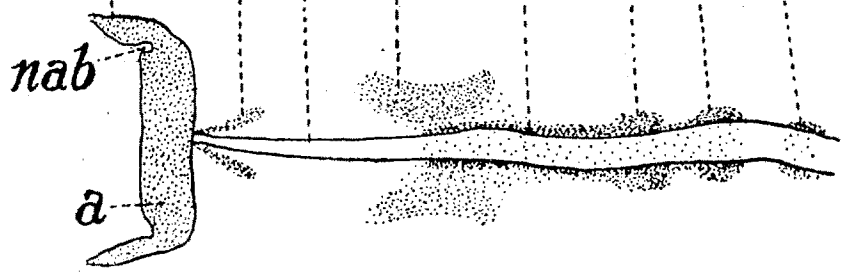

Fig. 35.

Fig. 36.

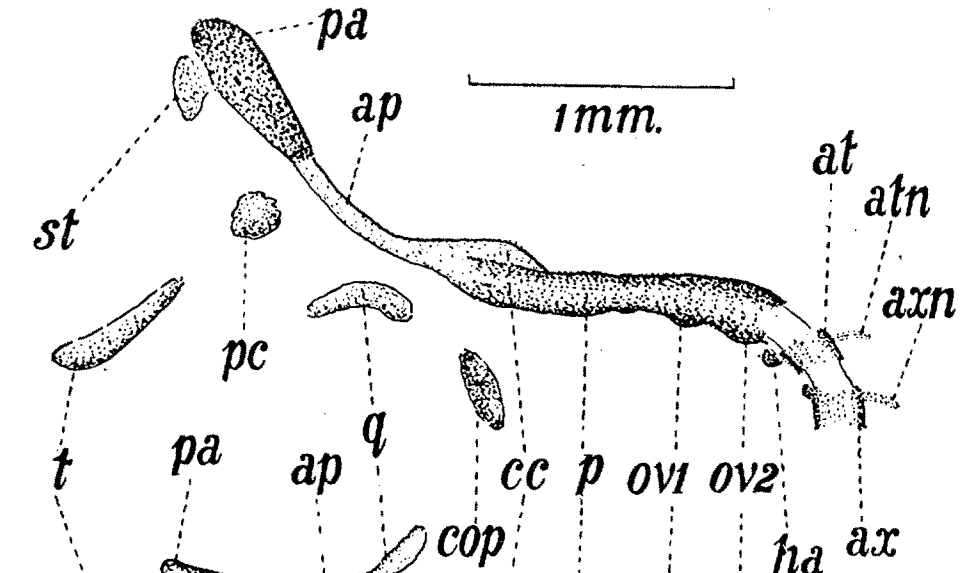

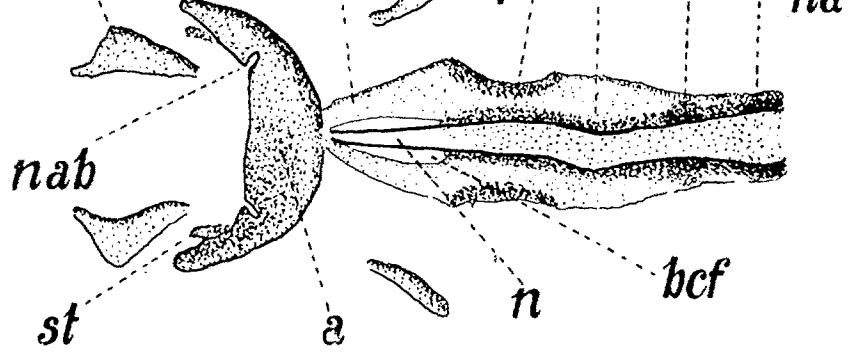

Fig. 37.

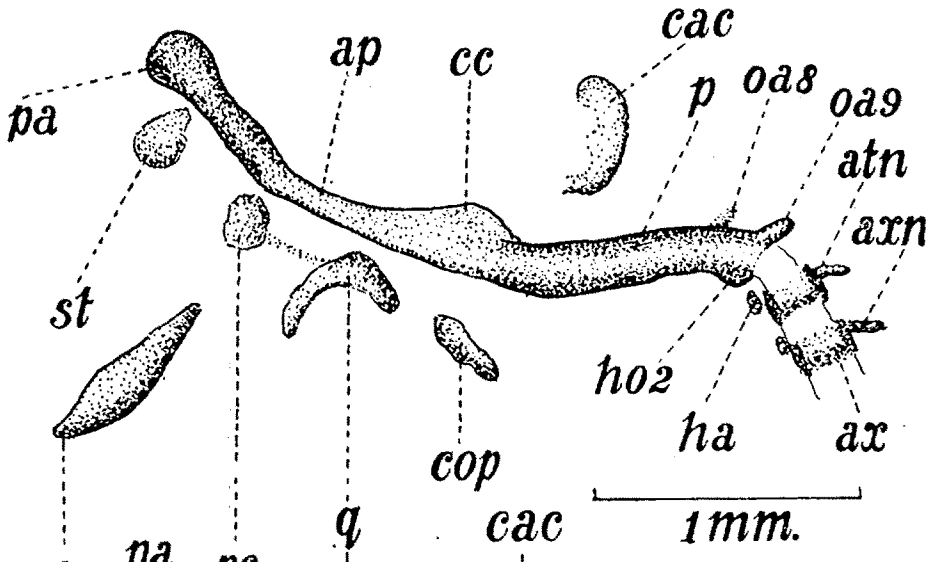

Fig. 38.

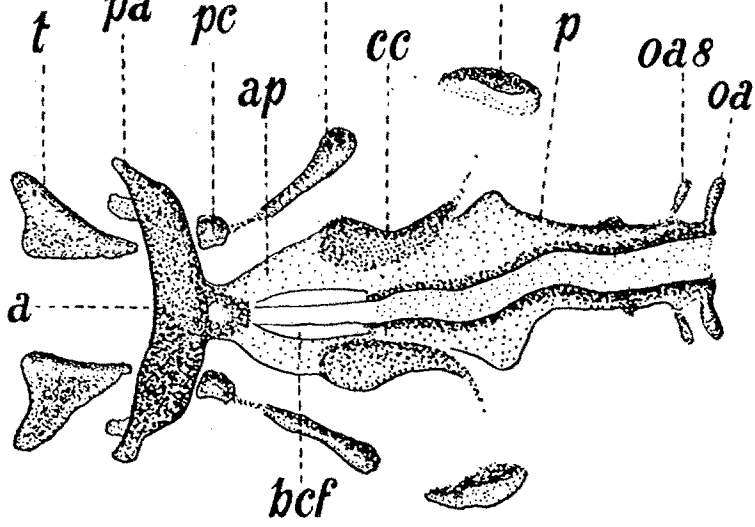

Fig. 39.

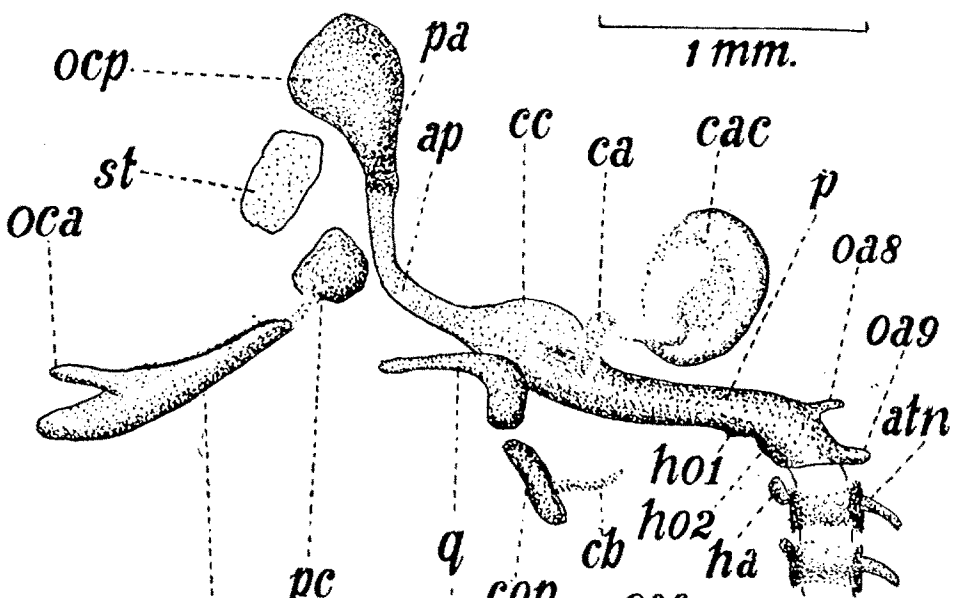

Fig. 40.

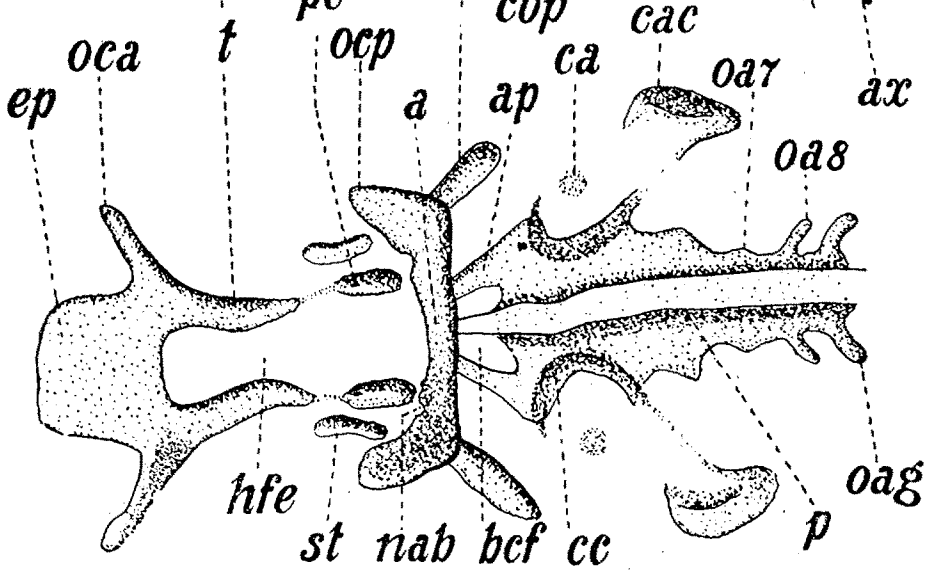

Fig. 41.

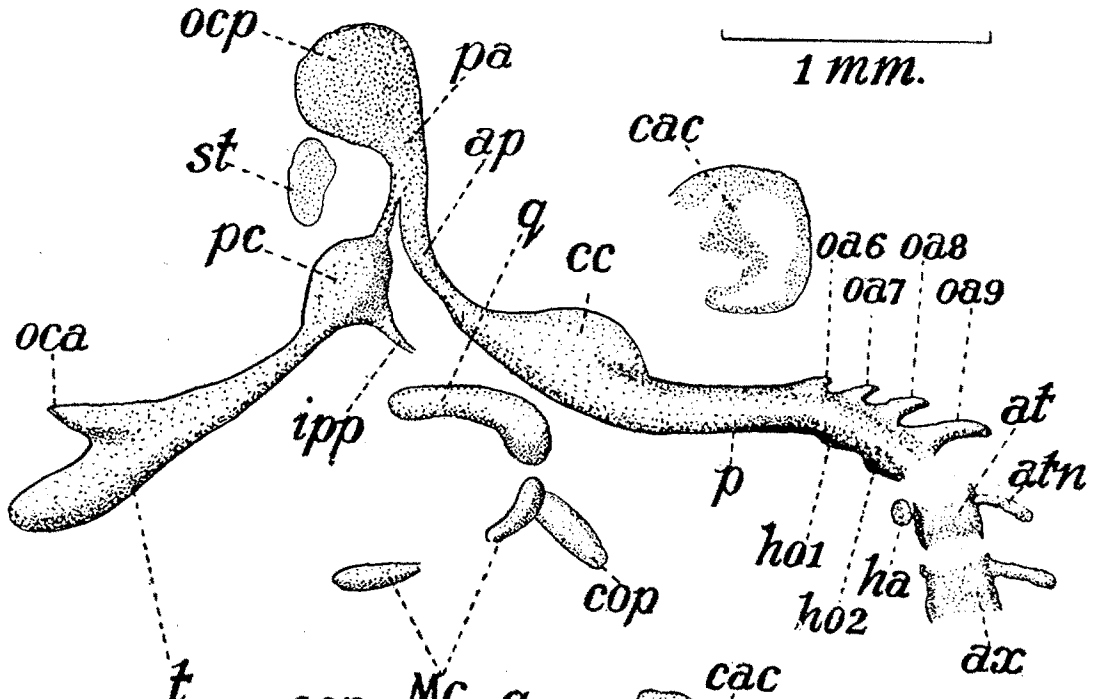

Fig. 42.

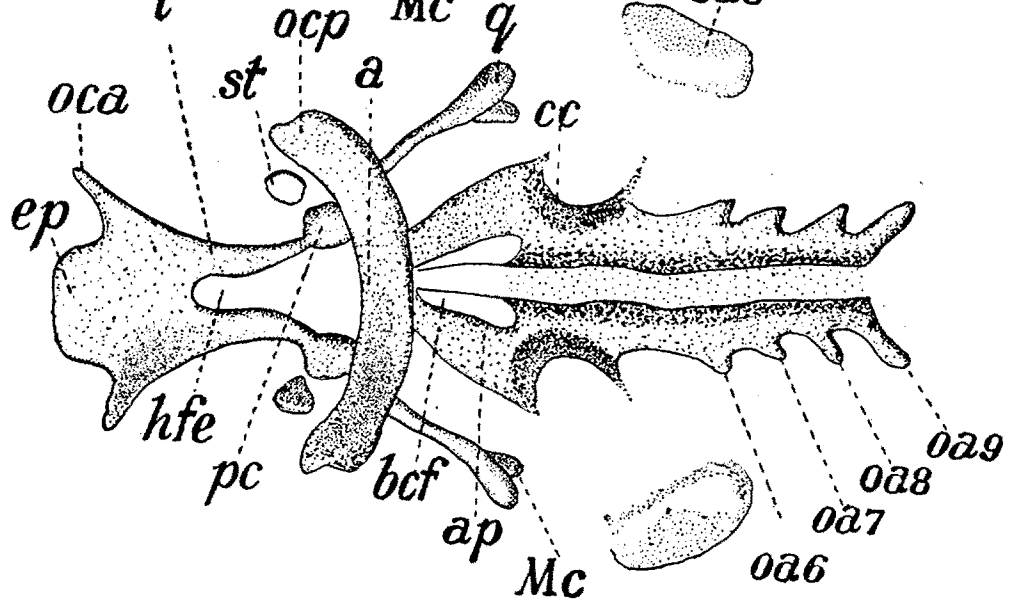

Fig. 43.

G. R. de B. del.

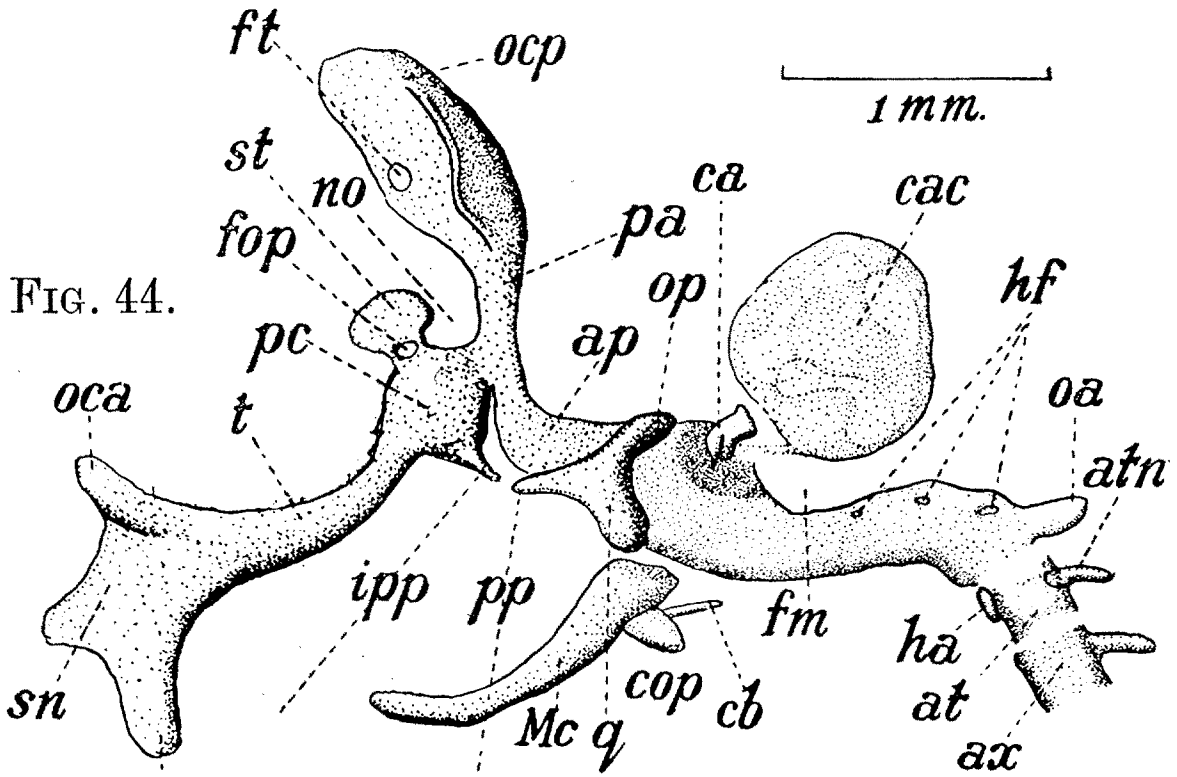

Fig. 44.

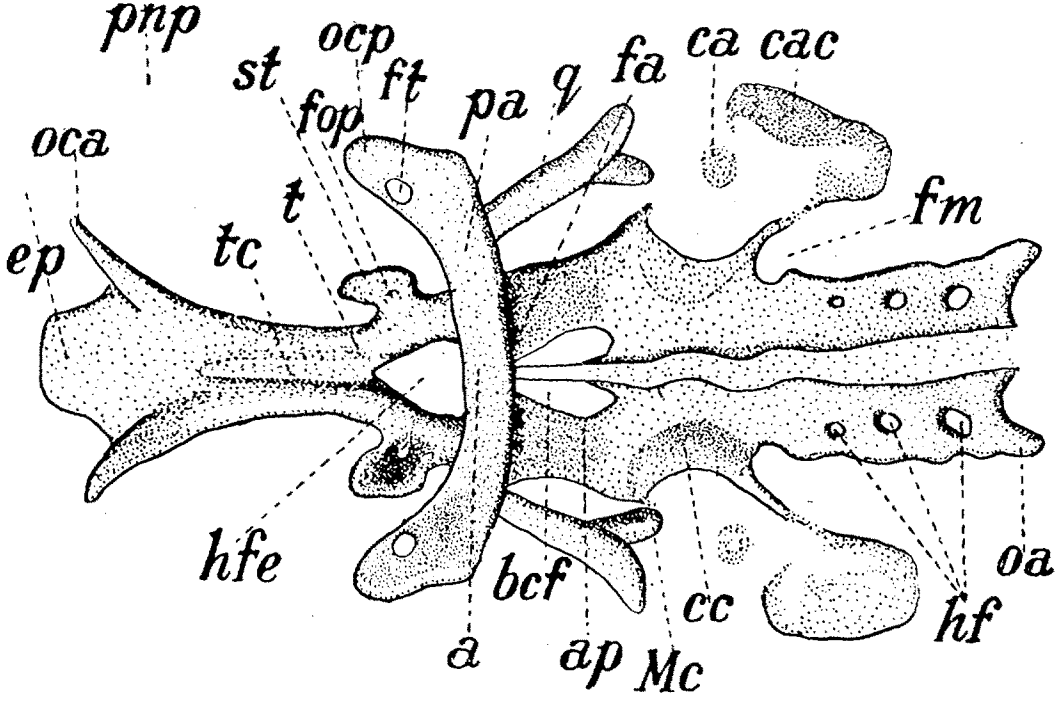

Fig. 45.

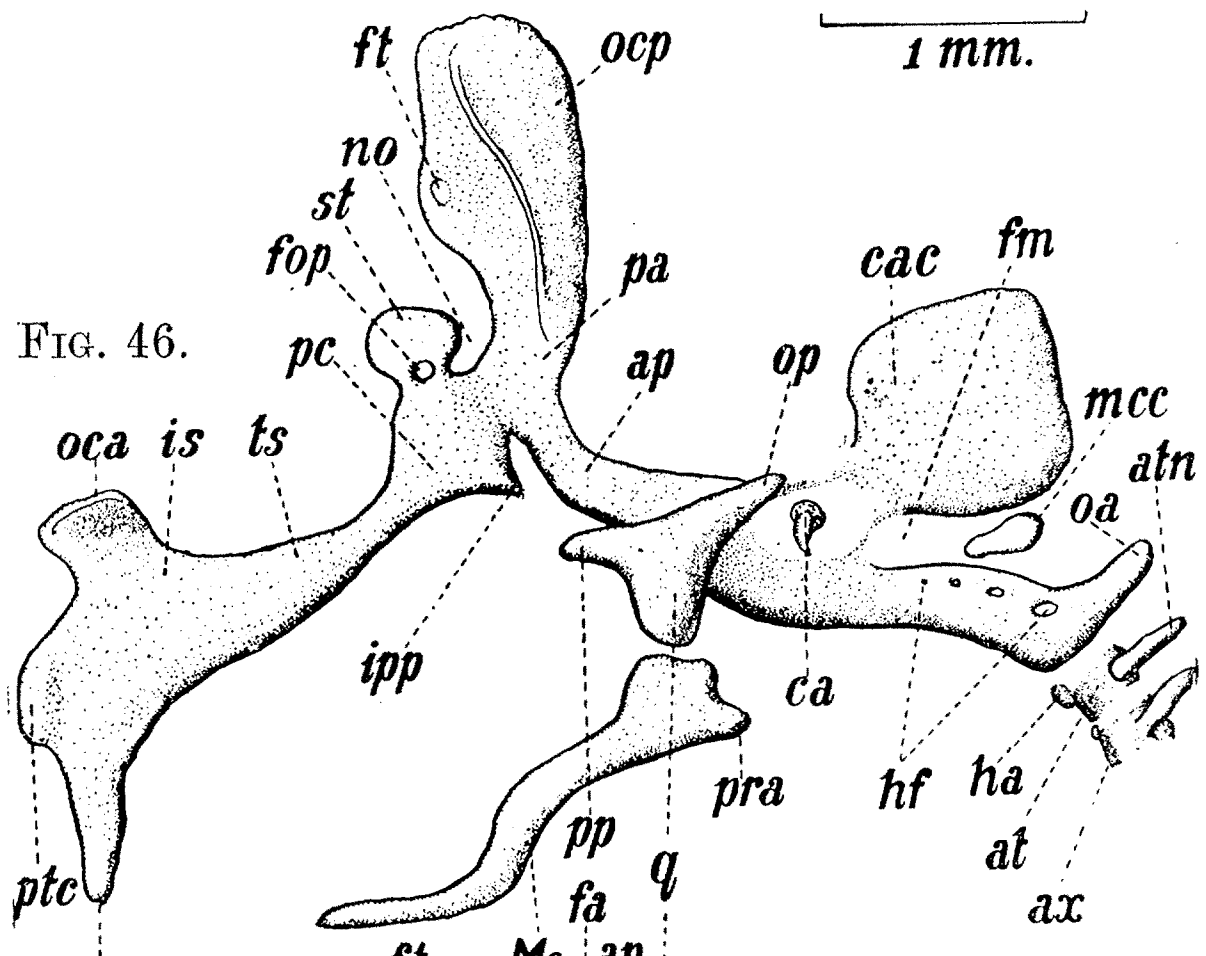

Fig. 46.

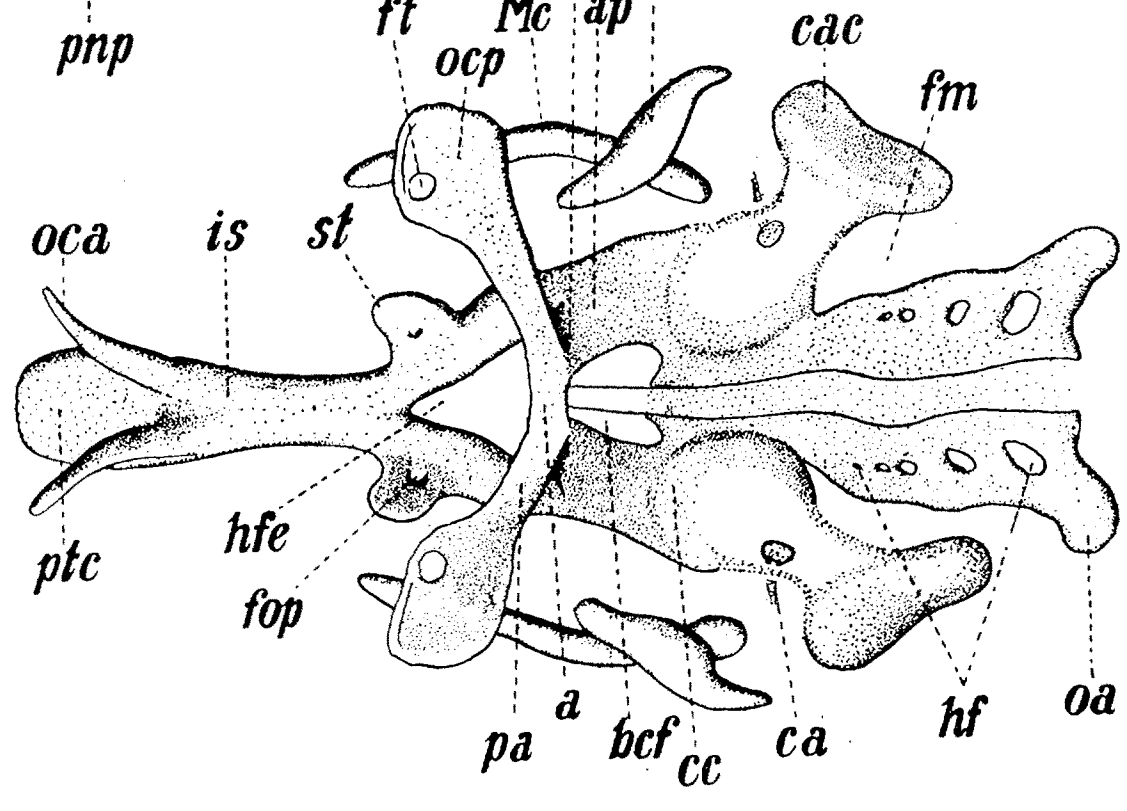

Fig. 47.

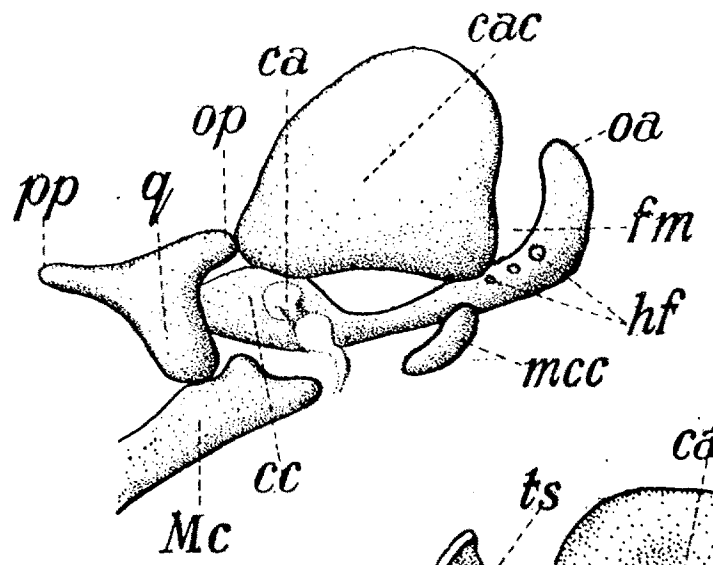

Fig. 48.

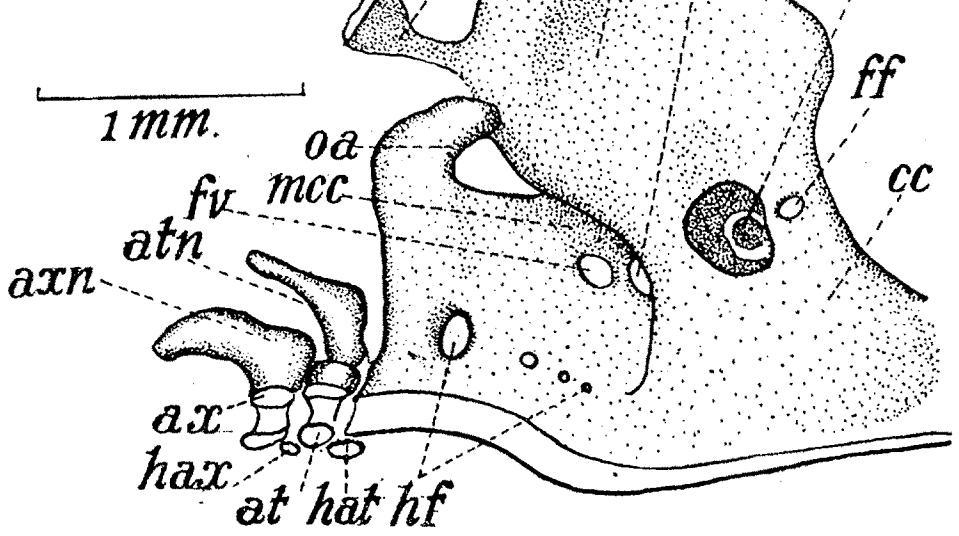

Fig. 49.

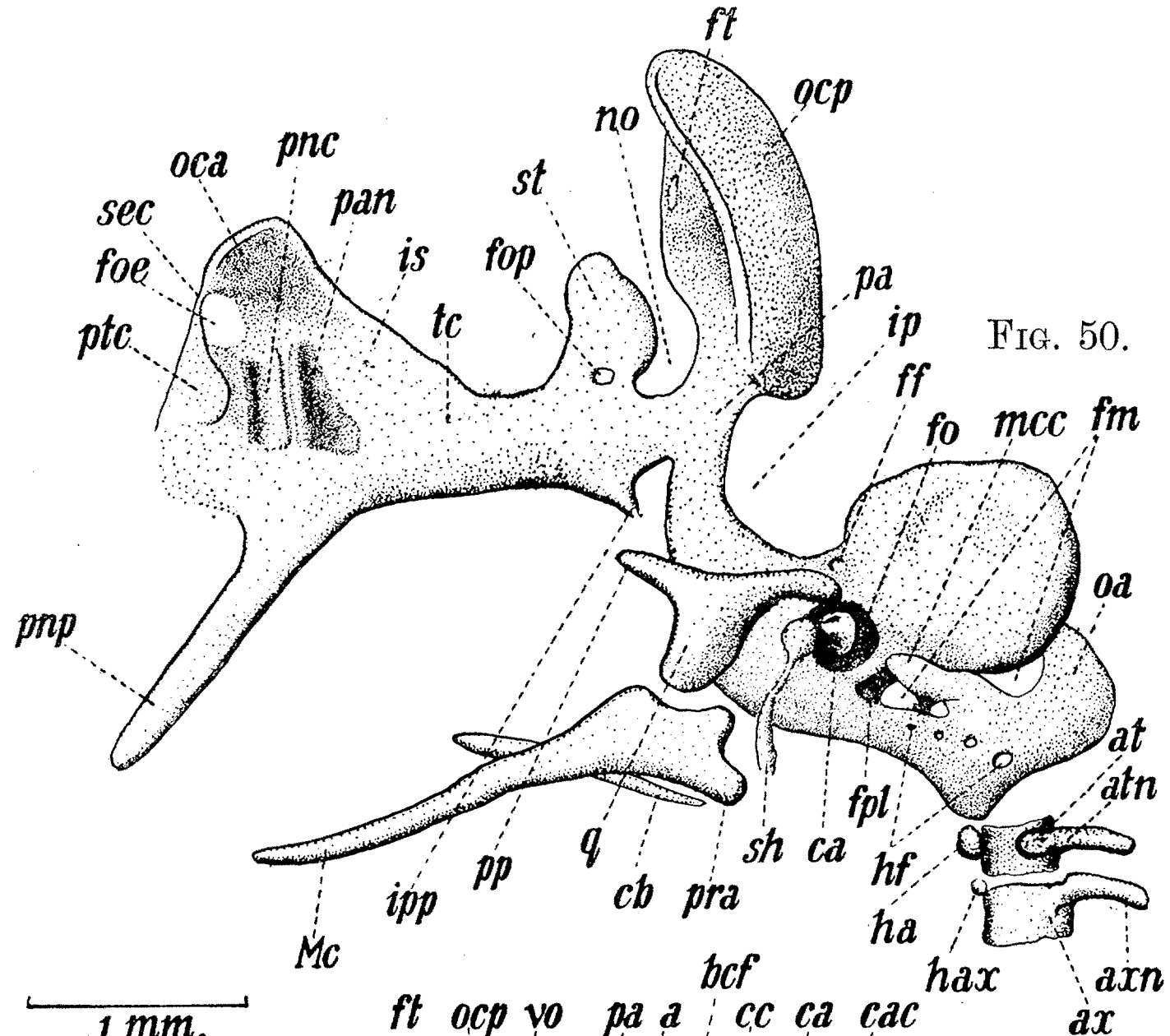

Fig. 50.

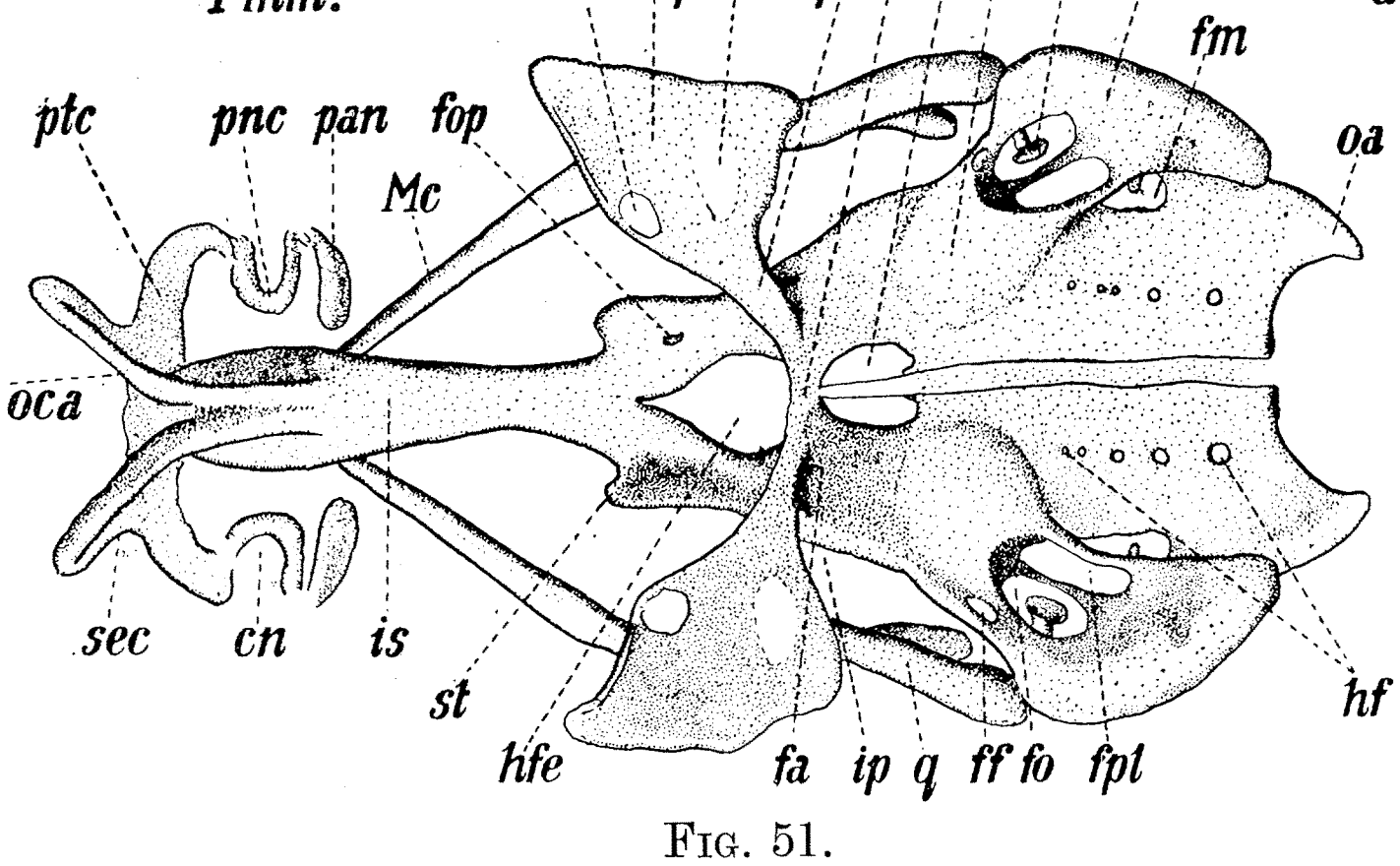

Fig. 51.

G. R. de B. del.

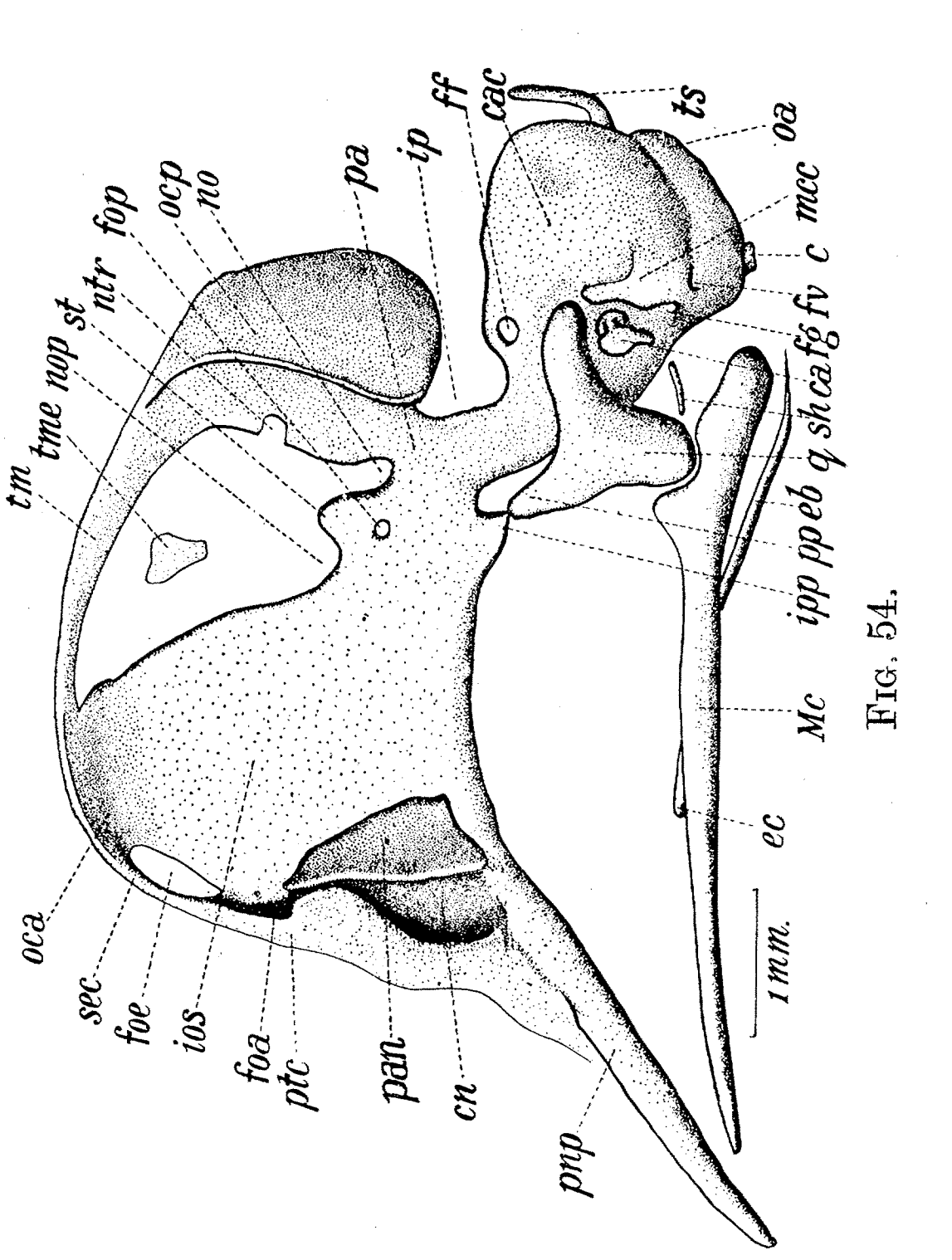

FIG. 54.

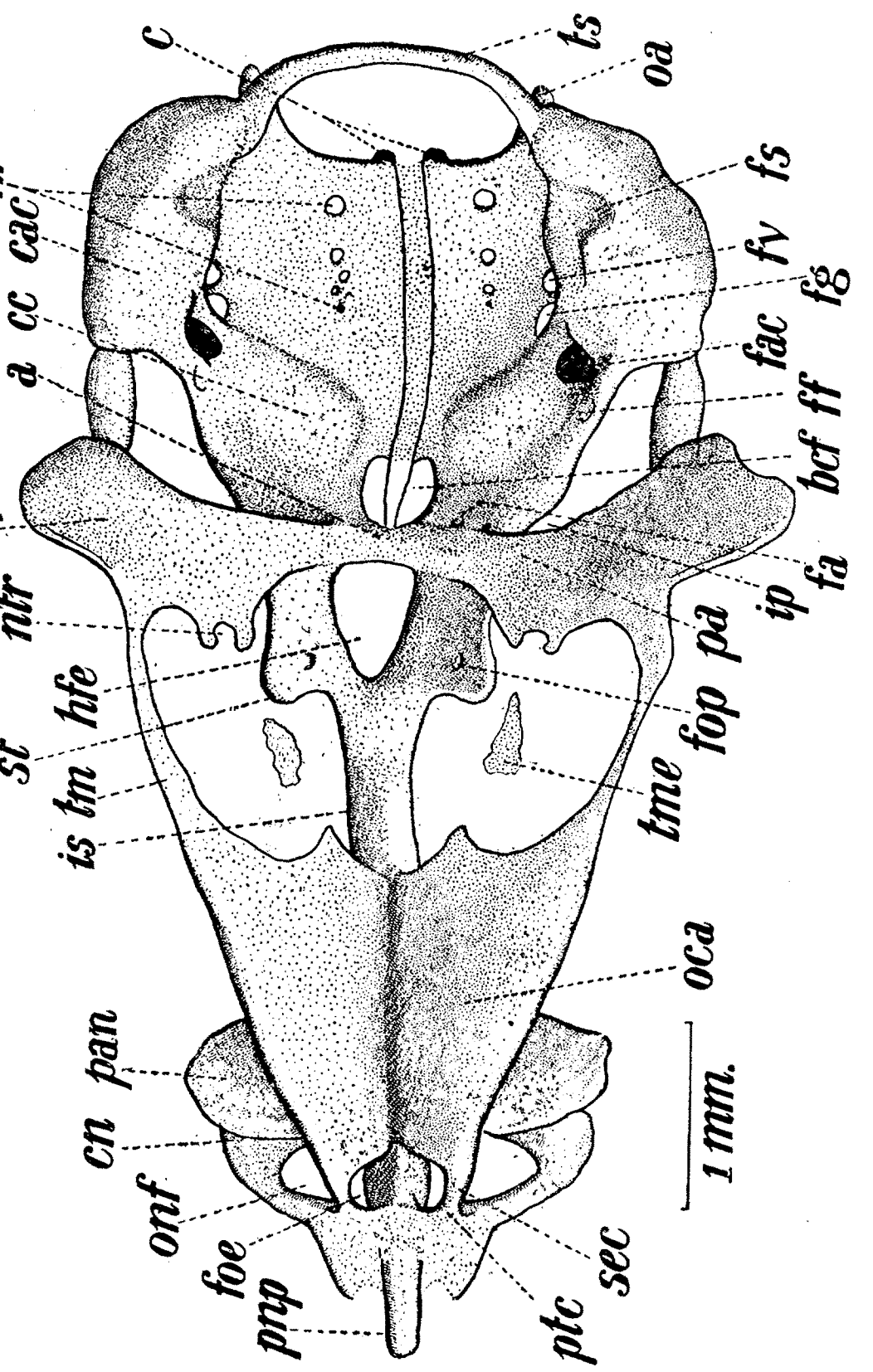

FIG. 55.

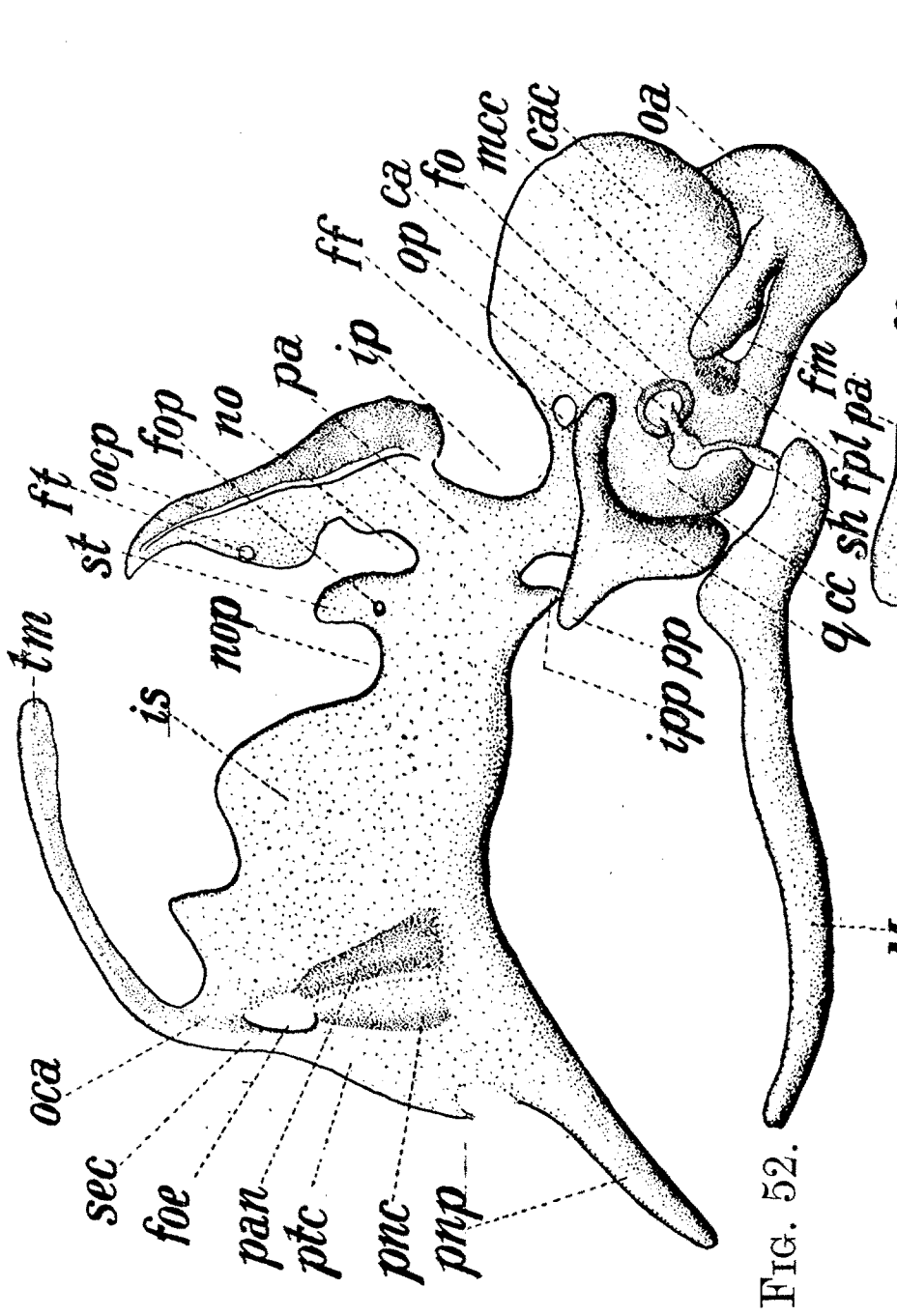

FIG. 52.

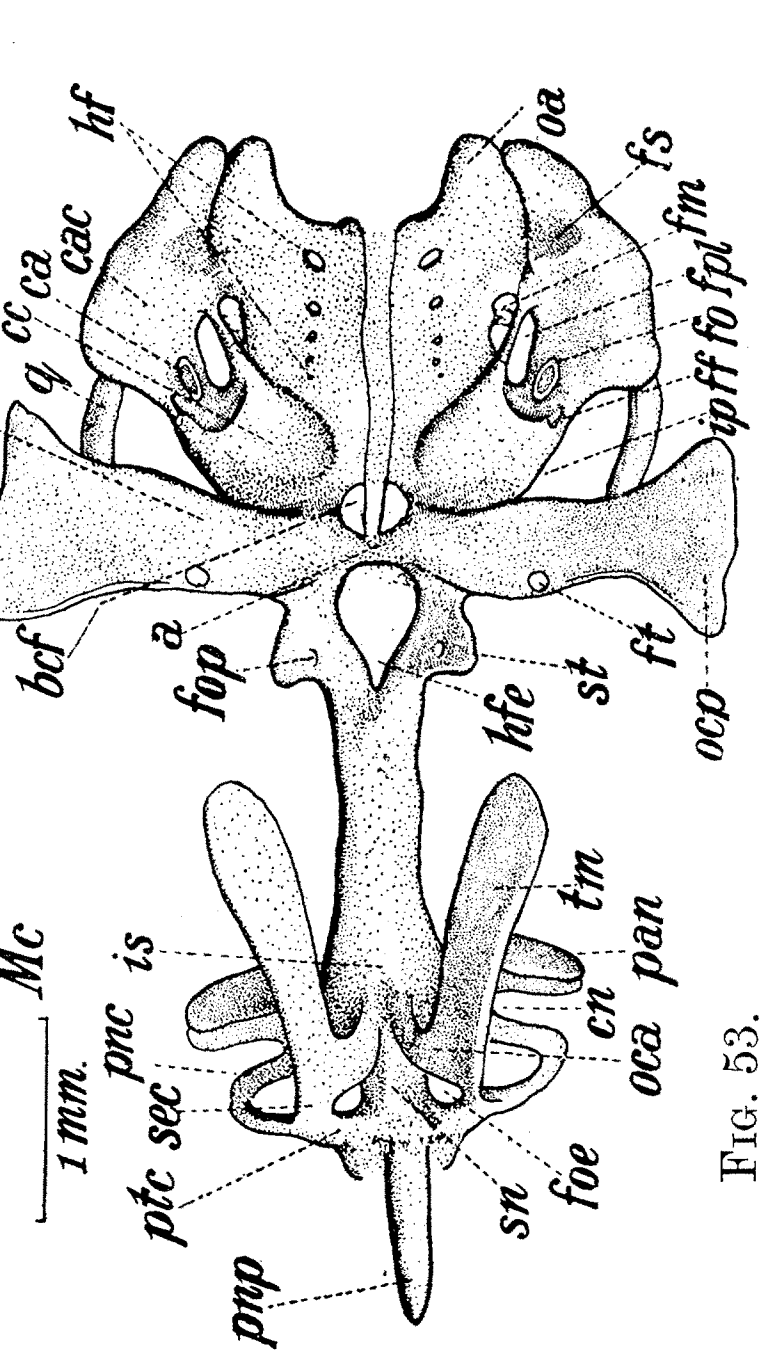

FIG. 53.

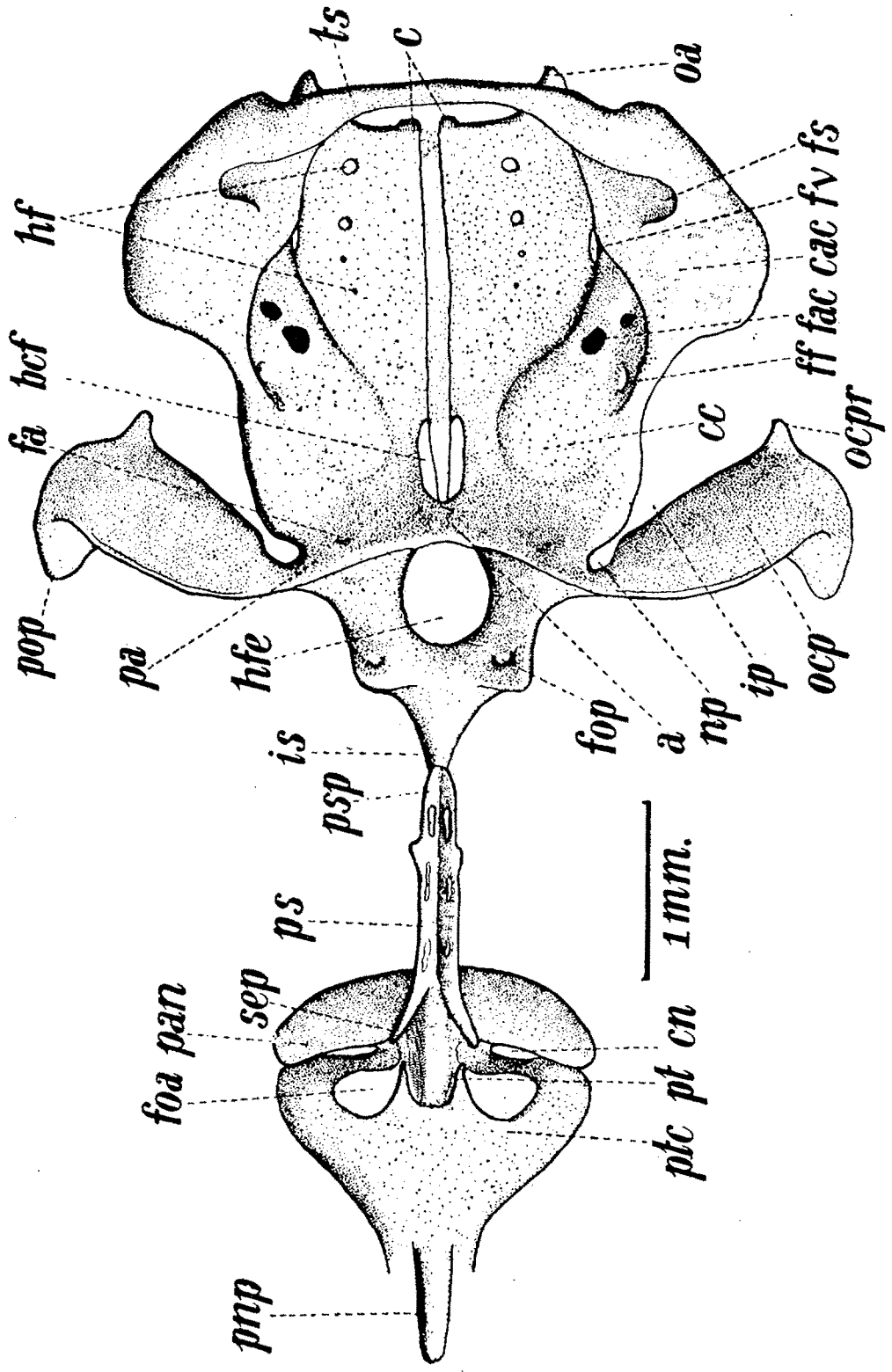

FIG. 56.

G. R. de B. del.

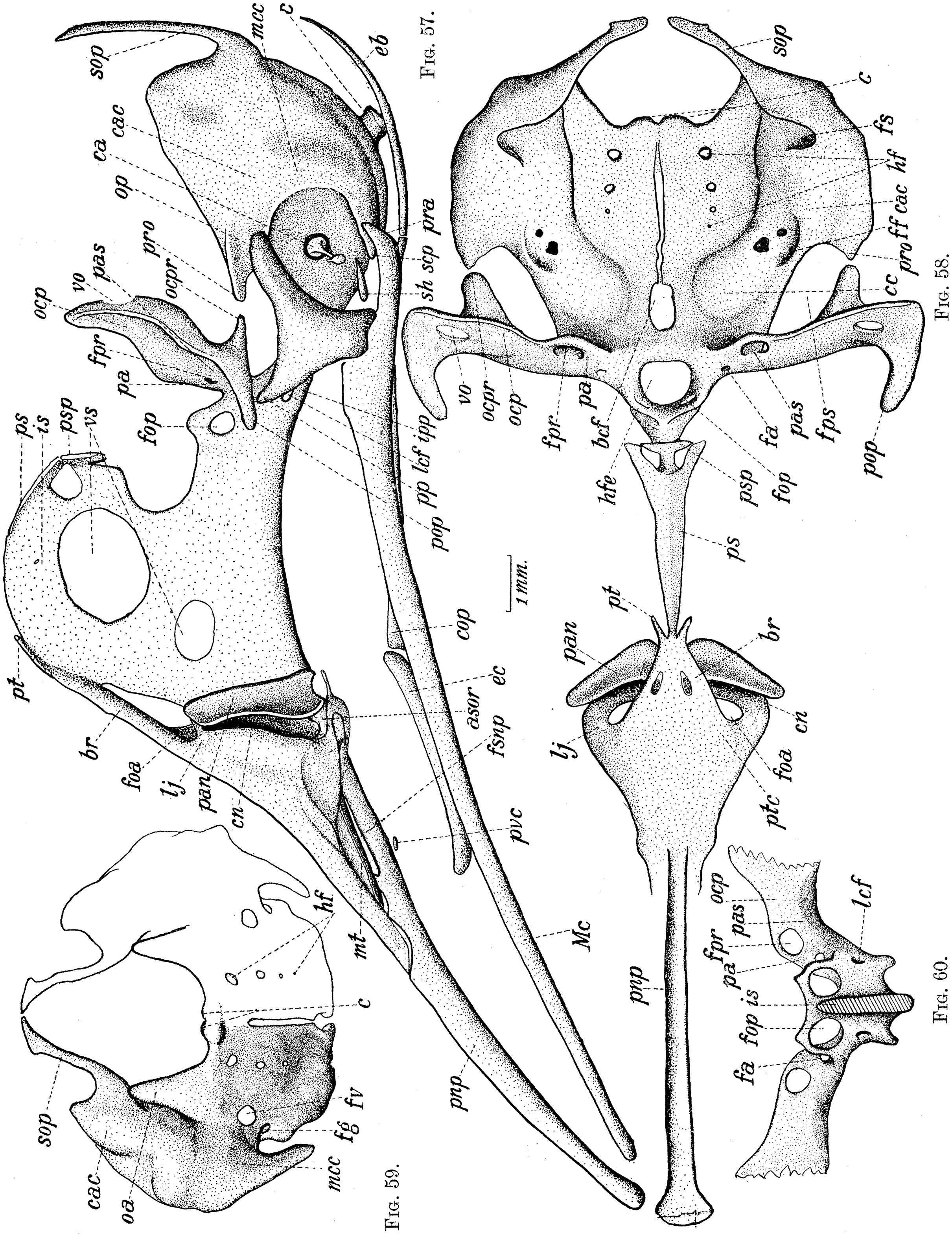

Fig. 57.

Fig. 58.

Fig. 59.

Fig. 60.

G. R. de B. del.

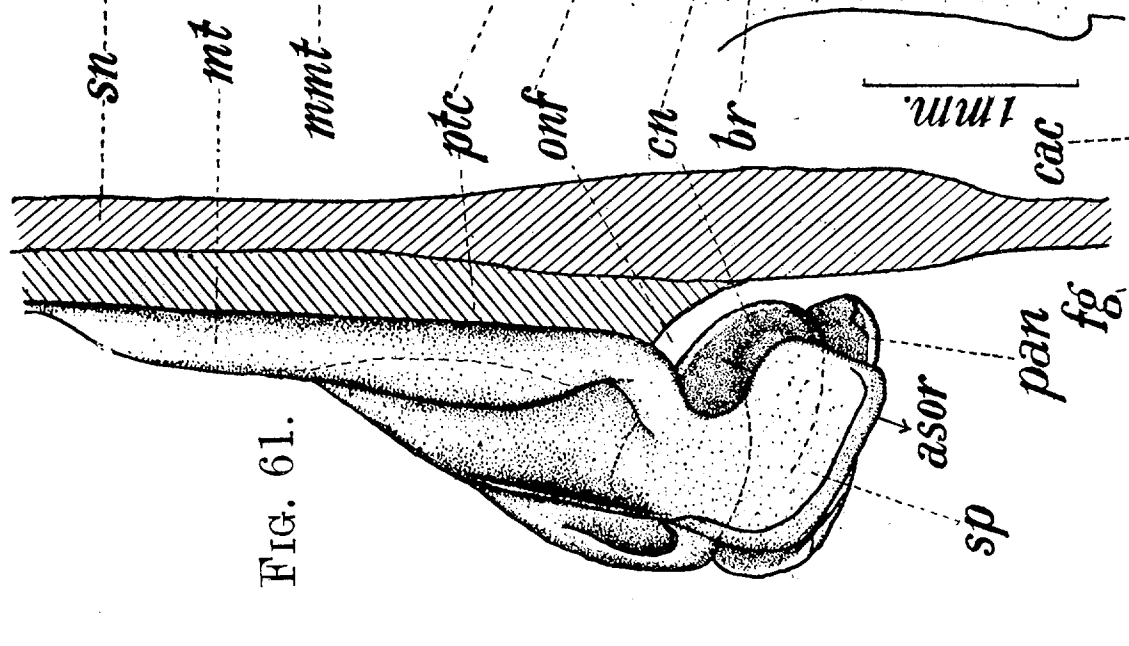

FIG. 61.

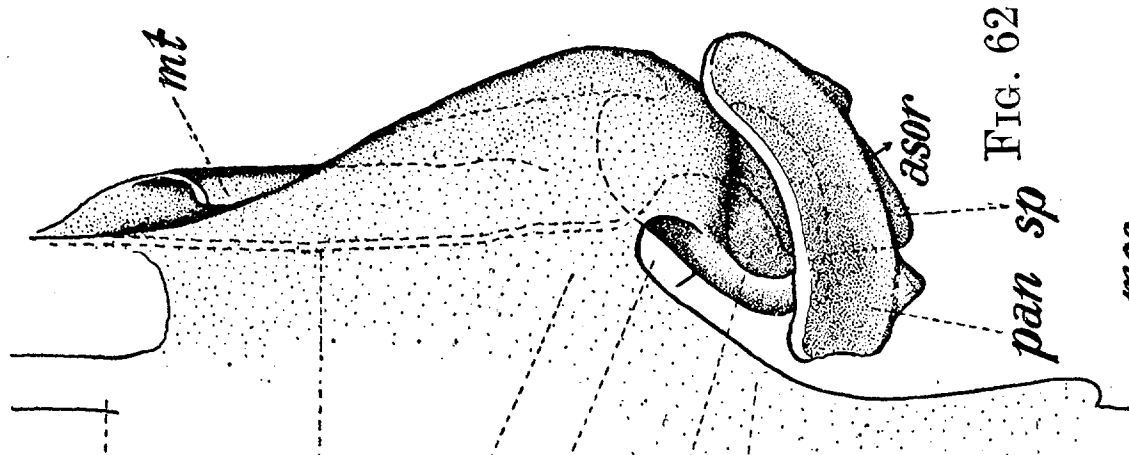

FIG. 62.

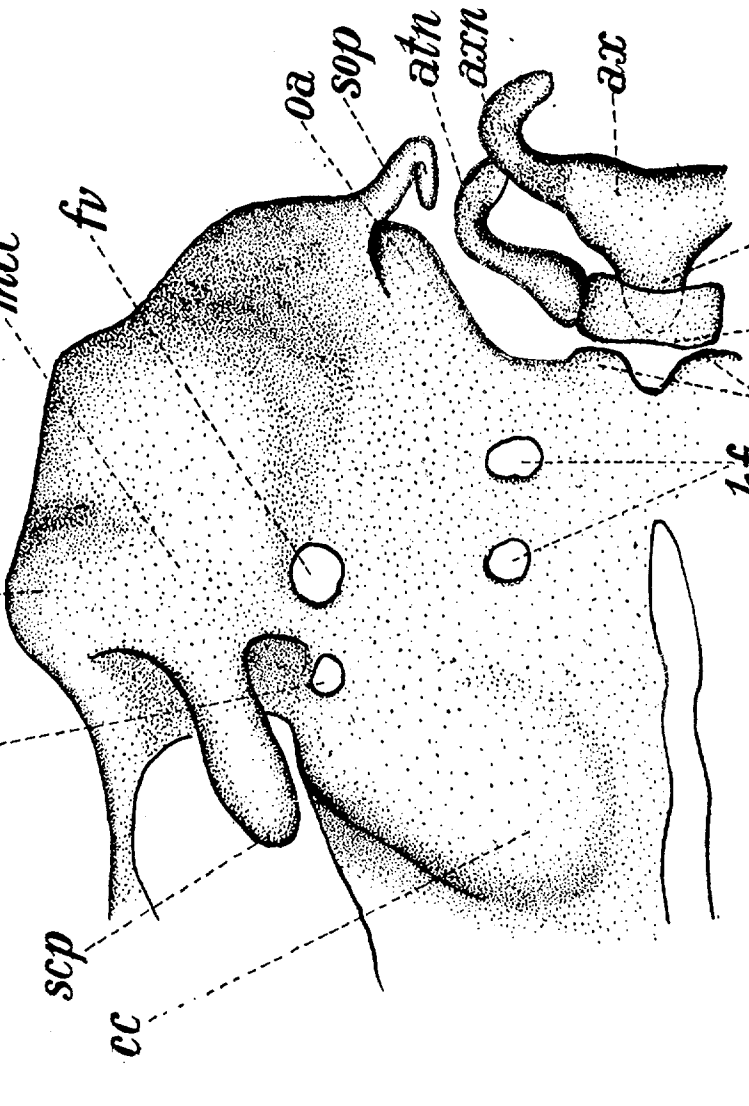

FIG. 63.

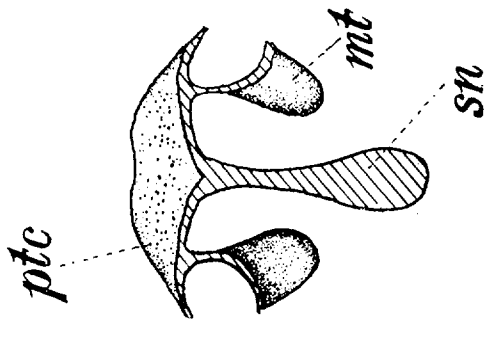

FIG. 64.

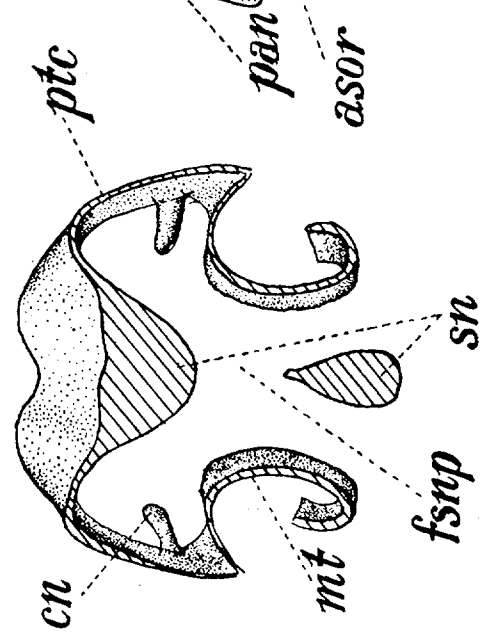

FIG. 65.

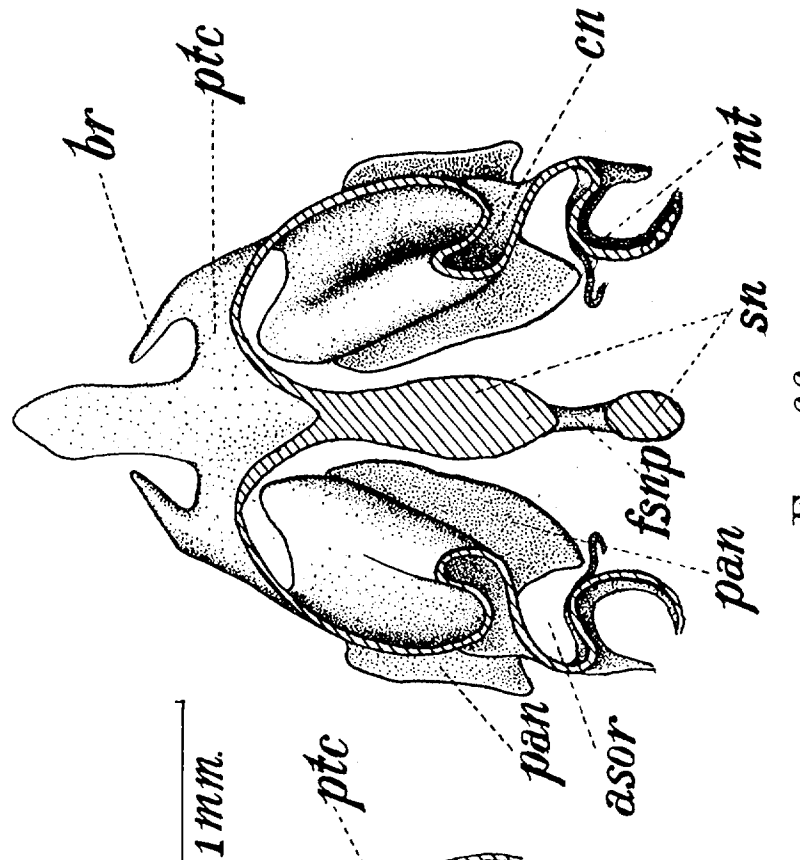

FIG. 66.

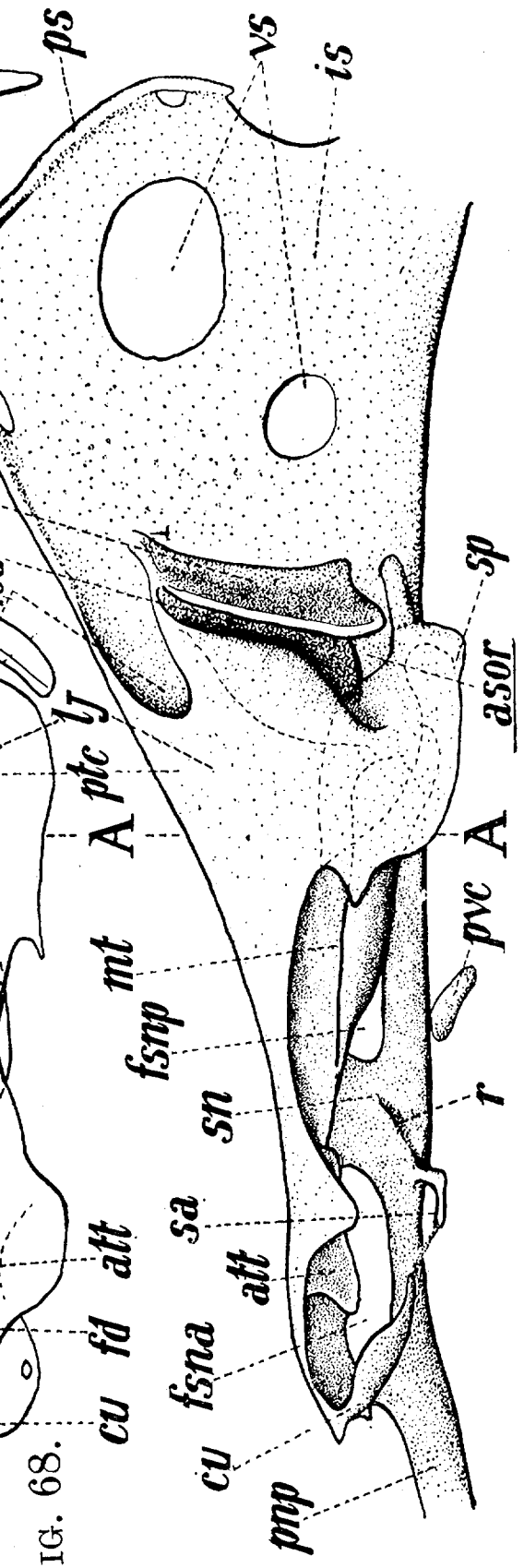

FIG. 67.

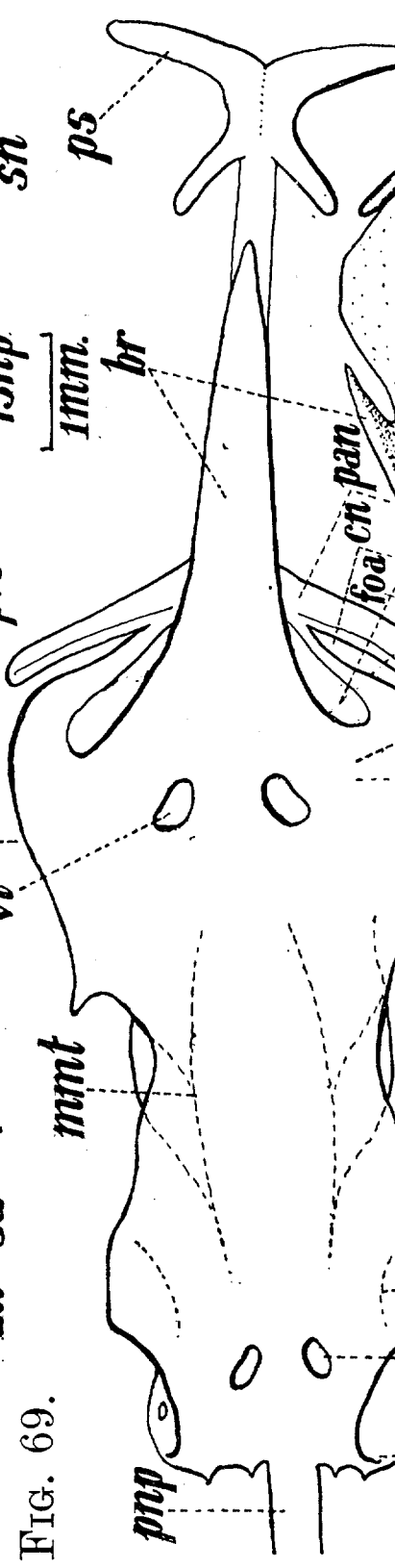

FIG. 68.

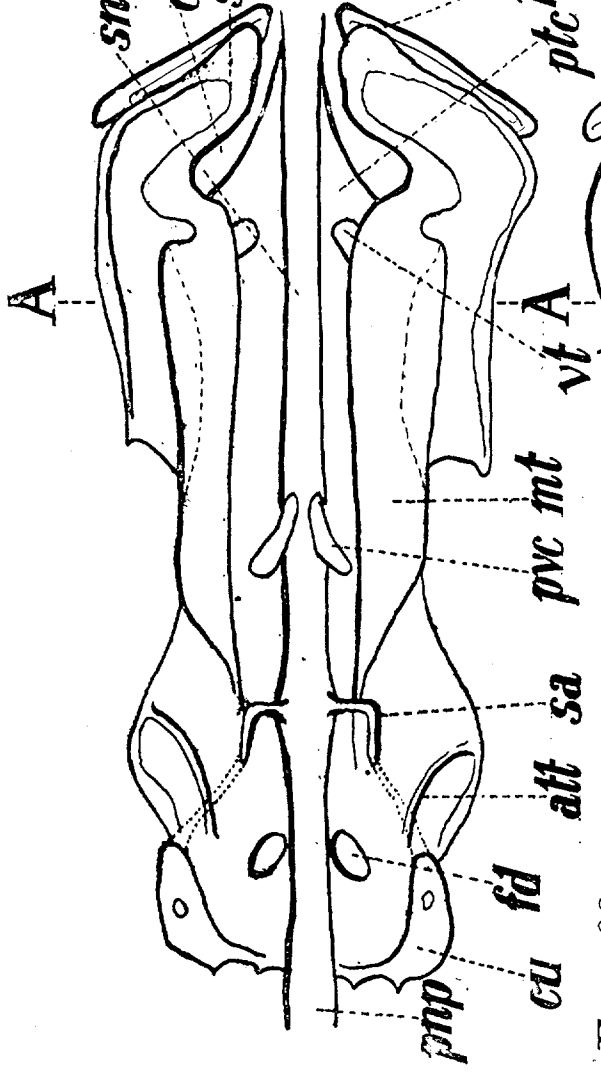

FIG. 69.

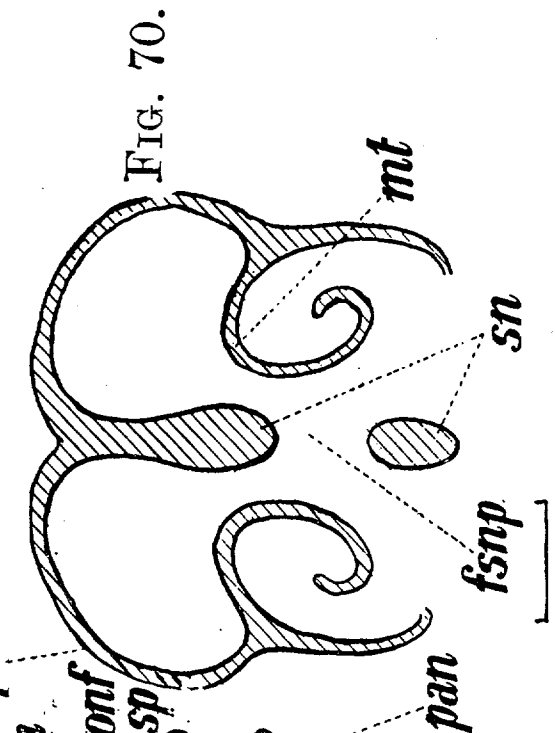

FIG. 70.

G. R. de B. del.

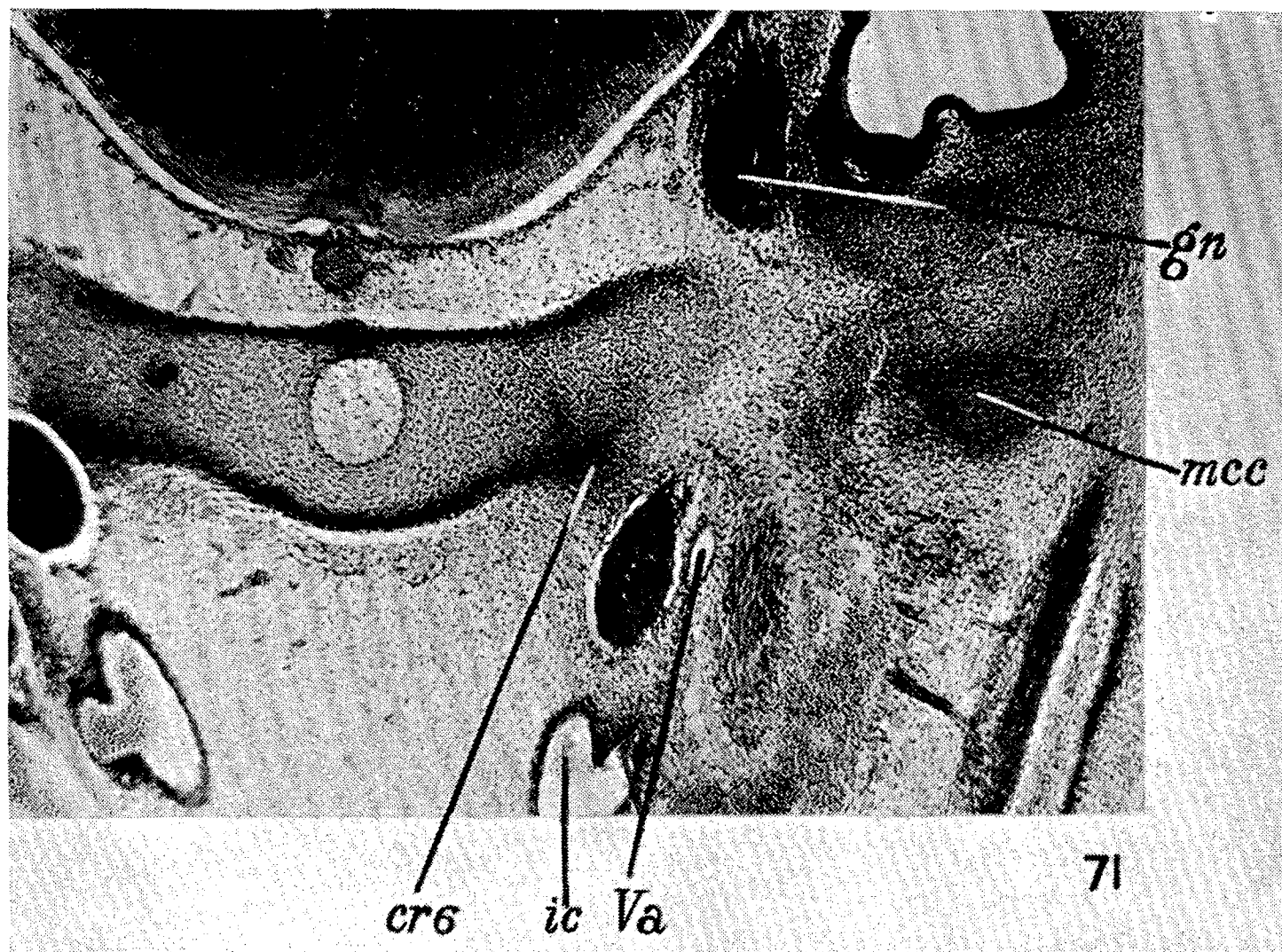

71

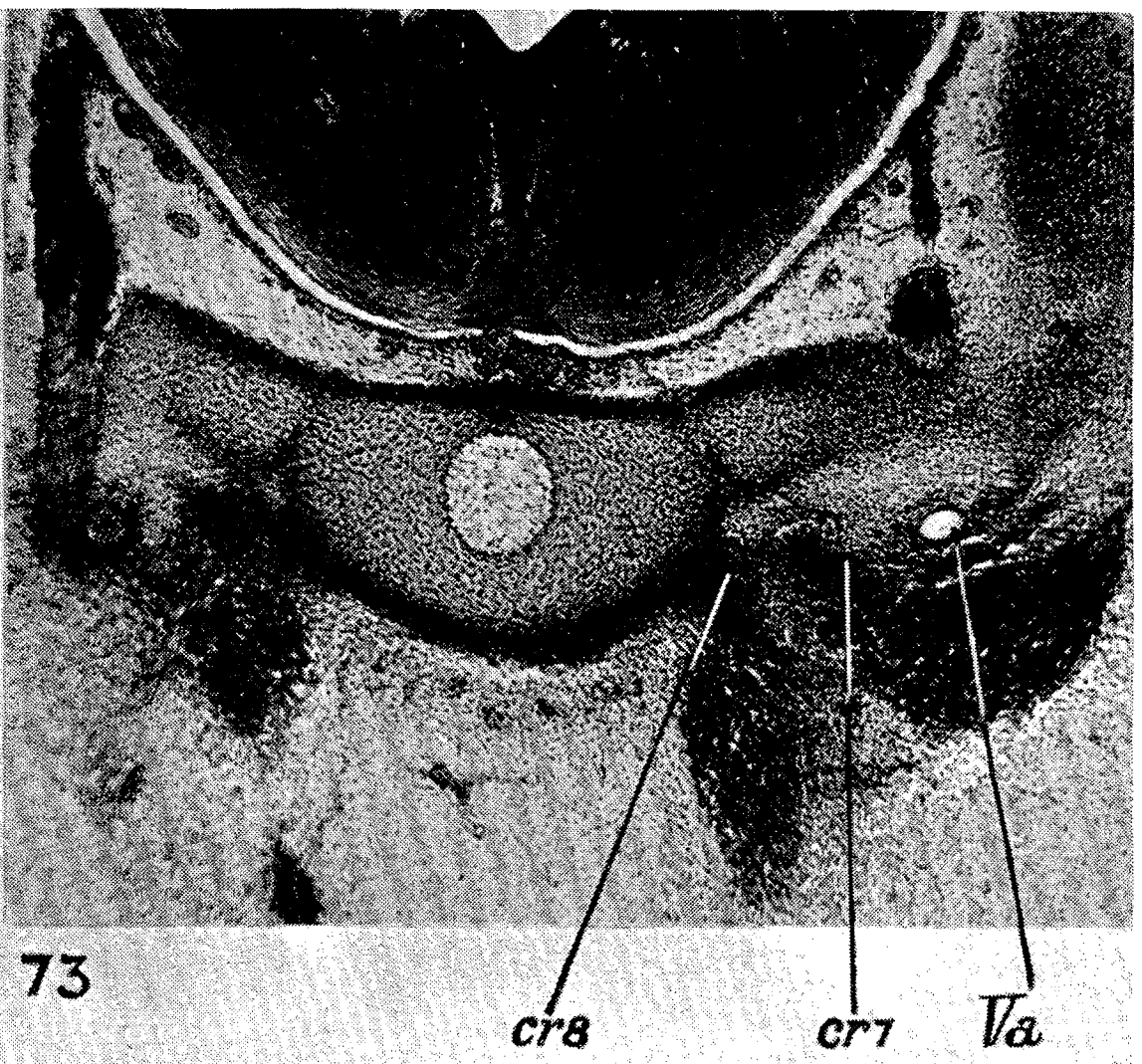

73

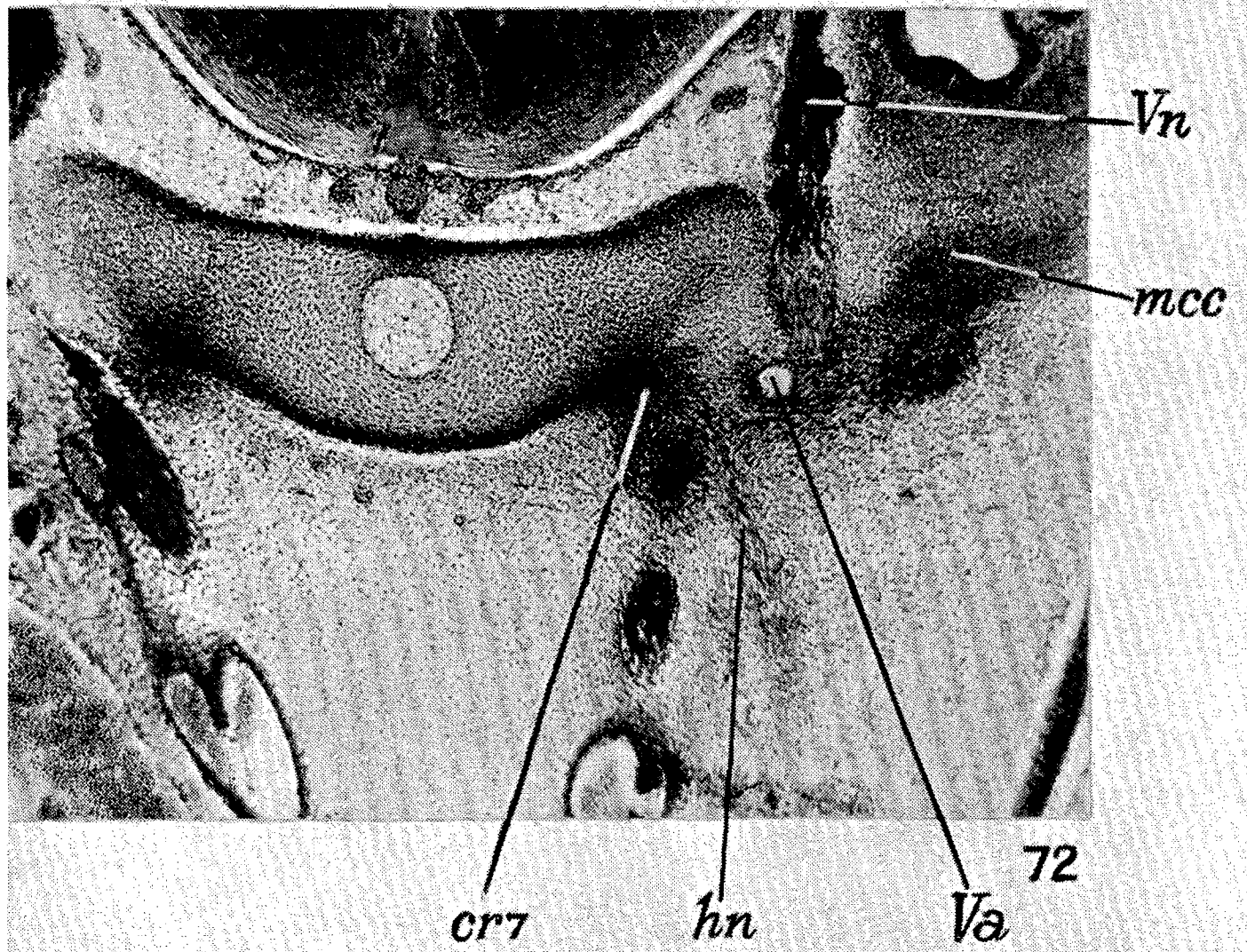

72

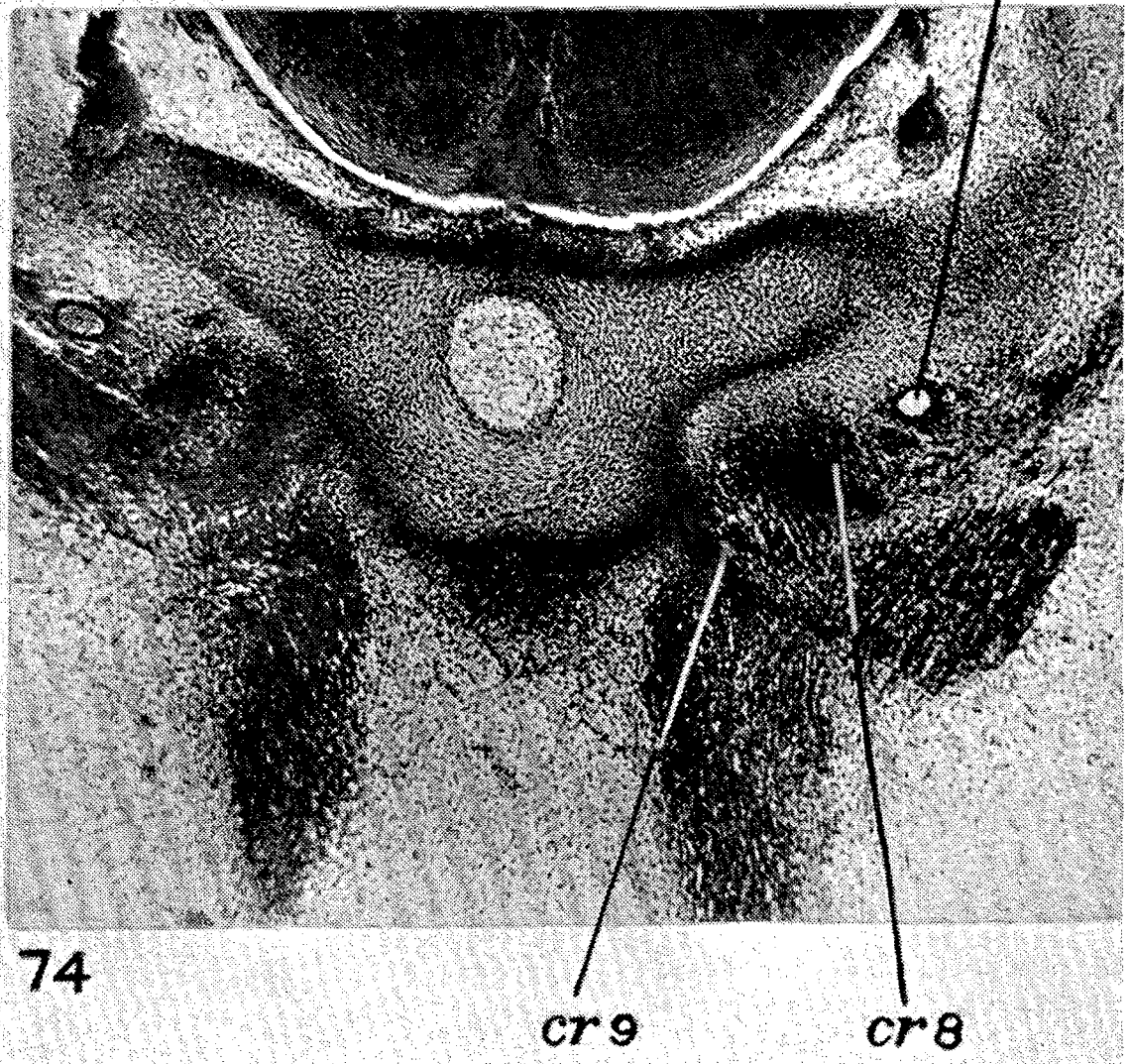

74

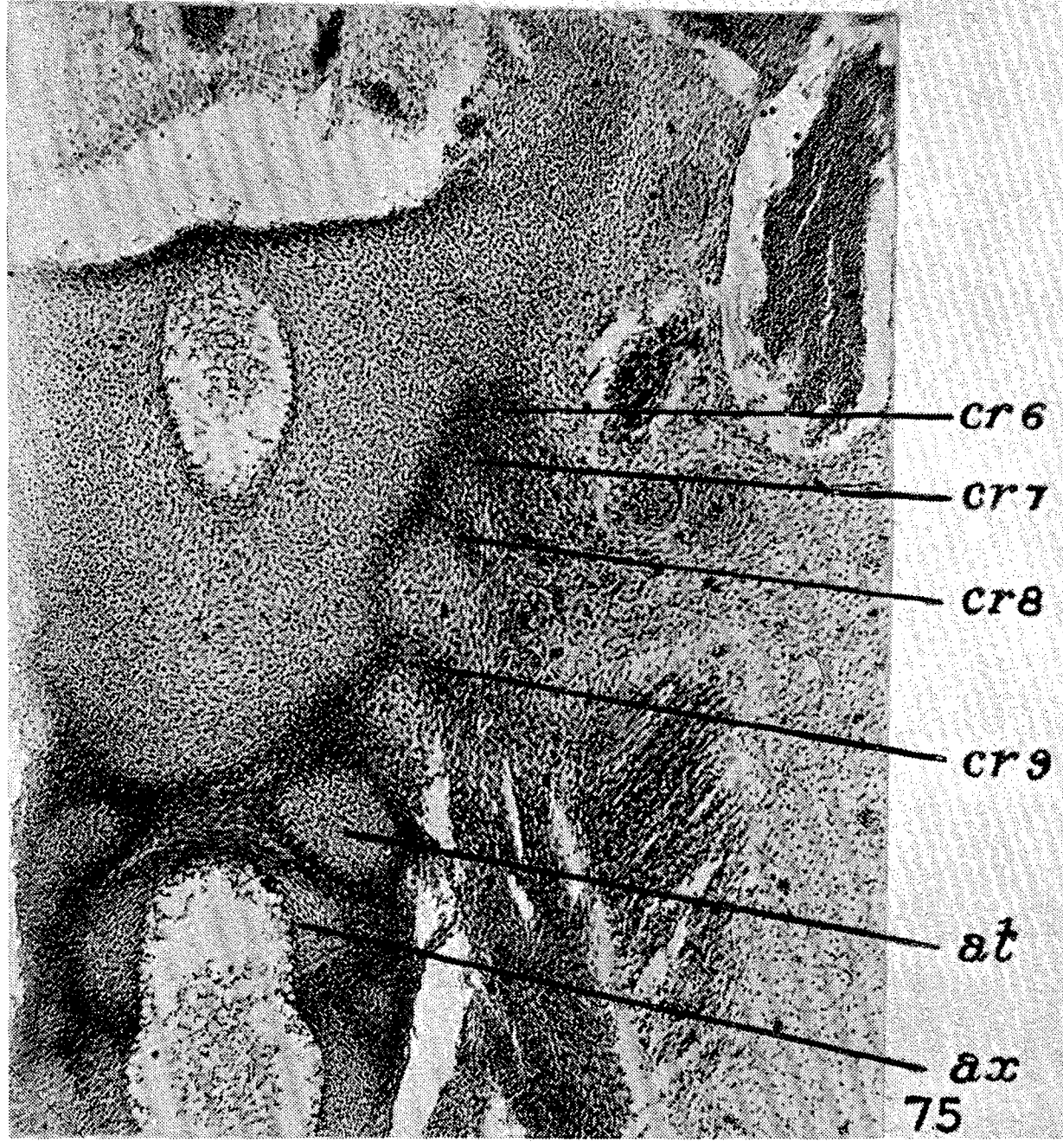

75

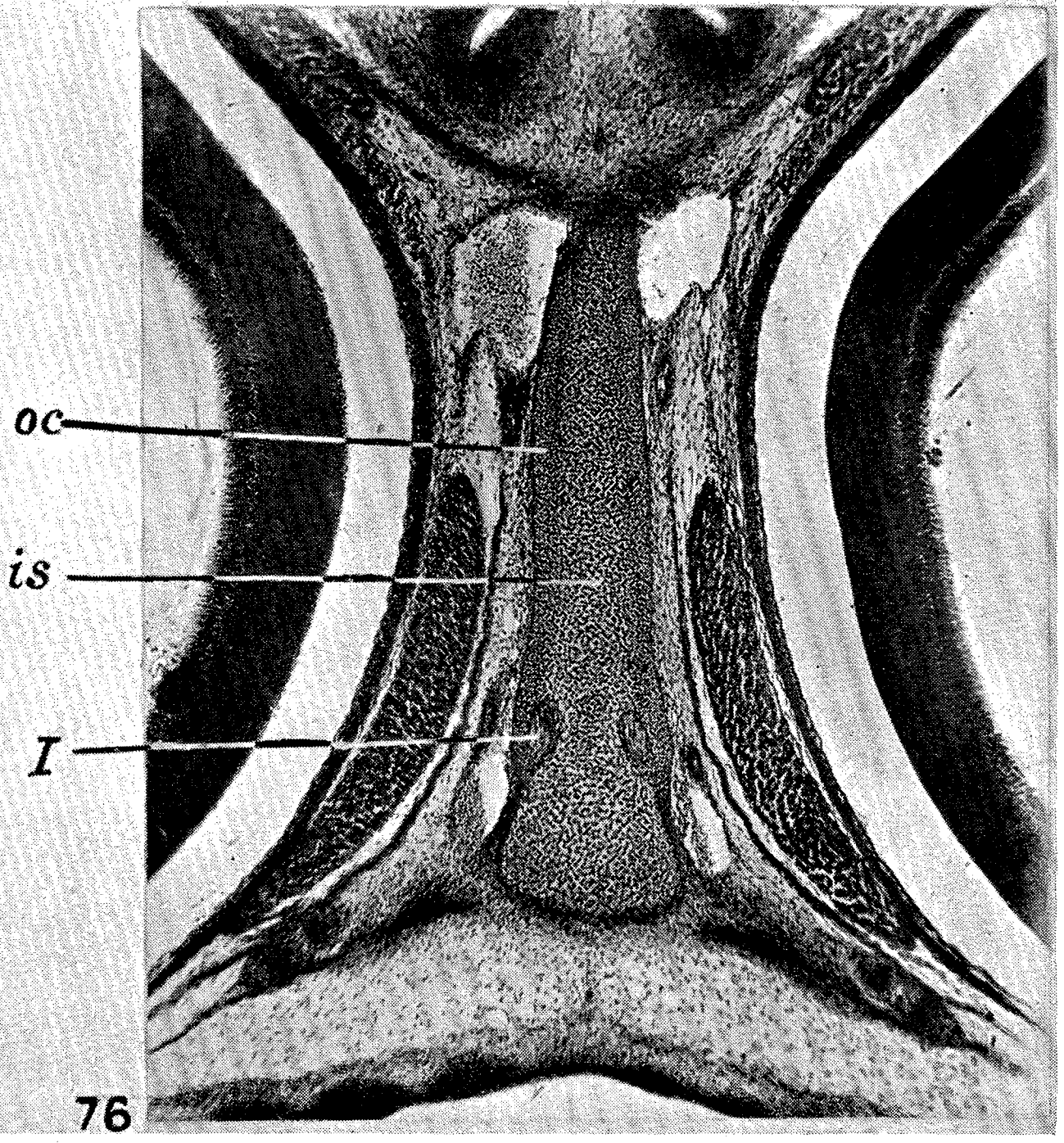

76

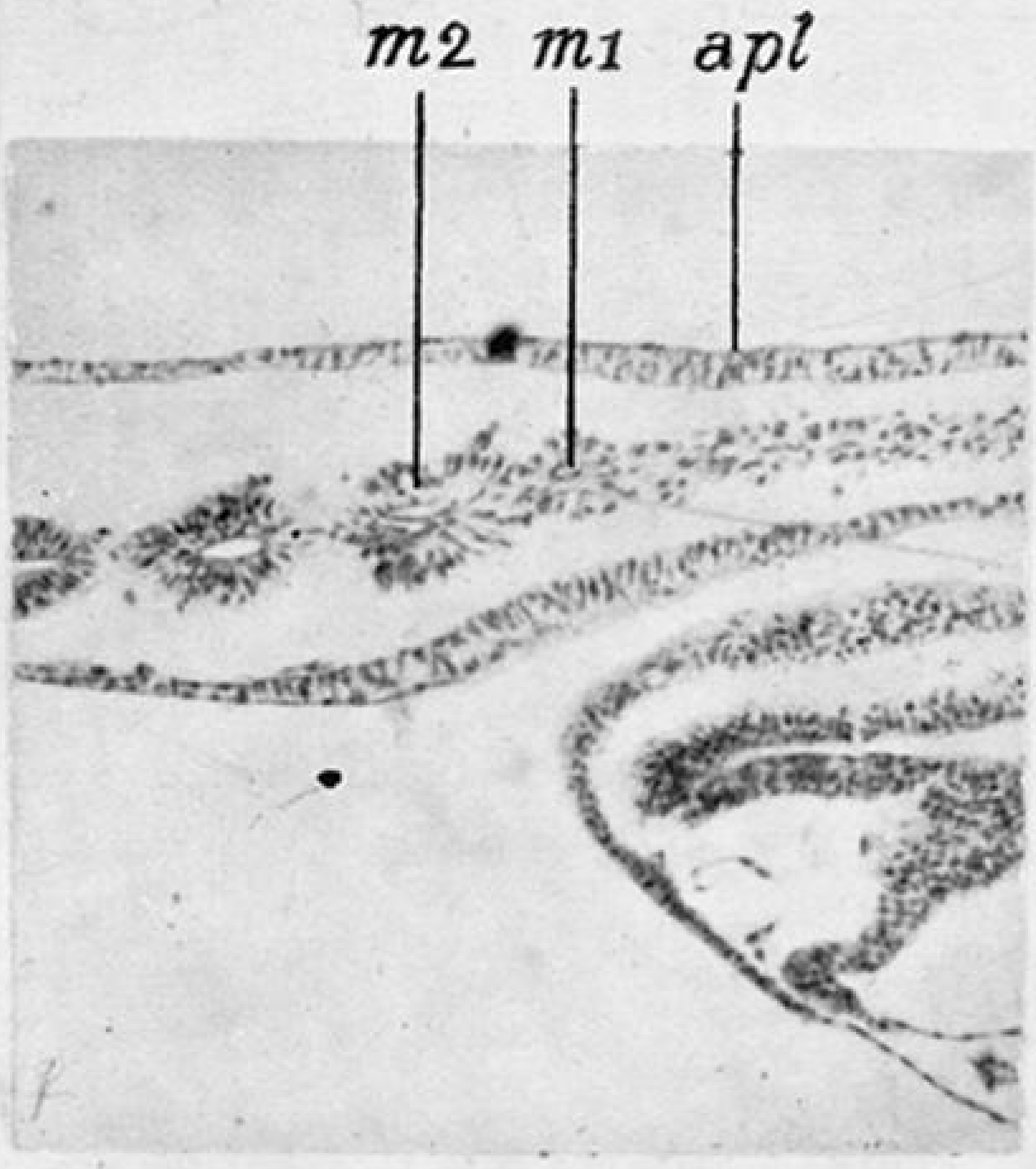

26

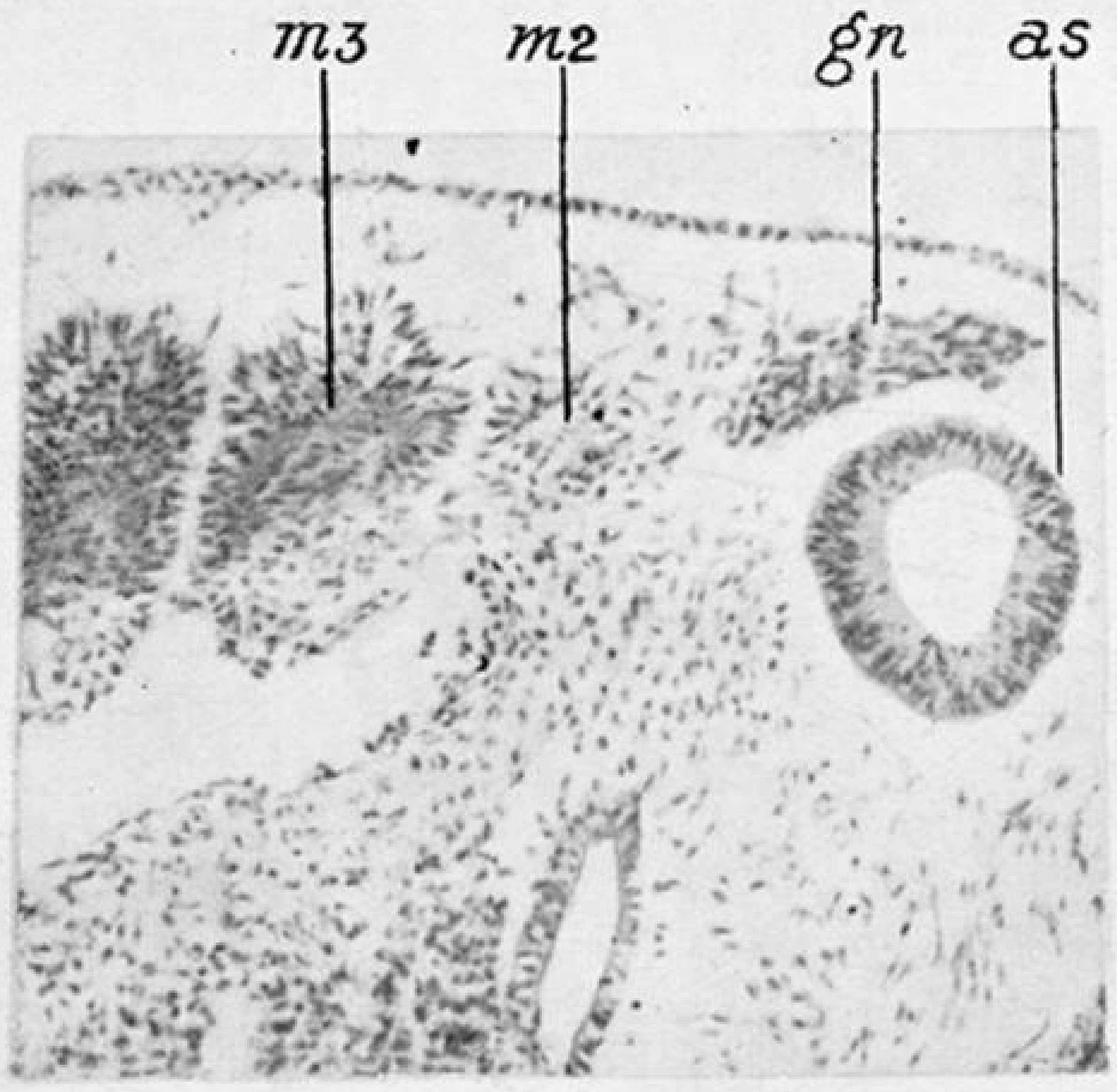

27

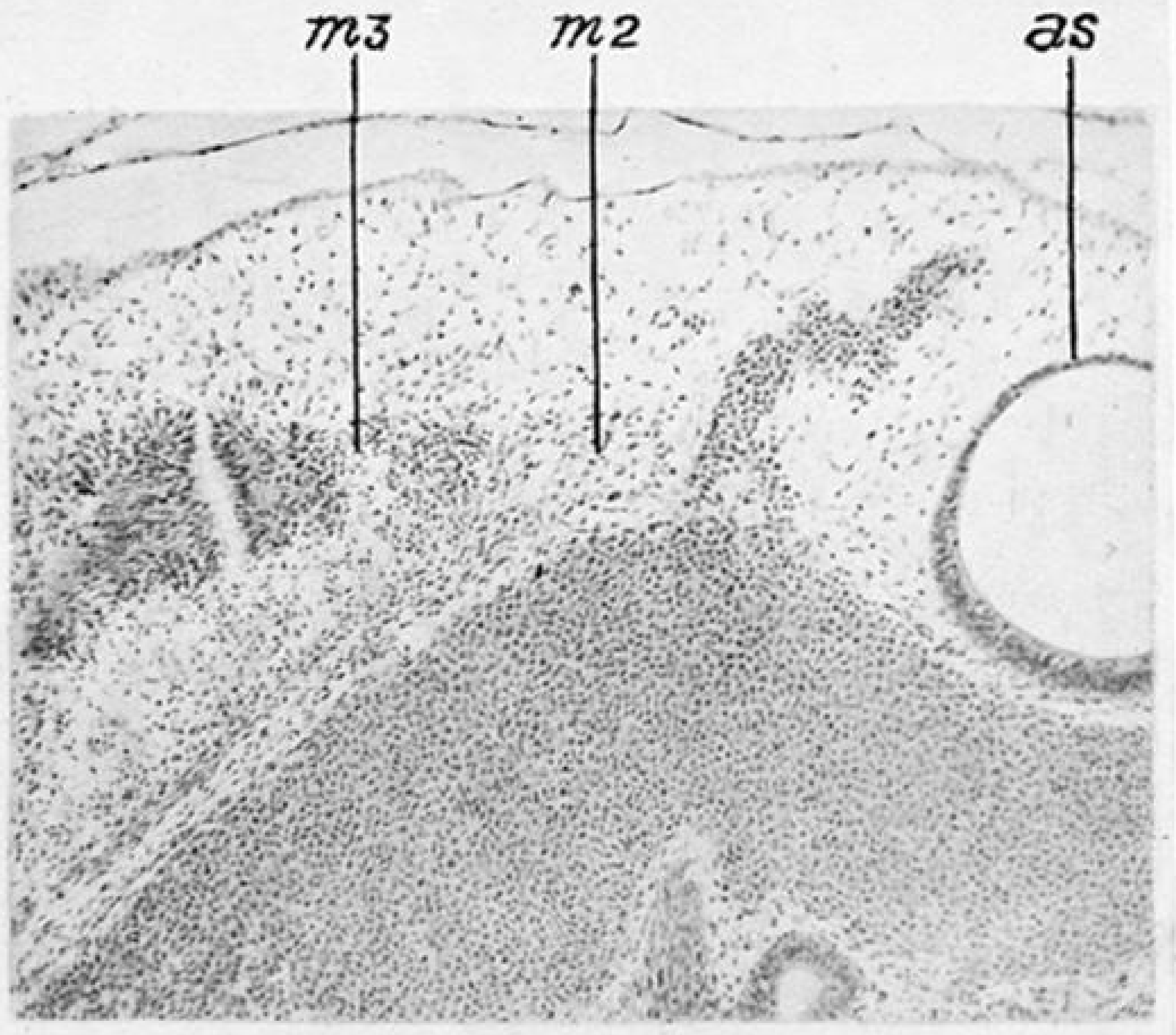

28

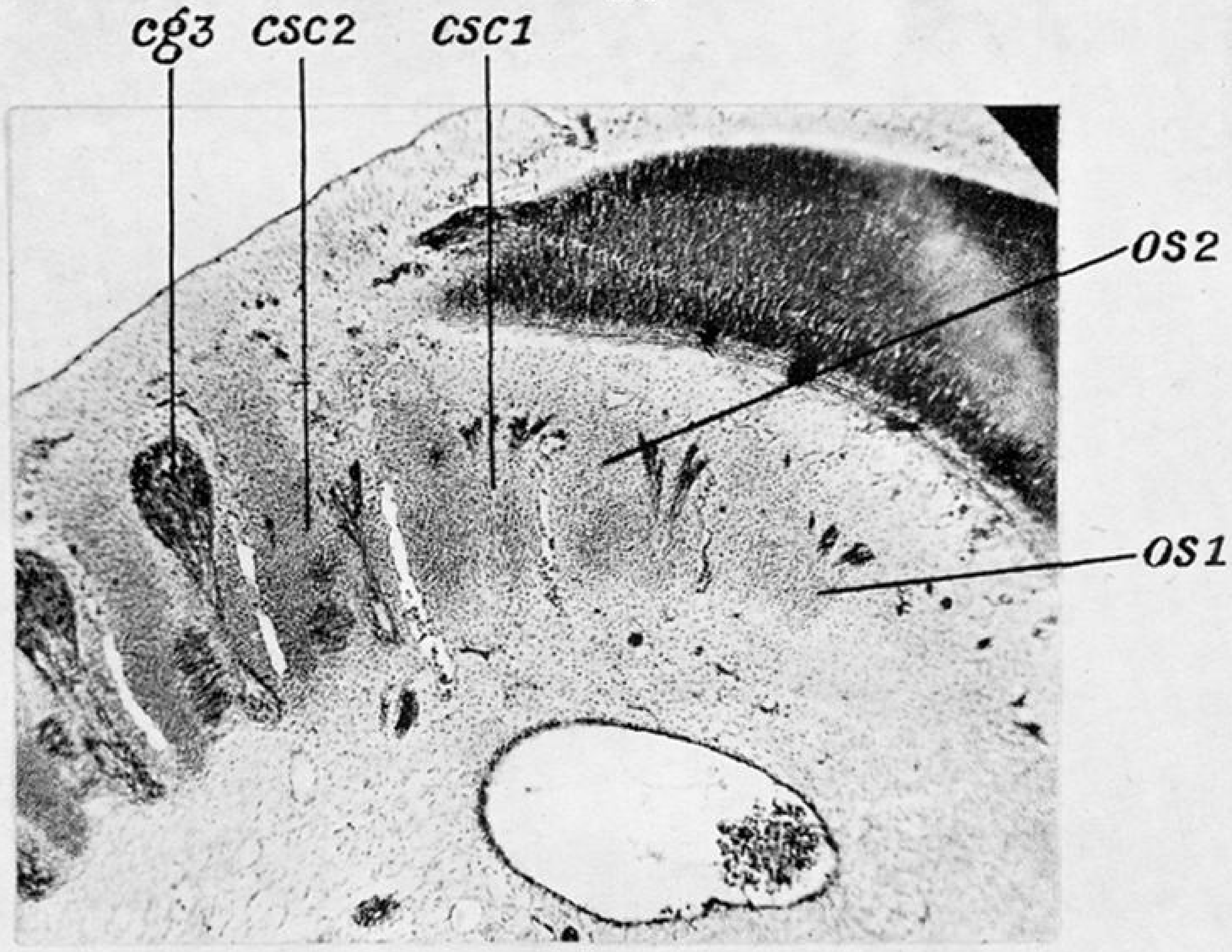

29

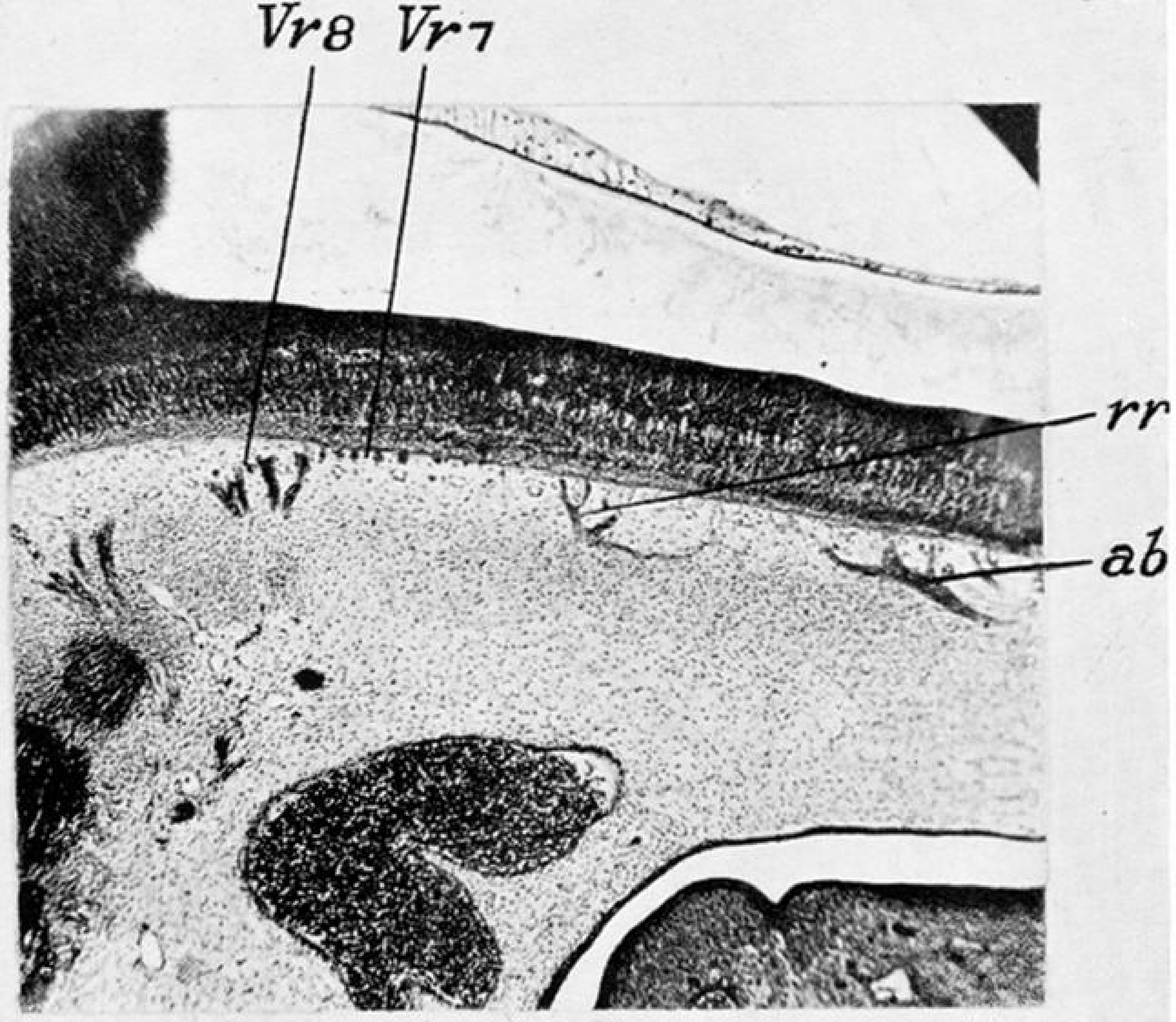

30

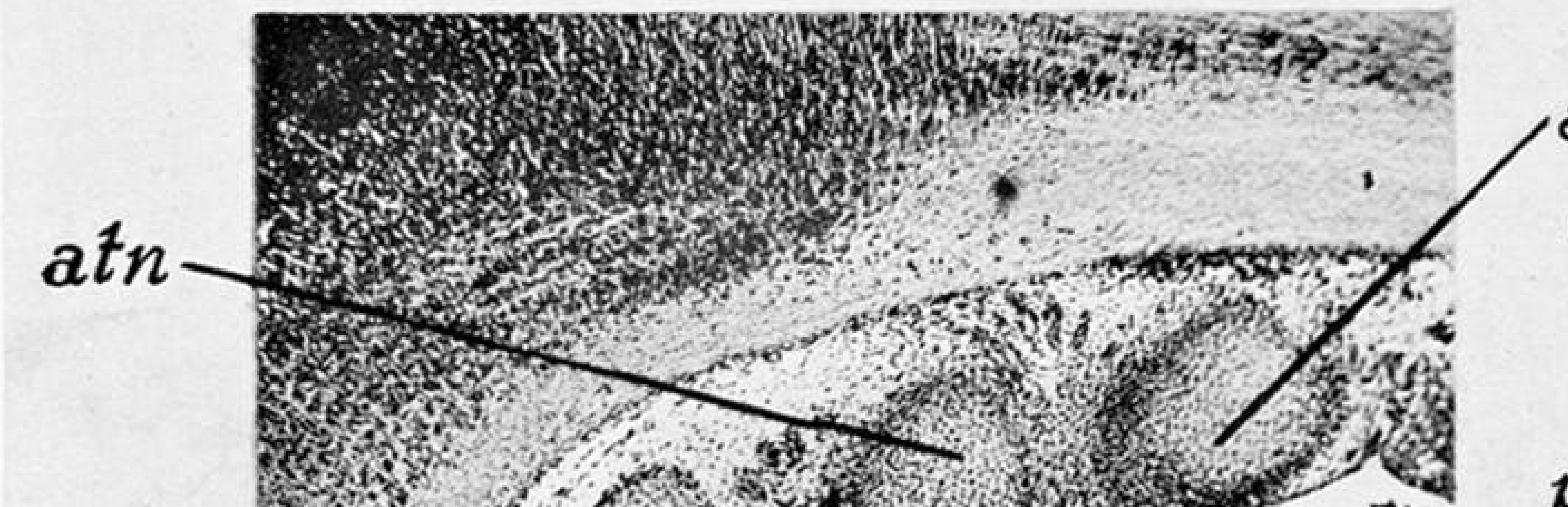

31

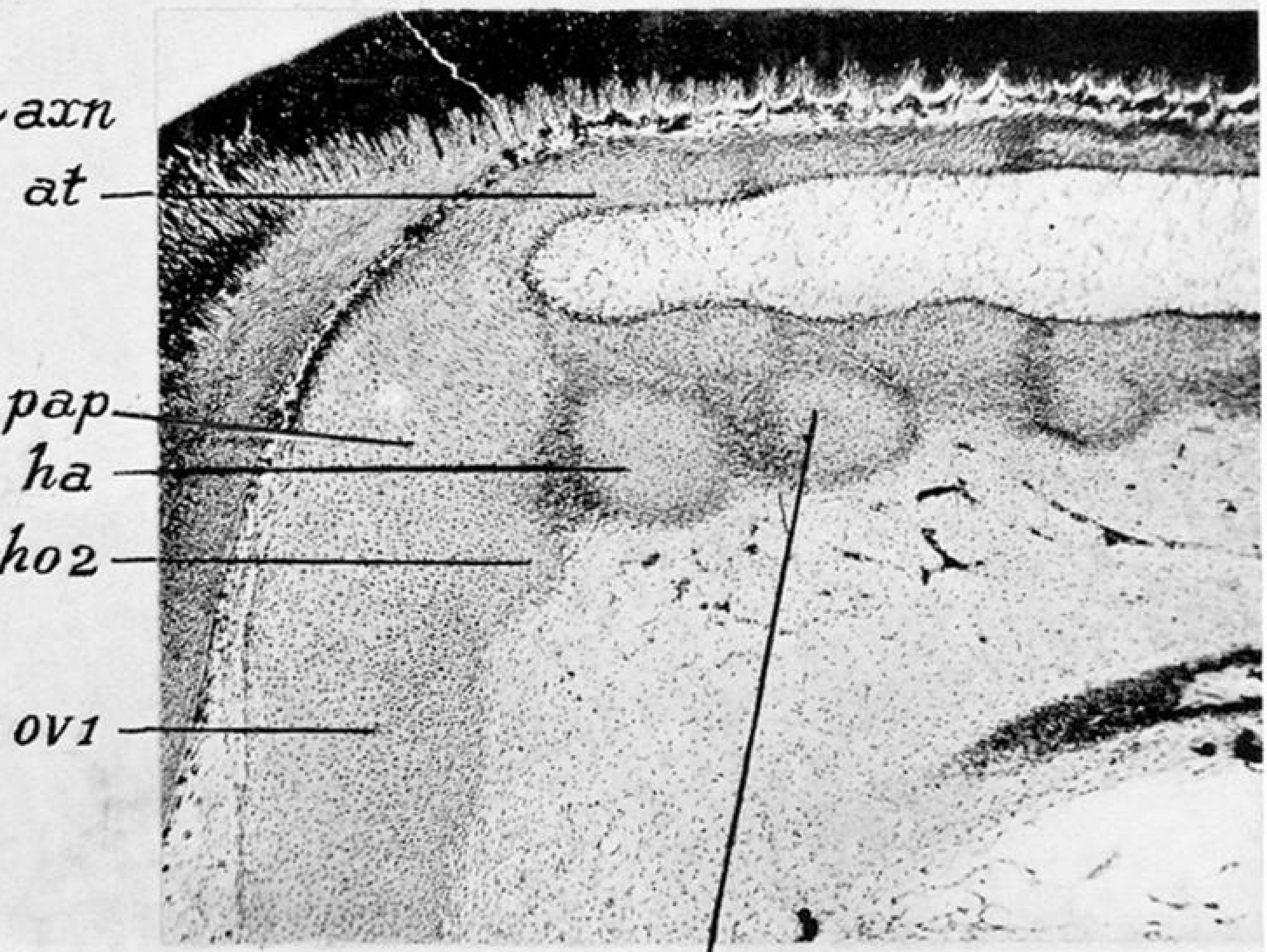

32

PLATE 46.

FIG. 26.—Parasagittal section through an embryo of the duck at the 10-somite stage. Anterior end to right.

FIG. 27.—Ditto, at the 23-somite stage.

FIG. 28.—Ditto, at the 78-hour stage.

FIG. 29.—Ditto, at the 132-hour stage.

FIG. 30.—Ditto, at the 132-hour stage (anterior to 29).

FIG. 31.—Ditto, at the 7-day stage. Anterior end to left.

FIG. 32.—Ditto, at the 7-day stage. Median to 31.

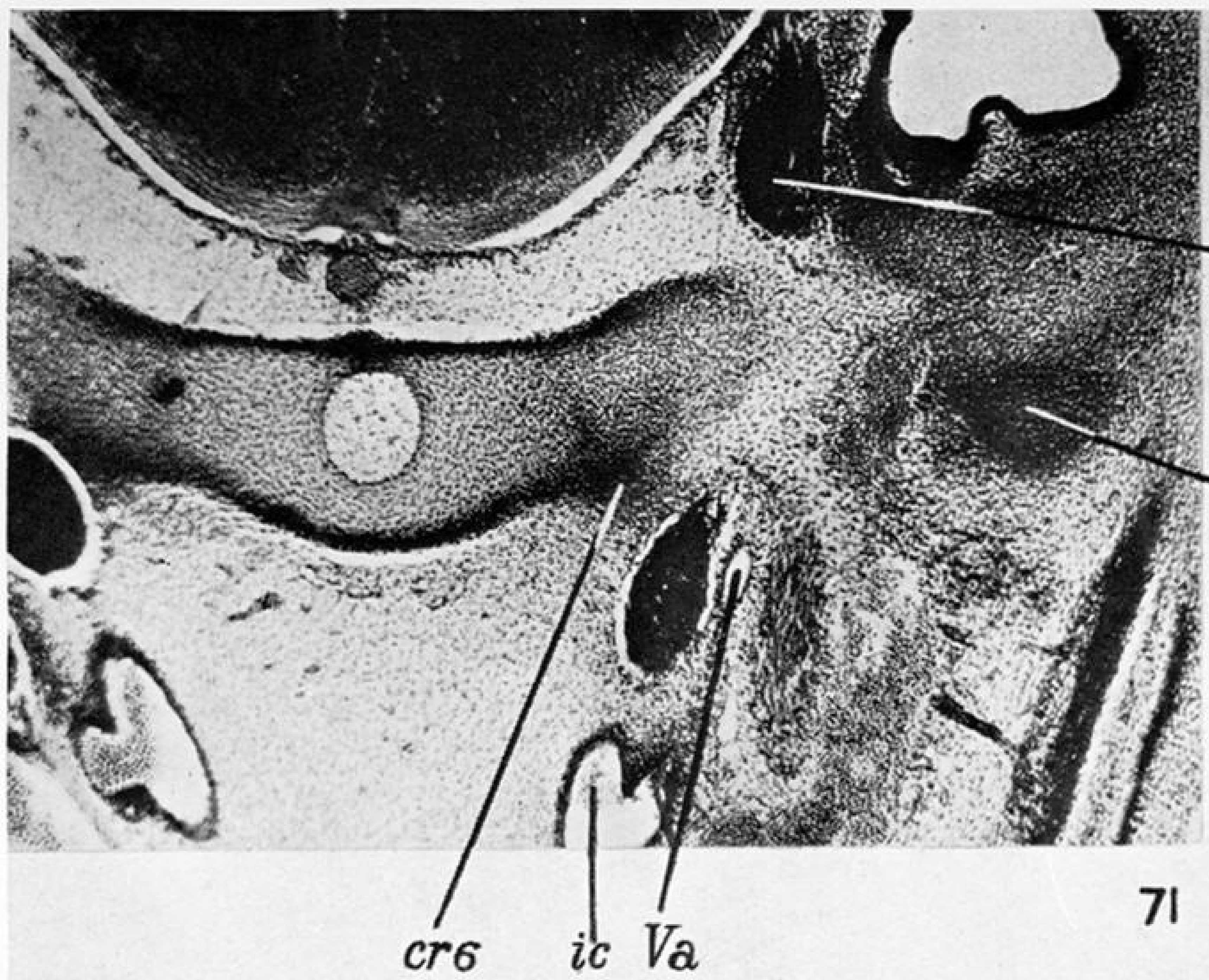

71

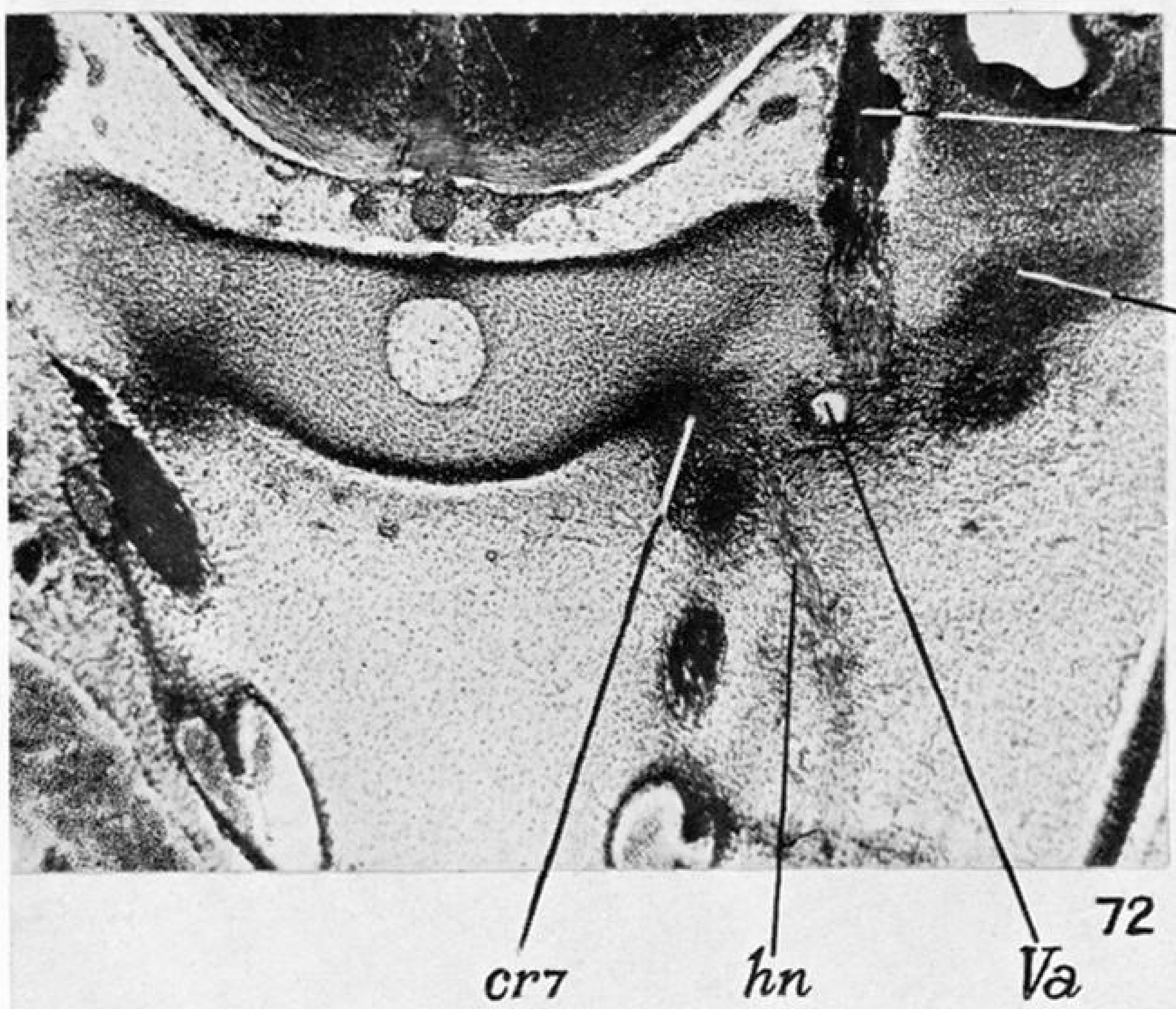

72

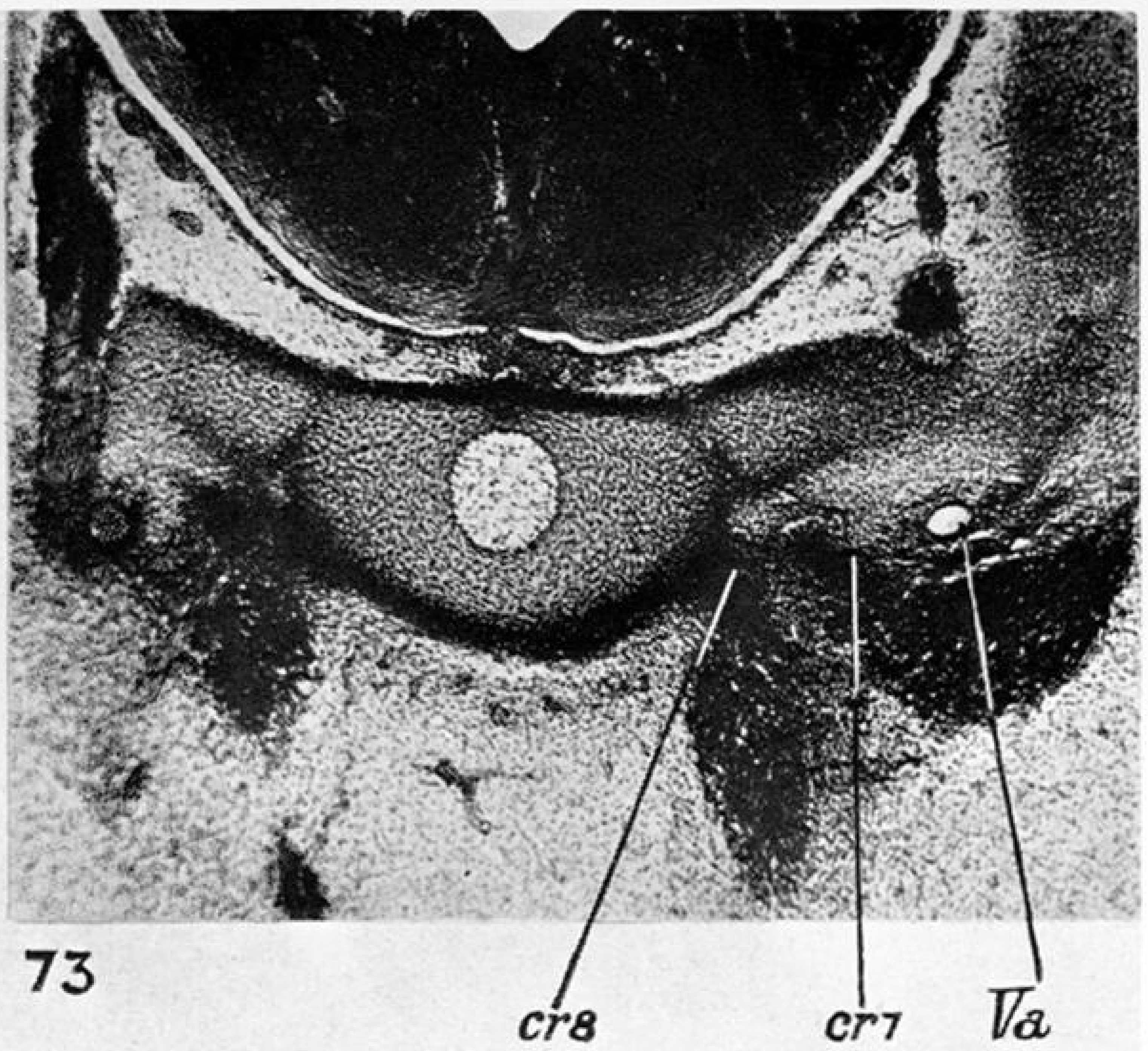

73

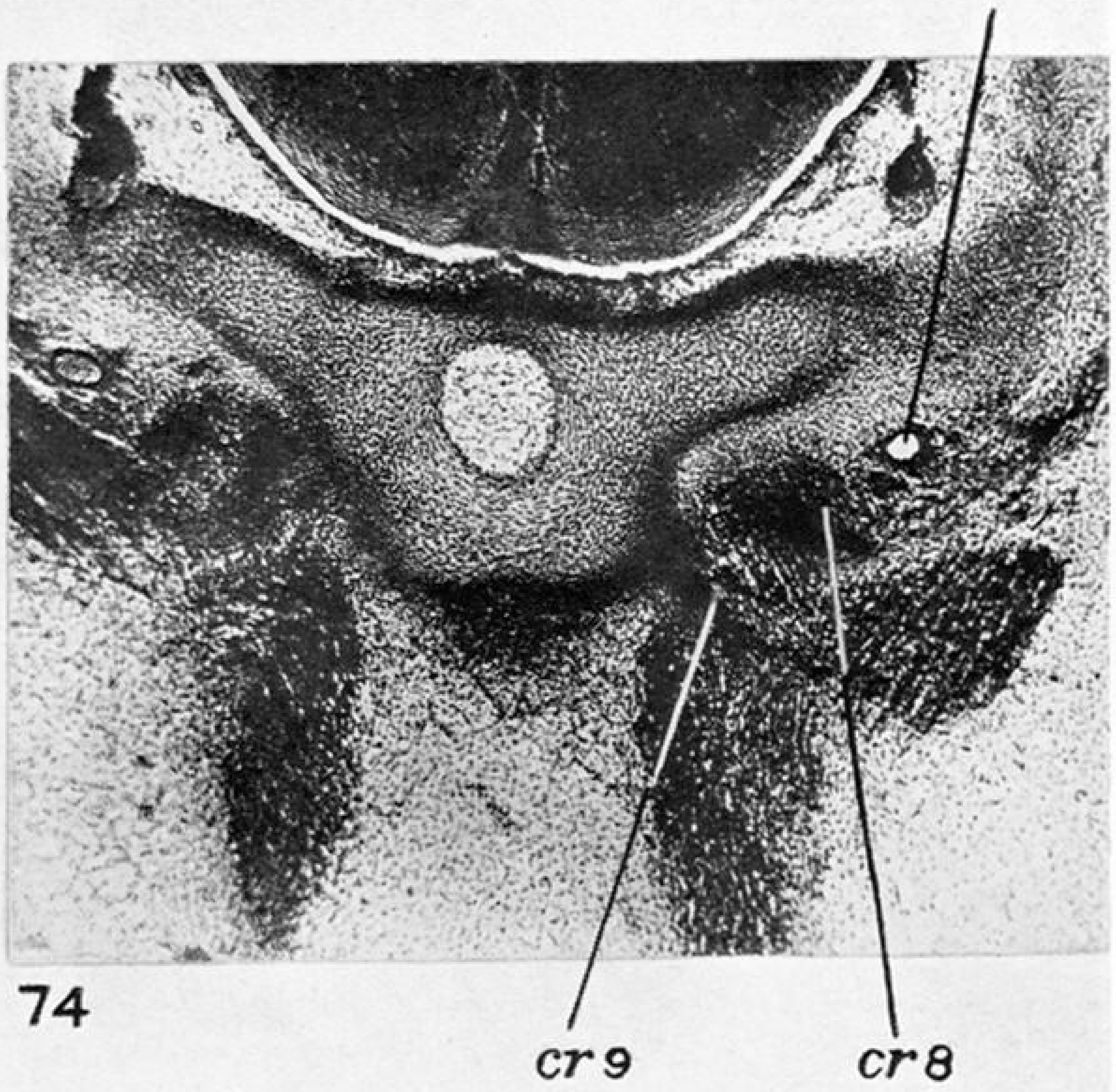

74

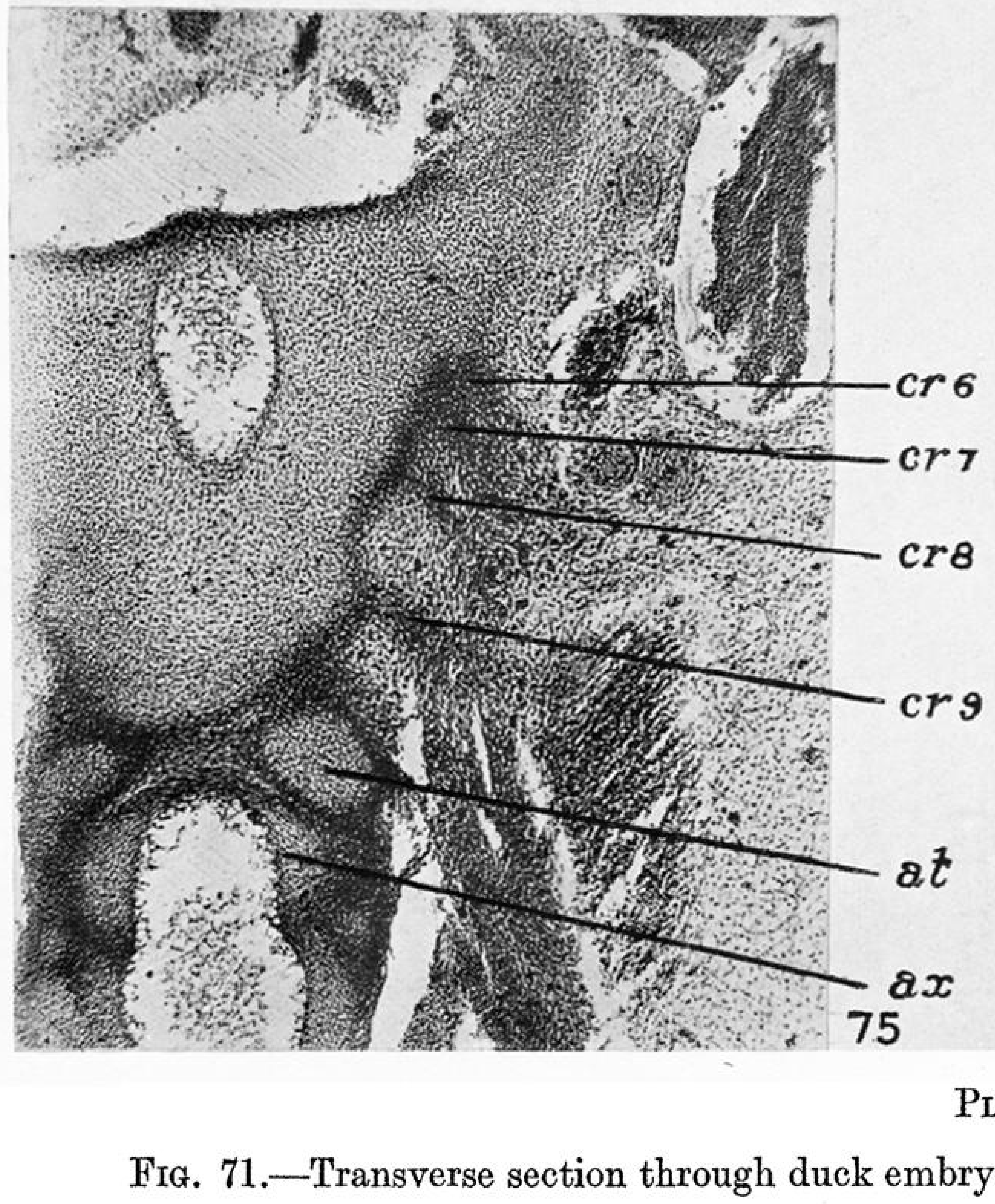

75

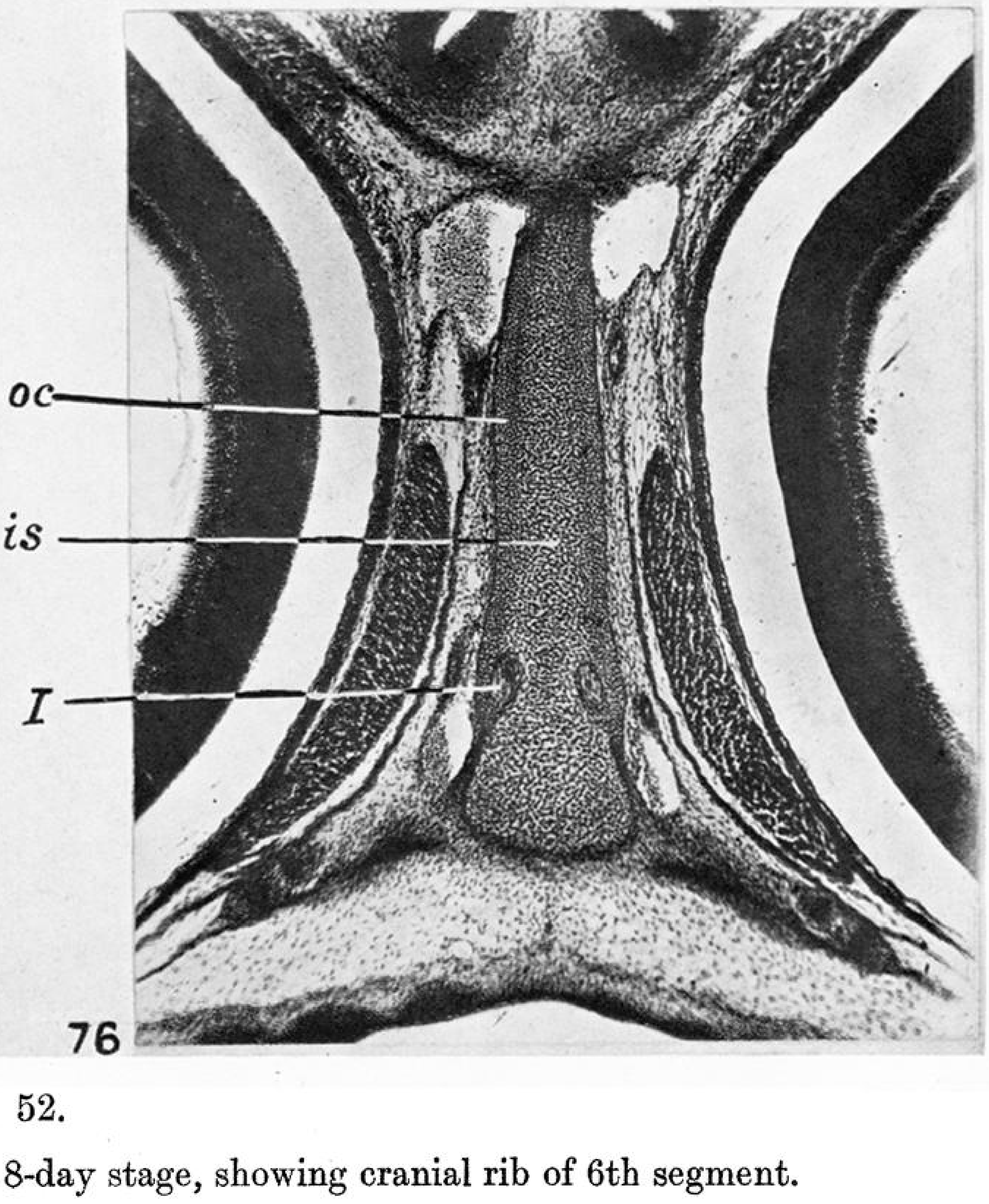

76

Plate 52.

Fig. 71.—Transverse section through duck embryo at 8-day stage, showing cranial rib of 6th segment.

Fig. 72.—Ditto, showing cranial rib of 7th segment.

Fig. 73.—Ditto, showing cranial rib of 7th and 8th segments.

Fig. 74.—Ditto, showing cranial ribs of 8th and 9th segments.

Fig. 75.—Horizontal section through duck embryo at 8-day stage, showing cranial ribs.

Fig. 76.—Horizontal section through sparrow embryo near full time, showing interorbital septum with orbital cartilages plastered on to it on each side, and enclosing olfactory nerves in tunnels.